

CASE REPORT

Idiopathic Gingival Fibromatosis: A Case Report

Sarmestha Soni¹, Pooja Pani², Tapas Ku. Bala³, Nishant⁴

ABSTRACT

Gingival fibromatosis is a heterogeneous group of enlargement characterized by progressive increase in submucosal connective tissue elements. Many cases are iatrogenic and some are inherited or idiopathic. This condition is usually part of a syndrome or rarely an isolated disorder. Gingival overgrowth as a clinical characteristic of idiopathic gingival fibromatosis causes dental complications which worsens patients' adaptation in daily emotional, social, and functional requirements. Here, we present a rare case of a non-syndromic idiopathic gingival fibromatosis in an 11-year-old child. The diagnosis was made based on history, clinical examination, radiographic findings, and histology. Gingivectomy was carried out in all four quadrants under local anesthesia. No recurrence was observed during the follow-up, and the patient showed remarkable esthetic and functional improvement.

Keywords: Gingival fibromatosis, Gingivectomy, Syndromes.

How to cite this article: Soni S, Pani P, Bala TK, Nishant. Idiopathic Gingival Fibromatosis: A Case Report. *Int J Prev Clin Dent Res* 2018;5(2):113-116.

Source of support: Nil

Conflict of interest: None

INTRODUCTION

Idiopathic gingival enlargement is also known as *gingivostomatitis*,^[1] diffuse fibroma,^[2] idiopathic fibromatosis,^[3] hereditary gingival fibromatosis,^[3] and familial elephantiasis.^[3]

Idiopathic gingival fibromatosis is a rare condition characterized by slowly progressing enlargement caused by collagenous overgrowth of gingival connective tissue.^[4] It is a benign growth of the gingival tissue affecting 1:175,000 live birth with no sex predilection. It appears as an isolated disorder or may sometimes be associated with other conditions such as epilepsy, hypertrichosis, and mental retardation.^[5,6]

It is also seen in several blood dyscrasias such as leukemia, thrombocytopenia, or thrombocytopathy and sometimes may develop as a part of syndromes such as Cowden syndrome,^[4] Zimmermann-Laband syndrome,^[7] and Murray-Puretic-Drescher syndrome.^[4]

It is a rare hereditary condition usually having an autosomal dominant inheritance pattern although recessive forms have also been sited.^[8] Investigations are in evolution to establish the genetic linkage and heterogeneity associated with this abnormality.^[4,7] 2p21-2p22 is one of the two loci demonstrated to be responsible for autosomal dominant hereditary gingival fibromatosis.^[9] In modern times, a mutation in the son of senseless-I gene has been suggested as a possible cause of isolated (non-syndromic) gingival fibromatosis.^[10] However, no definite linkage has been established.^[11]

A typical case of idiopathic gingival enlargement presents as large masses of firm, dense, and resilient insensitive growth that covers the alveolar ridges and extends over the teeth.^[12] The hyperplastic gingiva is usually pale-pink, firm, and leathery in consistency and presents a characteristic pebbled surface. The condition has been classified into two types, a nodular form characterized by the presence of multiple tumors in the dental papillae and a symmetric form, which results in a uniform enlargement of the gingiva. Associated clinical problems include poor esthetics, prolonged retention of deciduous teeth, abnormal occlusion, inadequate lip closure, and difficulty in eating and speaking.^[11]

Histologically, insulin-like growth factor (IGF) is described to have a moderate hyperplasia of the epithelium with hyperkeratosis and elongation of the rete pegs. The increase in the tissue mass is primarily the result of an increase in thickening of the collagen bundles in the connective tissue stroma.^[11]

Many drugs such as cyclosporin^[12,13] an immunosuppressive drug, verapamil for treating angina,^[14] nifedipine for treating cardiac arrhythmia,^[15,16] and phenytoin a well-known anticonvulsant drug^[17] are all responsible for gingival overgrowth.

CASE REPORT

An 11-year-old girl accompanied by her parents reported to the department of pediatric and preventive dentistry with the chief complaint of swollen gums for 2 years. The gums started enlarging 2 years back, and for the post

^{1,3}Reader, ^{2,4}PG Student

^{1,2}Department of Pedodontics, Awadh Dental College and Hospital, Jamshedpur, Jharkhand, India

^{3,4}Department of Oral and Maxillofacial Surgery, Awadh Dental College and Hospital, Jamshedpur, Jharkhand, India

Corresponding Author: Dr. Pooja Pani, PG Student, Department of Pedodontics, Awadh Dental College and Hospital, Jamshedpur - 831 012, Jharkhand, India. Phone: +91-7484900360. e-mail: dr.poojapani@gmail.com

7 months, they had grown rapidly to the present size. There was no difficulty in eating and chewing. The patient was concerned about the esthetic appearance as she was unable to close her mouth due to the swollen gums. Family history revealed consanguineous marriage between the parents. The child was normally built with good motor coordination and no signs of hepatosplenomegaly were seen. The patient had two elder siblings, both brothers, and a detailed interviewing revealed that none of the family members presented with any such swelling.

On extraoral examination, the child had convex profile with incompetent everted lips. Intraoral examination revealed generalized diffuse enlargement of both maxillary and mandibular arch covering 2/3rd of the teeth on both sides. All premolars were submerged. Gingiva was pink, firm, bulbous, and nodular in nature. The uneven swelling of the attached gingiva presented a pebbled appearance. Orthopantomogram showed the presence of a complete dentition. All teeth had pierced the alveolar process but were prevented from being erupted by the enlarged fibrous gingival tissue. Generalized horizontal bone loss was evident with mandibular molars showing inter-radicular radiolucency. Radiolucent shadow of enlarged gingiva was also seen. The development of all teeth was age appropriate.

The treatment of choice in this condition was gingivectomy to satisfy patient's esthetic demands. An internal bevel incision was given 2-3 mm above the mucogingival junction to the crest of the alveolar process to remove the bulk of the enlarged gingiva. Mucoperiosteal flap was raised exposing the root surfaces followed by root planning and thorough debridement of the granulation tissue was done. Reapproximation of the flap was done by placing simple interrupted sutures. The patient was called every month for a routine checkup and no signs of recurrence were seen for 8 months.

Histological investigations of the enlarged tissue were done. The H and E stained sections revealed stratified squamous parakeratinized epithelium covering the fibrocellular connective tissue. Connective tissue showed varying amounts of chronic inflammatory cell infiltrate and few areas showed increased number of blood vessels. Similar results were seen from the gingivectomy specimens of maxillary and mandibular enlarged gingiva. The overall features were suggestive of focal fibrous hyperplasia/chronic non-specific infection [Figures 1-6].

DISCUSSION

The diagnosis of idiopathic gingival fibromatosis was made based on patients' medical and family history,

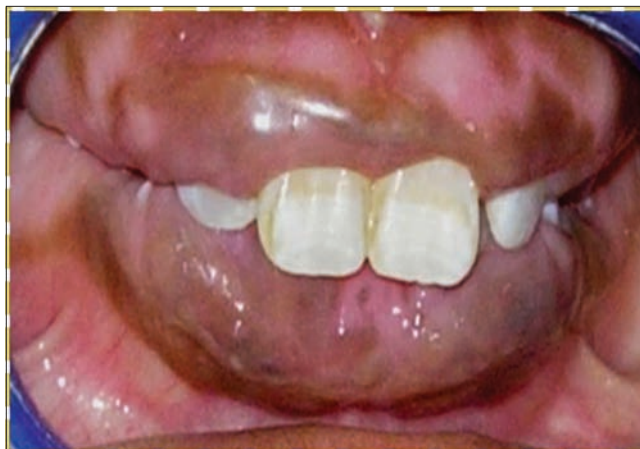

Figure 1: Pre-operative photograph

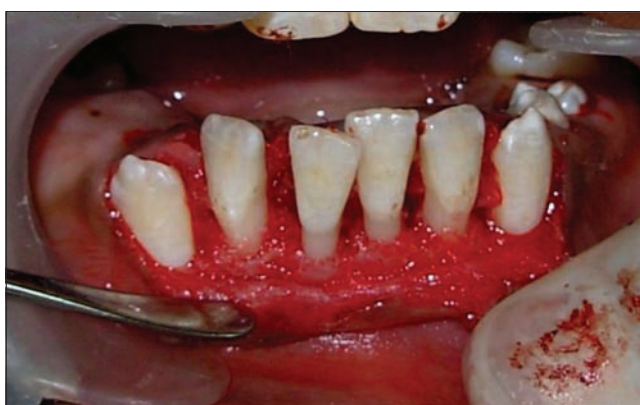

Figure 2: Flap raised

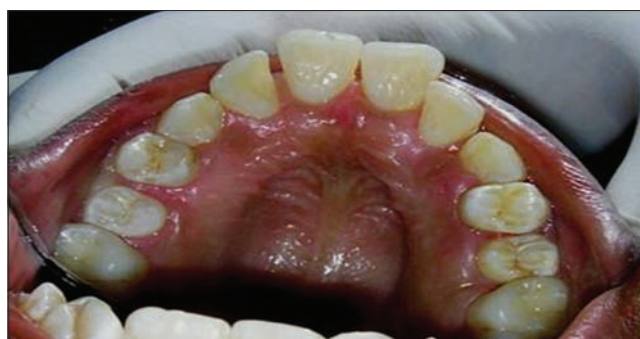

Figure 3: Post-operative photograph

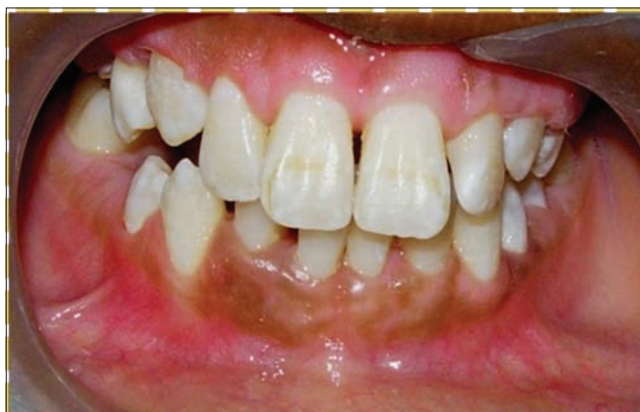

Figure 4: Post-operative photograph

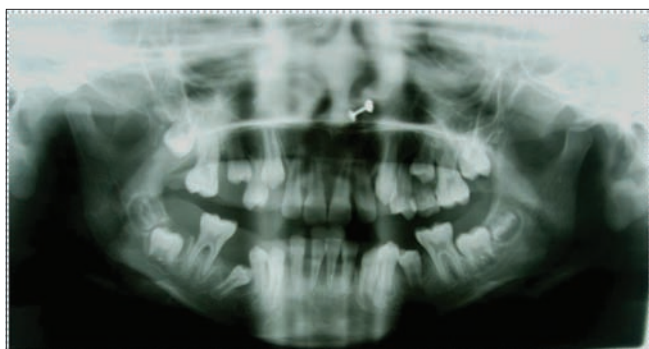

Figure 5: Orthopantomogram

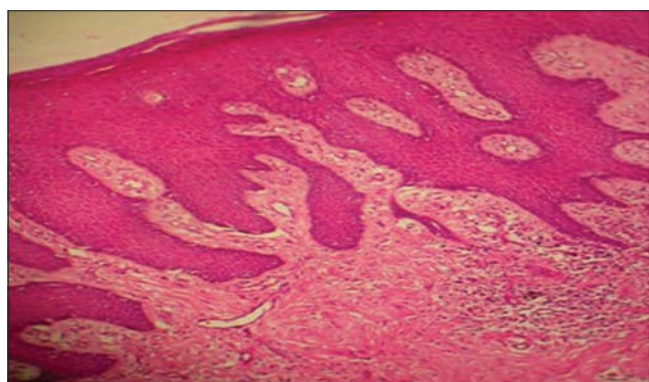


Figure 6: Histopathology

clinical presentation, radiographic findings, and histopathological examination. Idiopathic gingival fibromatosis manifests due to congenital or hereditary causes which is not understood accurately. Some authors have proposed the mode of transmission as mainly autosomal dominant, suggesting abnormal chromosome on phenotype 2p21.^[8,9] Various other factors responsible for idiopathic gingival fibromatosis include inflammation, leukemic infiltration, and drugs such as phenytoin,^[17] verapamil,^[14] cyclosporin,^[12,13] and nifedipine.^[15,16] Gingival proliferation is caused by one or more causes including an increase in proliferation of resident tissue fibroblasts, a reduced level of metalloproteinases synthesis (matrix metalloproteinases-1 and matrix metalloproteinase-2), resulting in low degradation of the extracellular matrix and an increase in collagen Type I production and heat-shock protein 47.^[5]

It is associated with many syndromes such as Ramon syndrome (IGF, mental retardation, hypertrichosis, and epilepsy),^[5,6] Rutherford syndrome (IGF and coronal dystrophy), Laband syndrome^[4] (IGF, ear, nose, nail, and bone defects with hepatosplenomegaly), the Cross syndrome^[4] (IGF, microphthalmia, mental retardation, athetosis, and hypopigmented skin), Murray-Puretic-Drescher syndrome^[4] (IGF with multiple hyaline fibromas), and Jones syndrome^[4] (IGF with sensorineural deafness). Our patient had no clinical findings that fulfilled any of these possible syndromes.

Table 1: Causes of generalized gingival fibromatosis

Hyperplastic gingivitis
Mouth breathing gingivitis
Drug-induced gingival overgrowth
Scurvy
Gingival overgrowth in pregnancy
Gingival overgrowth due to leukemia
Hereditary gingival fibromatosis
Wegener granulomatosis
Acanthosis nigricans
Idiopathic variety

Sometimes, gingival enlargement does not occur until the eruption of the primary^[18] or permanent^[19] dentition. It has been suggested that IGF may be due to nutritional and hormonal factors, but this too is not proven. Due to massive gingival enlargement, an affected child usually develops abnormal swallowing pattern and experiences difficulty in speech and mastication.^[17] At first, the gingiva is smooth and finely stippled, but with age, they become coarser and may throw papillary projections. The lesion more commonly involves the molar segments, especially upper molars. Labial enlargement in maxillary anterior region leads to an open lip posture and mouth breathing, which, in turn, leads to further enlargement. The enlargement creates conditions favorable for accumulation of plaque and material alba, hence, accentuating the depth of the gingival sulci. In such cases, secondary inflammatory changes may obscure the preexisting non-inflammatory enlargement. Idiopathic gingival enlargement is differentiated from chronic inflammatory hyperplasia by the absence of reddening of papillae, no loss of stippling, and absence of pitting on pressure.^[10]

Histologically, gingival hyperplasia is mainly due to an increase and thickening of collagen bundles.^[18] The nodular appearance can be attributed to the thickened parahyperkeratinized epithelium.^[19] Various treatment modalities have been proposed, but the treatment of choice in this condition is gingivectomy.

Recurrence rate in IGF is very high after surgery and because of this the patient should be followed for a considerable period of time and may require repeated surgeries. Appropriate time for removal of the gingival enlargement is at the age of 3, 6, and 12 years to have effective plaque control and to maintain oral hygiene after gingivectomy procedure. Emerson^[20] recommended that the best time is when all the permanent teeth have erupted. This often leads to increase in the patient's and parents psychological and emotional stress. Hence, psychological counseling is a must for patients and parents [Tables 1 and 2].

Table 2: Syndromes associated with gingival fibromatosis

Syndrome	Clinical features	Mode of inheritance
Laband syndrome	Syndactyly, nose and ear abnormalities, hyperplasia of the nails, and terminal phalanges	Dominant
Rutherford syndrome	Corneal dystrophy	Dominant
Cross syndrome	Microphthalmia, mental retardation, and pigmentary defects	Recessive
Ramon syndrome	Hypertrichosis, mental retardation, delayed development epilepsy, and cherubism	Recessive

REFERENCES

- Cekmez F, Pirgon O, Tanju IA. Idiopathic gingival hyperplasia. *Int J Biomed Sci* 2009;5:198-200.
- Carranza FA, Hogan EL. Gingival enlargement. In: Newman MG, Takei HH, Carranza FA, editors. *Clinical Periodontology*. 9th ed. Philadelphia, PA, USA: Saunders; 2002. p. 279-96.
- Hart TC, Pallos D, Bowden DW, Bolyard J, Pettenati MJ, Cortelli JR. Genetic linkage of hereditary gingival fibromatosis to chromosome 2p21. *Am J Hum Genet* 1998;62:876-83.
- Hart TC, Pallos D, Bozzo L, Almeida OP, Marazita ML, O'Connell JR, et al. Evidence of genetic heterogeneity for hereditary gingival fibromatosis. *J Dent Res* 2000;79:1758-64.
- Bozzo L, de Almeida O, Scully C, Aldred MJ. Hereditary gingival fibromatosis. Report of an extensive four-generation pedigree. *Oral Surg Oral Med Oral Pathol* 1994;78:452-4.
- Bozzo L, Machado MA, de Almeida OP, Lopes MA, Coletta RD. Hereditary gingival fibromatosis: Report of three cases. *J Clin Pediatr Dent* 2000;25:41-6.
- Martelli H Jr., Lemos DP, Silva CO, Graner E, Coletta RD. Hereditary gingival fibromatosis: Report of a five-generation family using cellular proliferation analysis. *J Periodontol* 2005;76:2299-305.
- Singer SL, Goldblatt J, Hallam LA, Winters JC. Hereditary gingival fibromatosis with a recessive mode of inheritance. Case reports. *Aust Dent J* 1993;38:427-32.
- Chaturvedi R. Idiopathic gingival fibromatosis associated with generalized aggressive periodontitis: A case report. *J Can Dent Assoc* 2009;75:291-95.
- Coletta RD, Graner E. Hereditary gingival fibromatosis: A systematic review. *J Periodontol* 2006;77:753-64.
- DeAngelo S, Murphy J, Claman L, Kalmar J, Leblebicioglu B. Hereditary gingival fibromatosis-a review. *Compend Contin Educ Dent* 2007;28:138-43.
- Kelekis-Cholakakis A, Wiltshire WA, Birek C. Treatment and long-term follow-up of a patient with hereditary gingival fibromatosis: A case report. *J Can Dent Assoc* 2002;68:290-4.
- Ramer M, Marrone J, Stahl B, Burakoff R. Hereditary gingival fibromatosis: Identification, treatment, control. *J Am Dent Assoc* 1996;127:493-5.
- Baptista IP. Hereditary gingival fibromatosis: A case report. *J Clin Periodontol* 2002;29:871-4.
- Tiwana PS, De Kok IJ, Stoker DS, Cooper LF. Facial distortion secondary to idiopathic gingival hyperplasia: Surgical management and oral reconstruction with endosseous implants. *Oral Surg Oral Med Oral Pathol Oral Radiol Endodontol* 2005;100:153-7.
- Sapp JP, Eversole LR, Wysocki GP. Connective tissue lesions. In: *Contemporary Oral and Maxillofacial Pathology*. 2nd ed. London, UK: Mosby; 2004. p. 294-7.
- Neville BW, Damm DD, White DH. Soft tissue tumours. In: *Colour Atlas of Clinical Pathology*. 2nd ed. Hamilton, Canada: Decker; 2003. p. 276-312.
- Indushekar KR. Idiopathic gingival fibromatosis. Case report. *Saudi Dent J* 2003;14:143-5.
- Tavageri AK, Kulkarni SS, Basavprabhu SP. Idiopathic gingival fibromatosis-a case report. *J Indian Soc Pedod Prev Dent* 2004;22:180-2.
- Emerson TG. Hereditary gingival hyperplasia. A family pedigree of four generations. *Oral Surg Oral Med Oral Pathol* 1965;19:1-9.