

Odontoid Fractures: 7-Year Experience from a Tertiary Care Referral Center in South India

¹Ankush Gupta, ²Bijesh Ravindran Nair, ³Vivek Joseph

ABSTRACT

Introduction: Odontoid fractures form about 10% of all cervical spine injuries. We looked at our 7-year experience with odontoid fractures.

Material and methods: A retrospective analysis of all patients admitted with a diagnosis of odontoid fracture, in a neurosurgical unit of Christian Medical College, Vellore, India, during the period from April 2008 to January 2015 was done. Their pre- and -postoperative clinical status, radiology, treatment given, outcomes and complications were assessed.

Results: Twenty-three patients with odontoid fractures were treated during this period, predominantly males (n = 21) and with a mean age of 37 years. There were 17 Type II fractures and 6 Type III fractures. Eight patients were managed with anterior odontoid screw fixation, eight with posterior instrumented fusion and four underwent a transoral odontoidectomy followed by posterior fusion. Three patients were conservatively managed (two with halo fixation and one with cervical collar). Two patients developed cut out of the anterior odontoid screw through the C2 body, thereby requiring posterior fusion. There was no mortality in our series. At a mean follow-up duration of 24.6 months (n = 17), there was no worsening of American Spinal Injury Association (ASIA) grade clinically, with evidence of radiological fusion in all cases except the one case managed with a cervical collar.

Conclusion: Odontoid fractures can be managed in a variety of ways. Choosing the appropriate treatment for each patient is important. Bony fusion in a reduced position is the goal of the treatment.

Keywords: odontoid; fracture; spine; cervical; trauma; fusion.

How to cite this article: Gupta A, Nair BR, Joseph V. Odontoid Fractures—7-Year Experience from a Tertiary Care Referral Center in South India. *J Spinal Surg* 2018;5(3):107-114.

Source of support: Nil

Conflict of interest: None

INTRODUCTION

The cervical spine is the most common site for post-traumatic vertebral fractures, of which nearly 10% involve the

odontoid process of the axis (C2) vertebra. Majority of the axis fractures are odontoid fractures, with Type II odontoid fracture being the commonest, resulting in fracture at the junction of the odontoid process with the body of C2.^{1,2} The epidemiological trend of Type II odontoid fractures has been changing and is being increasingly seen in the elderly. These fractures are known to be unstable, and hence the rates of non-fusion with conservative management can be as high as 85%.³ Type I and Type III odontoid fractures have higher fusion rates with external immobilization. The plausible reasons for this are that Type II fractures lead to disruption of the vascularity of the dens, resulting in poor quality of the trabecular bone.⁴ Also, the incidence of spinal cord injury and neurological deficits with odontoid fractures is less frequent, probably due to the wide spinal diameter at that level.⁵

We reviewed our experience with treating odontoid fractures over a 7-year period, as a large proportion of patients come to us with a remote history of trauma.

MATERIALS AND METHODS

This was a retrospective study looking at the patients with odontoid fractures treated from April 2008 to January 2015 in a neurosurgical unit of Christian Medical College, Vellore, India. Their in-patient records were reviewed, and their clinical condition, radiological findings, and treatment given were recorded. The clinical status of the patients was classified based on the ASIA classification. On follow-up, their clinical (ASIA grade) and radiological outcomes, including complications, were assessed.

Odontoid fractures were classified according to the Andersen and D'Alonzo classification of odontoid fractures.⁶ All patients had a lateral cervical spine plain radiograph, magnetic resonance imaging (MRI) and a non-contrast computed tomography (CT) scan of the cervical spine with 3D reconstruction. Additional findings noted on the CT of the cervical spine were the amount of displacement of the fractured segment (if any) and the obliquity of the fracture line.

Surgical Technique

The odontoid fracture fixation was undertaken either through an anterior approach or a posterior approach. The anterior surgeries were either an anterior odontoid

¹Postgraduate Registrar, ²Associate Professor, ³Professor

¹⁻³Department of Neurological Sciences, Christian Medical College, Vellore, Tamil Nadu, India

Corresponding Author: Vivek Joseph, Professor, Department of Neurological Sciences, Christian Medical College, Vellore, Tamil Nadu, India, e-mail: vivek.joseph@cmcvellore.ac.in

screw fixation or a transoral odontoidectomy. The transoral procedure was always followed by posterior fusion, either a C1-C2 lateral mass fusion or occasionally an occipitocervical fusion. The posterior surgeries comprised C1-C2 transarticular screw fixation with modified Gallie's fusion, C1-C2 lateral mass screw fusion or an occipitocervical fusion. In cases of displaced fractures, all patients underwent preoperative skeletal traction, and an attempt was made to reduce the displacement intraoperatively under fluoroscopic guidance.

Postoperative care and Follow-up

All patients were kept on rigid immobilization using a Philadelphia cervical collar for up to 3 months and were advised regular limb physiotherapy, incentive spirometry, and shoulder mobilization exercises. Follow-up was obtained through outpatient consultation or telephonically when feasible. Patients were typically asked to review after 3 months, and cervical spine plain radiographs were obtained (anteroposterior, and lateral in neutral, flexion and extension).

RESULTS

Patient Population

A total of 23 patients with odontoid fractures were treated during the period April 2008 to January 2015. There was a male preponderance within the cohort (91% males, n = 21). The mean age at presentation was 37 years, ranging from 20 to 68 years (median: 32 years). Not all the odontoid fractures were acutely sustained, and a fair proportion of patients had sustained remote injury. The time gap between occurrences of injury to the presentation in hospital ranged from 2 days to 20 years (median: 21 days; mean: 383 days).

Clinical Presentation (Table 1)

The most common mode of injury was motor vehicle accidents (MVAs), occurring in 13 patients (56.5%). Neck pain was the commonest presenting symptom, being present in almost all patients. On examination, quadriplegia was present in eight patients whereas 10 patients did not have any focal neurological deficits. The remaining five patients either had a hemiparesis or monoparesis, with features of cord compression. In all, 13 patients (56.5%) had evidence of spinal cord injury (SCI). According to the ASIA grading scale, one patient was ASIA grade C, 12 were ASIA grade D, and 10 were ASIA grade E.

Table 1: Clinical presentation of the cohort.

	Number of patients (%)
<i>Mode of injury</i>	
Motor vehicle accident	13 (56.5)
Fall from height	8 (34.8)
Assault	1 (4.3)
No history of trauma	1 (4.3)
<i>Neurological status</i>	
No deficits	10 (43.5)
Quadriplegia	8 (34.8)
Hemiparesis	3 (13)
Monoparesis (with sensory level)	2 (8.7)
<i>ASIA grade</i>	
C	1 (4.3)
D	12 (52.2)
E	10 (43.5)

Radiology (Table 2)

17 patients were diagnosed to have Type II odontoid fractures, whereas the remaining six patients had a Type III fracture. There were no Type I fractures in our cohort. There was displacement of the fractured dens over the C2 body in all cases, with anterior displacement present in 17 patients (73.9%) and posterior displacement in six patients (26.1%). The mean displacement was 7.1 millimeters (mm), ranging from 2.5 to 15 mm. There was a complete displacement of the dens over the C2 body in six cases. The direction of the fracture line was divided into anterior oblique (n=9), posterior oblique (n=8) and horizontal (n=6). Cervical traction was applied to 19 patients preoperatively. Among these 19 patients, there was a reduction of the displaced fracture in 11 cases (57.9%).

Table 2: Radiological profile of the cohort.

	Number of patients (%)
<i>Type of fracture</i>	
Type II	17 (73.9)
Type III	6 (26.1)
<i>Displacement of dens over C2 body</i>	
<i>Anterior</i>	
Type II (n = 17)	11 (64.7)
Type III (n = 6)	6 (100)
<i>Posterior</i>	
Type II (n = 17)	6 (35.3)
Type III (n = 6)	0
<i>Direction of fracture line</i>	
Anterior oblique	9 (39.1)
Posterior oblique	8 (34.8)
Horizontal	6 (26.1)

Treatment

Three patients in the cohort were managed conservatively, out of which two underwent external immobilization using a halo fixation, and one patient was immobilized with a Philadelphia cervical collar. Both the patients who underwent halo-fixation had Type III fractures. (Fig. 1) The patient who was managed with a cervical collar was a 68-year old lady (the oldest patient of our cohort) who did not have any focal neurological deficits at presentation. Her CT cervical spine showed a Type II odontoid fracture with posterior displacement of the dens, with a displacement of 3 mm. She also suffered from Rheumatoid arthritis, and had a history of trauma 11 months prior to presentation. She opted against surgery, hence was managed conservatively. On a 13-month follow-up, there was no evidence of bony fusion. Her ASIA grade was E, both at presentation and at follow-up.

Eight patients underwent an anterior odontoid screw fixation (Fig 2). This was done typically in patients who had an anterior displacement of the dens; although one patient out of these had a posterior displacement of nearly 4 mm. Four patients underwent a transoral odontoidectomy and C2 median corpectomy, followed by either occipito-cervical fusion or C1-C2 lateral mass fusion. All of these 4 patients had spondyloptosis of the fractured dens, which did not reduce adequately on traction and when positioned for surgery under GA. Three out of these had anteriorly displaced dens, and the mean displacement ($n = 4$) was 11.1 mm (range, 7-15 mm). Posterior

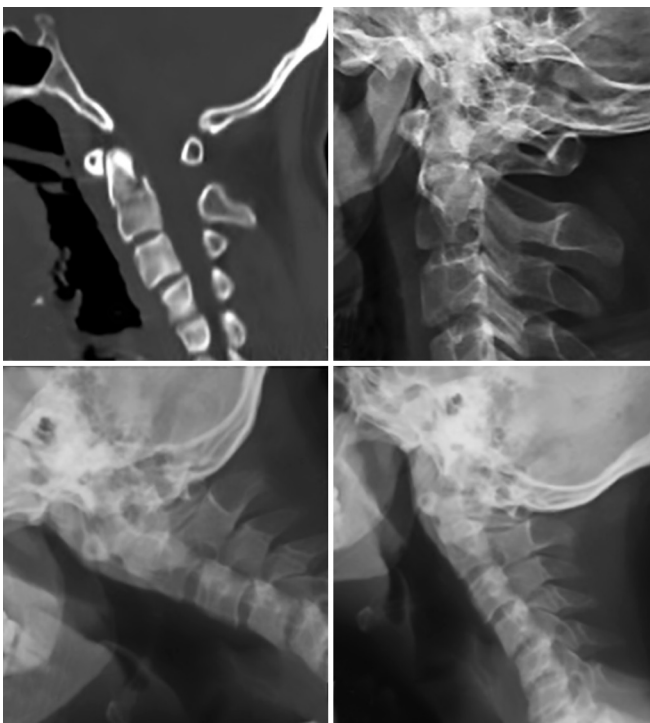

Fig. 1: 32-year old male with a Type III odontoid fracture (a,b) managed with Halo-fixation. On a 6-month follow-up, there is evidence of bony fusion and no instability on the flexion (c) and extension (d) imaging.

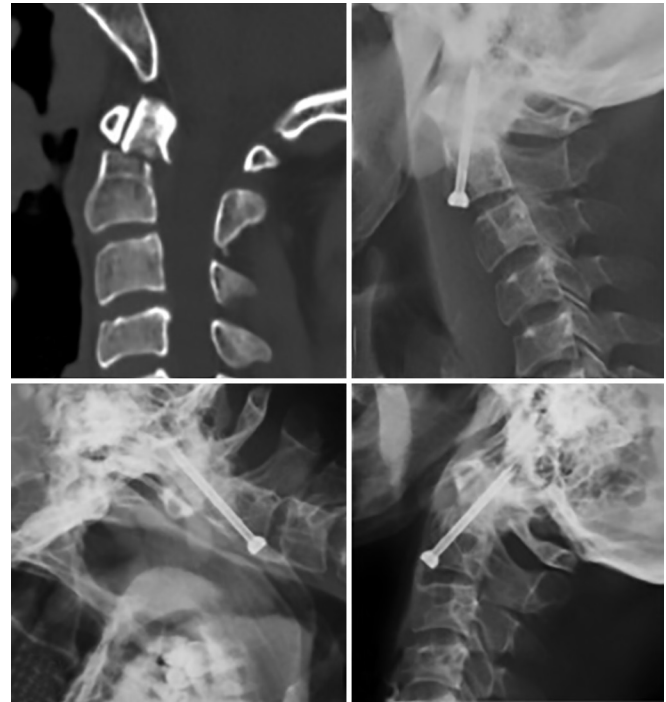

Fig. 2: 34-year old male with a posteriorly displaced type II odontoid fracture. (a) Preoperative CT sagittal images showing the displaced fracture. This patient underwent an anterior odontoid screw fixation and the immediate postoperative lateral radiograph showed good reduction of the fracture (b). 3-year follow-up lateral radiographs show the anterior odontoid screw in situ and bony fusion, with no evidence of instability on flexion (c) or extension (d) images.

fusion alone was performed in the remaining 8 patients, using C1-C2 transarticular screw fixation ($n = 5$) (Fig 3.), C1-C2 lateral mass screws ($n = 1$), occipito-cervical fusion ($n = 1$) or a C1-2 modified Brook's fusion ($n = 1$) (Fig 4.). Iliac crest autograft was used in all patients for fusion.

Complications and morbidity

There were no intraoperative complications in the cohort. Postoperatively two patients developed transient dysphagia and dyspnea, which resolved spontaneously. One patient developed a systemic infection that was treated with intravenous antibiotics. Two patients who underwent an anterior odontoid screw fixation developed anterior cut out of the screw from the C2 body with the screw tip still secure in the fractured odontoid fragment, thereby requiring posterior instrumented fusion for stabilization (Fig 5). Both these patients had Type III odontoid fractures. To analyze the cause of screw cut out, we measured the distance between the anterior margin of C2 body (at the fracture line) and the anterior margin of the odontoid screw ($n = 8$), and found the mean distance to be 2.6 mm (range, 1-5 mm). Both patients, who developed cut out of the screws, had a distance of 1 mm between the anterior margin of C2 body and the odontoid screw, which could translate into a more vertical trajectory of screw placement. These two patients however did not

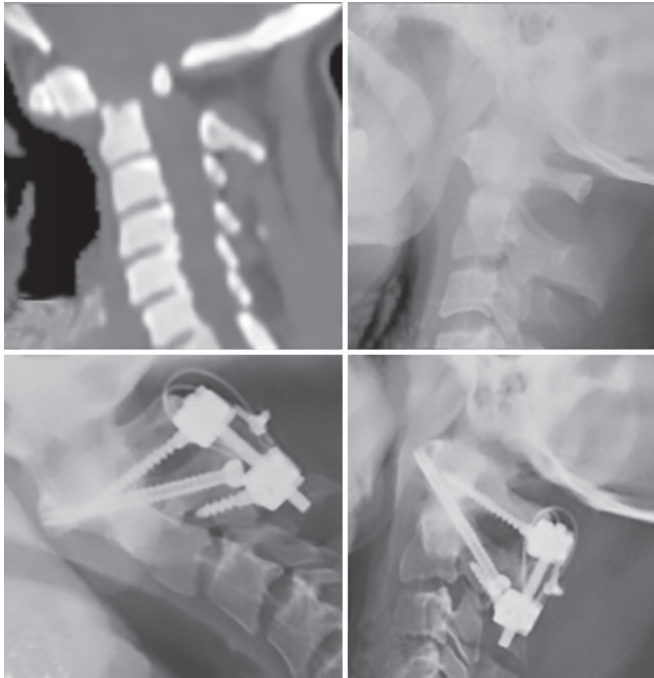

Fig. 3: 49-year old male with a completely displaced type II odontoid fracture (a) that reduced on traction (b). He underwent a C1-2 left transarticular screw insertion and right C1, C2 lateral mass screw fixation. 1 year follow-up lateral radiographs (c) flexion, (d) extension show bony fusion and no instability.

develop any new neurological deficits and were ASIA grade E at presentation and on last follow-up. There was no mortality in our series.

Follow-up (Table 3)

Follow-up was obtained either through outpatient consultation or telephonically. Plain cervical spine radiographs (anteroposterior and dynamic lateral views) were obtained on follow-up. Follow-up of at least 3 months could be obtained in 17 patients (74%), with a mean follow-up duration of 24.6 months (range, 3 to 82 months; median: 14.6 months). At the last follow-up, there was no worsening of ASIA grade clinically. The patient that was ASIA grade C preoperatively, improved to ASIA grade D at follow-up. 3 out of 10 patients who were ASIA grade D preoperatively (for whom follow-up data was available) improved to ASIA grade E, whereas the rest remained the same. All patients who were ASIA grade E preoperatively continued to remain so at follow-up. The neurological outcome of patients is depicted in Table 3.

Table 3: Neurological outcome of the patients (n=23). Clinical follow-up could be obtained in 17 patients (74%).

Preoperative ASIA grade	Follow-up ASIA grade			Total
	Lost to follow-up	D	E	
C	0	1	0	1
D	2	7	3	12
E	4	0	6	10
Total	6	8	9	23

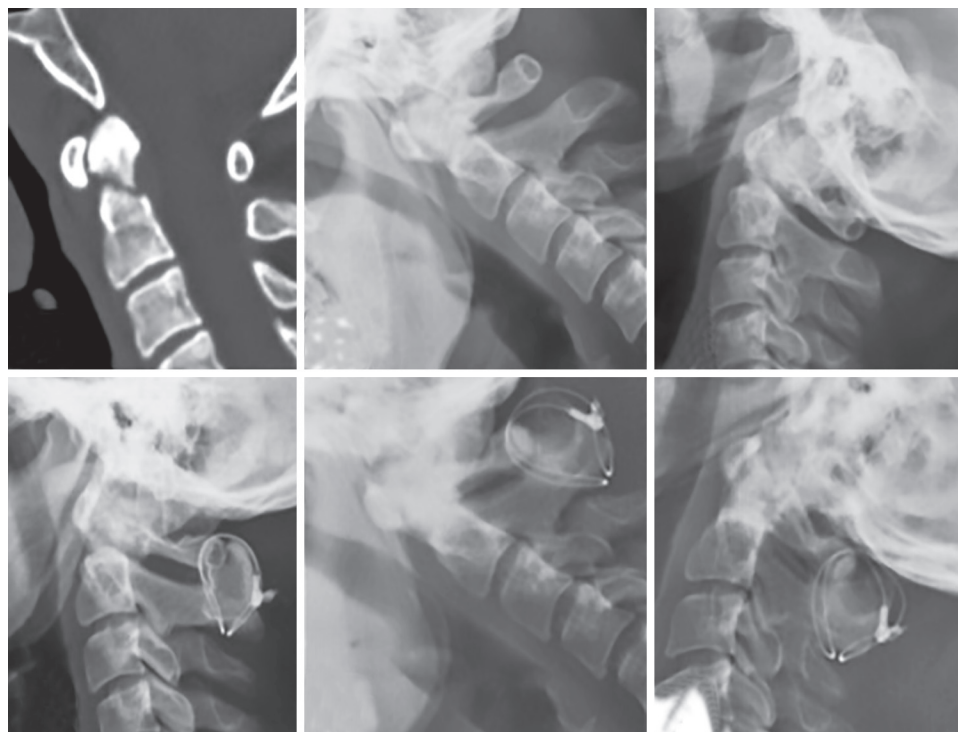


Fig. 4: 25-year old male with a minimally displaced type II odontoid fracture.(a) Preoperative CT sagittal images of the cervical spine. Preoperative flexion (b) and extension (c) radiographs showed no significant movement. As he had severe neck pain and restriction of neck movement, he was offered surgery and underwent a C1-2 modified Brook's fusion. (d) Immediate postoperative lateral radiograph showing the construct in situ. 1 year follow-up lateral radiographs showing bony fusion and no instability on flexion (e) and extension (f) images.

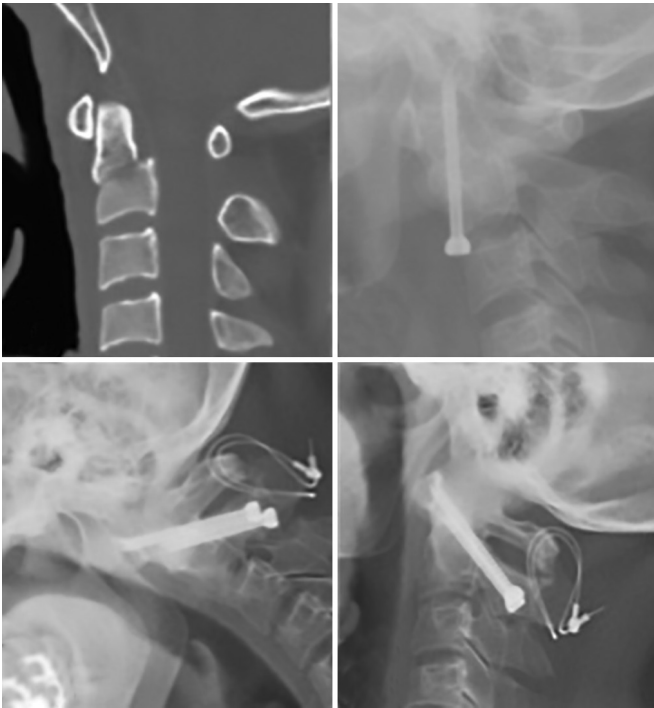


Fig. 5: 28-year old male with a Type III odontoid fracture as shown on the sagittal CT images (a). This patient underwent an anterior odontoid screw placement. Third postoperative day lateral radiograph (b) showing cut-out of the odontoid screw from the C2 body. This patient then underwent removal of the odontoid screw followed by a C1-2 transarticular screw fixation. One year follow-up radiographs do not show any instability on flexion (c) and extension (d) images.

On follow-up radiological assessment, there was no movement seen on the flexion and extension cervical spine lateral radiographs of all patients with bony fusion in all patients, except for the one patient with rheumatoid arthritis who was managed with a cervical collar.

DISCUSSION

Incidence of spinal cord injury

The global incidence rate of traumatic SCI is estimated to be nearly 23 cases per million per annum, with a slightly higher estimate of 25.5 cases per million per annum in developing countries.^{7,8} About 55% of spinal cord injuries affect the cervical spine and C2 fractures form nearly 20% of cervical spine injuries. The most common type of C2 fracture is the type II odontoid fracture. Smith et al.³ found that type II odontoid fractures formed 4.73% of all spinal fractures. Even though odontoid fracture is the most common type of C2 fracture, the incidence of SCI at this level is not correspondingly high. This is due to the large capacious spinal canal at this level and the anterior cervical subarachnoid space playing a significant role in buffering the canal compromise caused by the fractured odontoid, thereby preventing damage to the cord.⁵ Anderson et al.⁶ found that 45 of their 60 patients

(75%) did not have spinal cord injury at presentation, and 1 patient developed a late myelopathy. Harrop et al.⁵ reported on a series of 5096 admitted patients with spinal injuries. 2749 had neurological injury, of which 17 (0.62%) had odontoid fractures. This was in contrast to the 2347 patients who did not have neurological injury, of which 209 (8.9%) had odontoid fractures. So in their group of 226 patients with type II odontoid fractures, 17 patients (7.5%) had neurological deficits. The incidence of SCI in Type II odontoid fractures has been reported in literature to be as high as 27%.^{5,8,9} Smith et al.³ identified 268 patients with type II odontoid fractures, of which 8 were excluded, as their medical records could not be located. In the remaining 260, 45 patients (17.3%) had evidence of neurological injury. In our cohort of 23 patients, 13 patients (56.5%) had evidence of SCI, which is high compared to that in literature. It is likely that since we are a tertiary care referral hospital, patients with neurological deficits would have preferentially been referred, while those without deficits may have been treated locally. Also, in the absence of neurological deficits, patients may not have sought medical care.

Epidemiology

In the USA, the average age of patients with SCI has increased from 28.7 years (during the period 1973 – 1979) to 41 years, since 2005. This is in keeping with an overall increase in average life span by 9 yrs over the same period.¹⁰ The classic paper on odontoid fractures by Anderson and D'Alonzo⁶ included 60 patients with a mean age of 40.7 years, ranging from 3 yrs to 76 yrs. Smith et al.³ documented a mean age of 84.3 yrs in 192 patients with acute type II odontoid fractures, who were neurologically intact. In our cohort of 23 patients, the mean age was 37 years, with age range from 20 yrs to 68 yrs. It appears that the age at presentation probably depends on the average age of the population in the catchment area for that hospital.

Overall, about 80% of SCIs occurs in males.¹⁰ In Apfelbaum's series of 147 consecutive patients with odontoid fractures who underwent anterior odontoid screw placement, 67% were males and 33% were females.¹¹ In our cohort of 23 patients, the vast majority [91% (n=21)] were males, in keeping with the male predominance seen in patients with spine injuries.

The mechanism of injury causing odontoid fractures also shows a varying trend with age. They can occur in all age groups, though younger patients sustain these fractures following MVAs and older patients following a fall. Smith et al.³ in their older cohort of patients found that the mean age of patients sustaining type II odontoid fracture due to a fall was 11.3 years more than that due

to a MVA (mean age 85.3 years versus 74 years, $p < 0.001$). We had one patient with neck pain for 6 months with radiological evidence of Type II odontoid fracture, but the patient was unable to recall any trauma. Among the remaining patients, those who sustained a fall ($n=8$) had a mean age of 47 years (range, 28 to 68 years; median: 48 years), while those who had MVA ($n = 13$) had a mean age of 29 years (range, 20–58 years; median: 26 years). So, the group of patients who sustained a fall was on an average, 18 years older than the group that had MVAs ($p = 0.001$).

In our series, the duration between the dates of injury to presentation had a wide range from 2 days to 20 years (mean: 383 days), though most injuries were recent (median: 21 days). In the 147 consecutive cases reported by Apfelbaum et al., there were 129 cases (87.8%) with recent fractures (< 6 months old) and 18 cases (12.2%) with remote fractures (> 18 months old).¹¹ Similarly, in our series ($n=23$), we had 2 patients (8.7%) with injury of more than 18 months, all the remaining patients (91.3%) had injuries of less than 6 months duration.

Treatment guidelines for Management of Odontoid fractures

The joint section on disorders of the spine and peripheral nerves of the AANS and CNS in 2013¹² suggested that there was level II evidence recommending surgical stabilization and fusion in patients over the age of 50 years, with Type II odontoid fractures. There was Level III evidence recommending external cervical immobilization for non-displaced Type I, II and III fractures, although the rates of union in type II fracture were lower as compared to the others. Surgical stabilization was also indicated for type II and type III fractures with dens displacement ≥ 5 mm, comminution of the odontoid or inability to achieve fracture alignment with external immobilization (level III evidence).^{12,13} In our series of 23 patients, the mean displacement of the fractured odontoid process was 7 mm, ranging from 2.5 to 15 mm (median: 6 mm). Three patients were treated without surgical intervention in our series—2 with halo-fixator (Type III fractures) and one with Philadelphia cervical collar (Type II fracture). The mean displacement of the fractured odontoid process in these three cases was 2.9 mm.

Both anterior (odontoid screw fixation) and posterior (C1/C2 transarticular/lateral mass screw fixation with modified Gallie's/Brook fusion) stabilization have high fusion rates. Anterior odontoid screw fixation has an additional advantage of preserving rotatory movement at the atlanto-axial joint, at the expense of causing transient dysphagia.^{2,14,15,16} In our series, eight patients underwent anterior odontoid screw placement. The time to intervention for these patients ($n = 8$) ranged from 6 to 21 days

(mean: 13.25 days; median: 11 days). Two of these patients required revision surgeries later (transoral surgery followed by posterior C1/C2 lateral mass screw fixation in one patient, and bilateral transarticular C1/C2 fixation in the other). These patients had Type III fractures, and the distance between the anterior margin of the C2 body (at the fracture line) and the anterior margin of the screw was 1 mm. Hence in Type III odontoid fractures, the decision of anterior odontoid screw fixation must be made cautiously.

8 patients underwent a posterior fixation alone, with the mean time to intervention being nearly 3 months (range, 3 days-6 months). Occipitocervical fusion was done in one patient who had a comminuted fracture of the odontoid, along with lateral displacement of C1 and rotation, thereby making C1-C2 fixation technically difficult. One other patient with a type III odontoid fracture was planned for an anterior odontoid screw fixation, but was detected to have a barrel-shaped chest, which restricted the appropriate trajectory of screw placement, and he subsequently underwent a C1-C2 transarticular fixation. 4 other patients, all of whom had a Type II odontoid fracture that reduced on traction, also underwent a C1-2 transarticular fixation. 1 patient underwent a C1-2 instrumented fusion with lateral mass screws and rods. 1 patient presented 4 months after trauma, with a minimally displaced Type II odontoid fracture, after a failure of halo vest application done elsewhere. Dynamic cervical spine radiographs did not display any instability, however we offered him surgery as he complained of severe neck pain. Due to absence of instability, he underwent a C1-2 modified Brook's fusion, which provided good neck pain relief and radiological fusion on follow-up. Four patients in our series underwent transoral odontoidectomy followed by posterior fusion (occipitocervical fusion in 2, and C1-C2 lateral mass fusion in 2). All these patients had significant displacement of the fractured odontoid process, with a mean displacement of 8.9 mm.

Complications and Morbidity

Apfelbaum et al.¹¹ in their series of 147 patients, who underwent anterior odontoid screw fixation, had 7 mortalities (4.7%) at 30 days from surgery, of which 1 was attributed to surgery. Postoperative hardware related complications were seen in 9% of patients who had recent fractures (screw cut out through the anterior surface of C2 cortex being the commonest, followed by screw backing out) and in 25% of patients who had remote fractures (screw fracture being the commonest). They also demonstrated high rates of non-union in cases of remote fractures.¹¹ Subach et al.¹⁷ reported a fusion rate of 96% at a mean follow-up of 30 months, and did not have any

complications in their series of anterior odontoid screw fixation. They however reported 2 cases (8%) in which they had technical difficulties in anterior odontoid screw placement, one requiring rigid external immobilization and the other requiring posterior atlanto-axial arthrodesis. In our series, the overall morbidity rate was 8.69%, with two patients having hardware related complications, both being cut-out of the anterior odontoid screw through the C2 body. Both these patients had Type III odontoid fractures that were recognized preoperatively. However we felt that an anterior odontoid screw could be placed in these cases. The plausible cause of screw cut out in these cases could be that the purchase of the screw within the C2 body was inadequate, due to the fracture line through the body. A similar issue was also faced by Apfelbaum et al.¹¹ Hence it could be said that although anterior odontoid screw fixation remains a treatment option for Type III odontoid fractures, one should bear in mind the chances of screw cut out through the anterior cortex of C2, in cases of inadequate screw purchase through the C2 body.

Follow up and Outcome

Surgical outcomes for odontoid fractures have been good, with fusion rates in literature ranging from 77% to 100%.¹⁸⁻²² Higher degree of displacement of the fractured dens has been implicated as one of the factors leading to non-union; however there have been conflicting reports in literature. Also, remote fractures (> 18 months old) are more prone to non-union or fibrous union.¹¹ We were able to achieve a minimum 3-month follow-up in 74% of our patients, and demonstrated bony fusion in all except one who was managed with a Philadelphia collar. There were no instances of neurological worsening in our series.

Limitations

The limitations of our study are that the number of patients included is fairly small, and being a retrospective study, follow-up compliance is an issue. Also, on reviewing patient records, the exact reason for choosing one surgical approach over the other was not properly documented, and hence an algorithmic approach to odontoid fractures could not be formulated.

CONCLUSION

With the increasing average age of population, the incidence of odontoid fractures has been shown to be gradually rising. Various management strategies and surgical approaches have been described in literature, with satisfactory outcomes. Type I and type III fractures managed with external immobilization have shown good fusion rates, although surgical stabilization increases the

fusion rates further (in displaced Type III fracture) to the order of 100%. Management of type II odontoid fractures favors surgical stabilization, as fusion rates with external immobilization are not as good as those achieved in Type III fractures. The choice of surgical approach should be individualized according to the nature of fracture (direction of fracture line, displacement and the time from injury) and also according to the surgeon's comfort and expertise. Anterior odontoid screw fixation has an additional advantage of preserving rotatory motion at the atlanto-axial joint, but should be cautiously performed in Type III fractures.

REFERENCES

1. Hadley MN, Browner C, Sonntag VK. Axis fractures: a comprehensive review of management and treatment in 107 cases. *Neurosurgery* 1985;17(2):281-290.
2. Przybylski GJ. Introduction to odontoid fractures: controversies in the management of odontoid fractures. *Neurosurg Focus* 2000;8(6):1-3.
3. Smith HE, Kerr SM, Fehlings MG, Chapman J, Maltenfort M, Zavlasky J, et al. Trends in epidemiology and management of type II odontoid fractures: 20-year experience at a model system spine injury tertiary referral center. *Clin Spine Surg* 2010;23(8):501-505.
4. Heggeness MH, Doherty BJ. The trabecular anatomy of the axis. *Spine* 1993;18(14):1945-1949.
5. Harrop JS, Sharan AD, Przybylski GJ. Epidemiology of spinal cord injury after acute odontoid fractures. *Neurosurg Focus* 2000;8(6):1-4.
6. Anderson LD, D'Alonzo RT. Fractures of the odontoid process of the axis. *J Bone Jt Surg Am* 1974;56(8):1663-1667.
7. Lee BB, Cripps RA, Fitzharris M, Wing PC. The global map for traumatic spinal cord injury epidemiology: update 2011, global incidence rate. *Spinal Cord* 2014 Feb;52(2):110-116.
8. Rahimi-Movaghar V, Sayyah MK, Akbari H, Khorramirouz R, Rasouli MR, Moradi-Lakeh M, et al. Epidemiology of Traumatic Spinal Cord Injury in Developing Countries: A Systematic Review. *Neuroepidemiology* 2013 Jun 13;41(2):65-85.
9. Apuzzo ML, Heiden JS, Weiss MH, Ackerson TT, Harvey JP, Kurze T. Acute fractures of the odontoid process: An analysis of 45 cases. *J Neurosurg* 1978;48(1):85-91.
10. National Spinal Cord Injury Statistical Center. Spinal cord injury facts and figures at a glance. *J Spinal Cord Med* 2010;33(4):439-440.
11. Apfelbaum RI, Lonser RR, Veres R, Casey A. Direct anterior screw fixation for recent and remote odontoid fractures. *J Neurosurg* 2000 Oct;93(2 Suppl):227-236.
12. Ryken TC, Hadley MN, Aarabi B, Dhall SS, Gelb DE, Hurlbert RJ, et al. Management of isolated fractures of the axis in adults. *Neurosurgery* 2013;72(suppl_3):132-150.
13. Julien TD, Frankel B, Traynelis VC, Ryken TC. Evidence-based analysis of odontoid fracture management. *Neurosurg Focus* 2000;8(6):1-6.
14. Jaiswal AK, Sharma MS, Behari S, Lyngdoh BT, Jain S, Jain VK. Current management of odontoid fractures. *Indian J Neurotrauma* 2005;2(1):3-6.
15. Shilpakar S, McLaughlin MR, Haid Jr RW, Rodts Jr GE, Subach BR. Management of acute odontoid fractures: operative

- techniques and complication avoidance. *Neurosurg Focus* 1999;8(6):e3–e3.
16. Joaquim AF, Patel AA. Surgical treatment of Type II odontoid fractures: anterior odontoid screw fixation or posterior cervical instrumented fusion? *Neurosurg Focus* 2015;38(4):E11.
 17. Subach BR, Morone MA, Haid Jr RW, McLaughlin MR, Rodts GR, Comey CH. Management of acute odontoid fractures with single-screw anterior fixation. *Neurosurgery* 1999;45(4):812.
 18. Collins I, Min W-K. Anterior screw fixation of type II odontoid fractures in the elderly. *J Trauma Acute Care Surg* 2008;65(5):1083–1087.
 19. Chi Y-L, Wang X-Y, Xu H-Z, Lin Y, Huang Q-S, Mao F-M, et al. Management of odontoid fractures with percutaneous anterior odontoid screw fixation. *Eur Spine J* 2007;16(8):1157–64.
 20. Moon M-S, Sun D-H, Moon Y-W, Moon J-L. Treatment of Dens Fracture in Adults. *Bull NYU Hosp Jt Dis* 2006;63.
 21. Lee S-C, Chen J-F, Lee S-T. Management of acute odontoid fractures with single anterior screw fixation. *J Clin Neurosci* 2004;11(8):890–895.
 22. Platzer P, Thalhammer G, Ostermann R, Wieland T, Vécsei V, Gaebler C. Anterior screw fixation of odontoid fractures comparing younger and elderly patients. *Spine* 2007;32(16):1714–1720.