

Meandering Pancreatic Duct as a Cause of Idiopathic Recurrent Pancreatitis

¹Shyam Sundar, ²Balaji Purushotham, ³Rajkumar Rathinasamy, ⁴Prabu Kathiresan

ABSTRACT

Idiopathic pancreatitis contribute to about 20% of acute and recurrent pancreatitis. Here we present a case of loop-type variant of meandering pancreatitis. A patient with a very rare anomaly of the main pancreatic duct presented with recurrent episodes of pancreatitis.

Keywords: Anomalous pancreatic biliary junction, Idiopathic pancreatitis, Loop type, Meandering pancreatic duct.

How to cite this article: Sundar S, Purushotham B, Rathinasamy R, Kathiresan P. Meandering Pancreatic Duct as a Cause of Idiopathic Recurrent Pancreatitis. *World J Lap Surg* 2018;11(1):48-50.

Source of support: Nil

Conflict of interest: None

INTRODUCTION

Acute pancreatitis is serious illness with fatal outcomes. Some common causes include alcohol consumption, gall stones, autoimmunity, trauma, and several anatomical anomalies,¹ such as anomalous pancreatic biliary junction² and pancreatic divisum.³ Idiopathic pancreatitis includes 20% of cause of pancreatitis and 30% incidence of recurrent pancreatitis. Recurrent pancreatitis is usually associated with pancreatic ductal dilatation.

The main pancreatic duct normally has obtuse angle curve from tail and body of pancreas to major ampulla. Occasionally, the ventral duct in the head of the pancreas has abnormal curvature with localized spiral or hairpin curve. This anomaly is known as meandering pancreatic duct. This type of anomaly can cause ductal hypertension and may be the reason for onset of idiopathic recurrent pancreatitis.

CASE REPORT

A 13-year-old female presented with abdominal pain radiating to the back for 3 days. The pain was acute,

continuous, and not associated with food intake. Patient had similar episode 5 years before where she was diagnosed with spontaneous biliary peritonitis and laparostomy was performed. Since then she has recurrent episodes of pancreatitis for which she had recurrent hospitalization and managed conservatively.

On admission, her serum amylase and serum lipase levels were normal. Aspartate transaminase, alanine transaminase, gamma-glutamyl transferase, total bilirubin, and serum calcium levels were normal. Serum triglycerides and parathormone levels were normal.

Ultrasound of abdomen showed dilated main pancreatic duct. There was no evidence of gallstones or sludge. The 320-slice computed tomography of abdomen revealed a slip of pancreatic tissue anterior to the head measuring $3 \times 1.7 \times 1.2$ cm representing the ventral pancreas. Its duct measuring 3 mm in diameter is seen to open into distal common bile duct. There is reduction in parenchyma with dilatation of the main pancreatic duct which measures 6.5 mm. Replaced right hepatic artery passes along the posterior surface of head of pancreas. Common bile duct and cystic duct shows mild fusiform dilatation. Upper gastrointestinal endoscopy was performed, which showed no abnormality. Magnetic resonance cholangiopancreatogram (MRCP) showed meandering pancreatic duct of loop variety with dilatation of main pancreatic duct (Figs 1 to 3). Patient was put on nil per oral, O₂ support, and nasogastric tube was inserted. Parenteral fluids were given and managed



Fig. 1: Loop variant of main pancreatic duct

¹Fellow, ²Professor and Head, ^{3,4}Assistant Professor

¹⁻⁴Department of Minimal Access Surgery, Madras Medical College, Chennai, Tamil Nadu, India

Corresponding Author: Shyam Sundar, Fellow, Department of Minimal Access Surgery, Madras Medical College, Chennai Tamil Nadu, India, e-mail: shyamsundarsr89@gmail.com

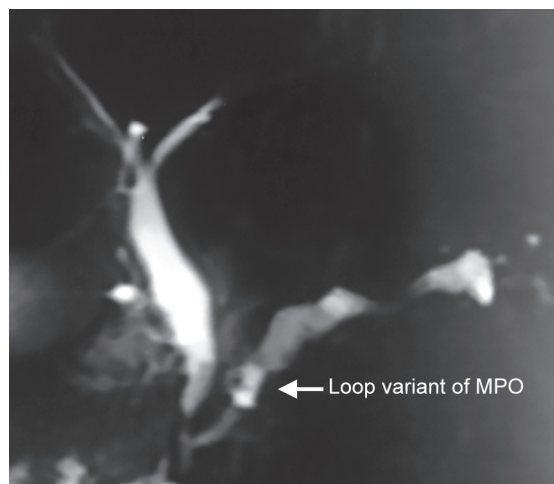


Fig. 2: AR1 loop in MRCP

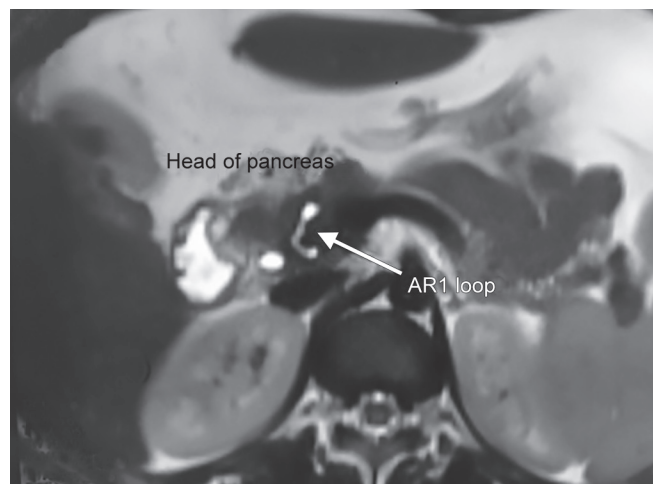


Fig. 3: AR1 loop variant in MMPD

conservatively. Patient symptoms improved clinically and was discharged. Patient is in regular follow-up every 2 months and is symptom-free.

DISCUSSION

Meandering main pancreatic duct (MMPD) is defined as an abnormal curvature of the main pancreatic duct without an abnormal pancreaticobiliary junction. It comprises two anatomical variants: (1) loop type and (2) reverse Z-type.

Figure 4 shows schematic images of MMPD. The thick line indicates the common bile duct, and the thin line indicates the main pancreatic duct. Based on its morphology, MMPD was classified into subtypes in the head of pancreas on MRCP: Normal type (A), examples of loop type (B1-2), and examples of reversed Z-type

(C1-3). Assuming the body-axis as x-axis and horizontal direction as y-axis, MMPD curves in loop and reversed Z-types have two extreme in horizontal direction respectively, while normal type has none. Dorsal pancreatic duct could be observed or not.

Review of the literature shows only one study done in Tokyo University showing the incidence and relevance of MMPD as a cause of recurrent idiopathic pancreatitis against those with similar abnormalities with no symptoms. In India, this is the second case reported, with other one being a reversed Z-type.

According to the Tokyo University study,⁴ the results of univariate analysis revealed a significant positive association of MMPD to the onset of pancreatitis [$p = 0.0002$; odds ratio (OR): 4.01; 95% confidence interval (CI): 1.92–6.11] and recurrent acute pancreatitis (RAP) [$p < 0.0001$;

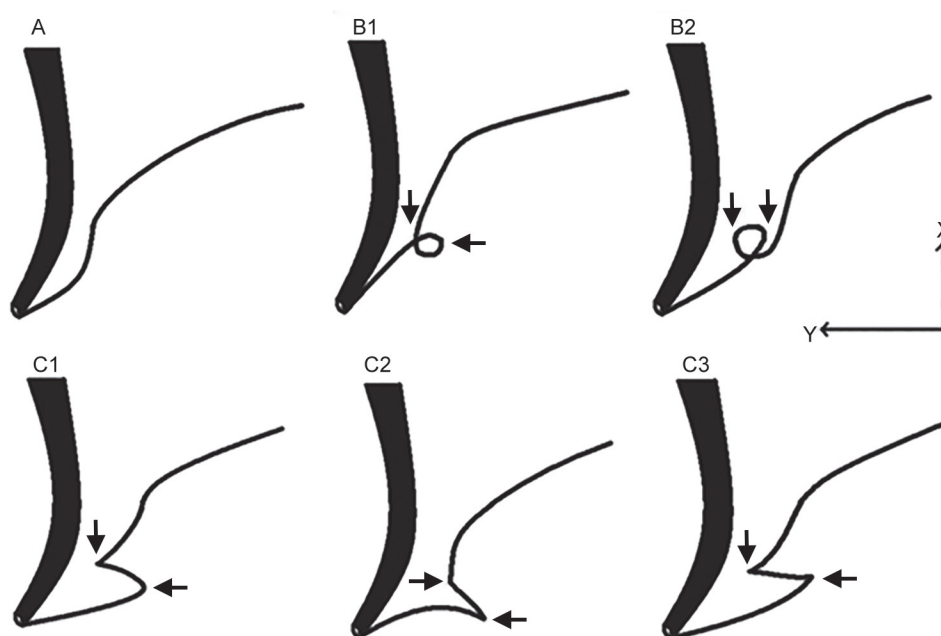


Fig. 4: Types of MMPD

OR: 26.2 (95% CI: 22.2–30.2)]. Positive association of loop/reversed Z-type to the onset of RAP was detected as well [$p = 0.0006/0.0009$; OR: 21.6/18.5 (95% CI: 15.9–27.3/12.9–24.0)].

The etiology of meandering pancreatic duct abnormality has not yet been established. A single case of reverse Z loop reported by Wirsingococele⁵ revealed the mechanical obstruction theory.⁶ In our patient too, we had gross dilatation of main pancreatic duct with pancreatic parenchymal atrophy. But in the study established by Gonio et al,⁷ neither dilatation of main pancreatic duct nor pancreatic parenchymal atrophy was associated with MMPD pancreatitis.

For MMPD, MRCP⁸ is the investigation of choice. Heavily T2-weighted images are useful in picking up the anomaly. It is established that cannulating the main pancreatic duct is difficult owing to the curvature and bends of the duct. Thus, the role of MRCP in the management of MMPD is not well established.⁹

In the Tokyo study, it was found that pancreatitis occurring due to MMPD is less severe compared with those due to other causes and ductal anomaly. But no proper evidence could be established due to the rarity of the anomaly.

Currently, there are no set protocols made for management of pancreatitis due to MMPD and treatment follows as indicated for other causes of pancreatitis as the pathophysiology of the disease process is not well established.

CONCLUSION

Meandering main pancreatic duct is a very rare anomaly and an important cause for recurrent pancreatitis and requires a very high degree of suspicion for diagnosis of the same. It mainly presents in two of its subtypes: (1) Loop variant and (2) reverse Z variant. Owing to the

rarity of the anomaly, proper management protocols had not been set in the literature. Proper management protocols can be made on further reporting in future.

REFERENCES

1. Shanbhogue AK, Fasih N, Surabhi VR, Doherty GP, Shanbhogue DK, Sethi SK. A clinical and radiologic review of uncommon types and causes of pancreatitis. *Radiographics* 2009 Jul-Aug;29(4):1003-1026.
2. Ishii H, Arai K, Fukushima M, Maruoka Y, Hoshino M, Nakamura A, Koike Y, Sakamoto N, Hanada H, Kusano M, et al. Fusion variations of pancreatic ducts in patients with anomalous arrangement of pancreaticobiliary ductal system. *J Hepatobiliary Pancreat Surg* 1998 Feb;5(3):327-332.
3. Cotton PB. Congenital anomaly of pancreas divisum as cause of obstructive pain and pancreatitis. *Gut* 1980 Feb;21(2):105-114.
4. Gono W, Akai H, Hagiwara K, Akahane M, Hayashi N, Maeda E, Yoshikawa T, Kiryu S, Tada M, Uno K, et al. Meandering main pancreatic duct as a relevant factor to the onset of idiopathic recurrent acute pancreatitis. *PLoS One* 2012 May;7(5):e37652.
5. Gupta R, Lakhtakia S, Tandan M, et al. Recurrent acute pancreatitis and Wirsingococele. A case report and review of literature. *J Pancreas*. 2008;9:531–533.
6. Delhaye M, Matos C, Arvanitakis M, Deviere J. Pancreatic ductal system obstruction and acute recurrent pancreatitis. *World J Gastroenterol* 2008 Feb;14(7):1027-1033.
7. Gono W, Akai H, Hagiwara K, Akahane M, Hayashi N, Maeda E, Yoshikawa T, Tada M, Uno K, Ohtsu H, et al. Pancreas divisum as a predisposing factor for chronic and recurrent idiopathic pancreatitis: initial *in vivo* survey. *Gut* 2011 Aug;60(8):1103-1108.
8. Vitellas KM, Keogan MT, Spritzer CE, Nelson RC. MR cholangiopancreatography of bile and pancreatic duct abnormalities with emphasis on the single-shot fast spin-echo technique. *Radiographics* 2000 Jul-Aug;20(4):939-957, quiz 1107-1108, 1112.
9. Carnes ML, Romagnuolo J, Cotton PB. Miss rate of pancreas divisum by magnetic resonance cholangiopancreatography in clinical practice. *Pancreas* 2008 Aug;37(2):151-153.