

# Challenges faced in operating a 3 Kilogram Thyroid Cancer

<sup>1</sup>Roma Pradhan, <sup>2</sup>Pallavi Shinde, <sup>3</sup>Soumya Pattnaik, <sup>4</sup>Siddharth Sathaye, <sup>5</sup>Sashi Raj, <sup>6</sup>Mohammad Nazar  
<sup>7</sup>Sofia Batool, <sup>8</sup>Aradhana Sinha, <sup>9</sup>Tshering D Bhutia

## ABSTRACT

A case of a 60-year-old male who presented to the endocrine surgery outpatient department with complaints of neck swelling for last 6 years with h/o rapid growth for 1½ months, associated with 3 Ds, i.e., dysphagia, dysphonia, and dyspnea. Fine-needle aspiration cytology was reported as suspicious for a follicular neoplasm. On examination, he was found to be having a huge nodular goiter with impending ulceration of overlying skin. Operability and difficult intubation were serious challenges. Patient was taken up for surgery. Intubation was a challenge for the anesthetist. Awake intubation was tried but because of plenty of

tortuous multiple vessels in oral cavity, there was bleeding and the vision was obscured. As informed by our anesthetist, the air bubbles coming from the trachea during patient's breathing was the only guide for her to direct the endotracheal tube. At operation, left carotid was found to be encased, but could be separated with sharp dissection. Left internal jugular vein and left vagus were encased, could not be saved, and hence, sacrificed. Right recurrent laryngeal nerve and right superior and inferior parathyroid were preserved. Thus, a total thyroidectomy could be performed. The specimen weighed 3 kg (Fig. 1). After removal of the 3 kg mass, patient had difficulty in holding his head upright due to postural compensation. Postoperatively, patient had difficulty in swallowing, which was evident by pooling of saliva during laryngoscopy postoperatively; however, right vocal cord was mobile. Literature is sparse about the problem which the patient developed after removal of huge goiter weighing more than 3 kg. This is probably the largest thyroid cancer operated in India.

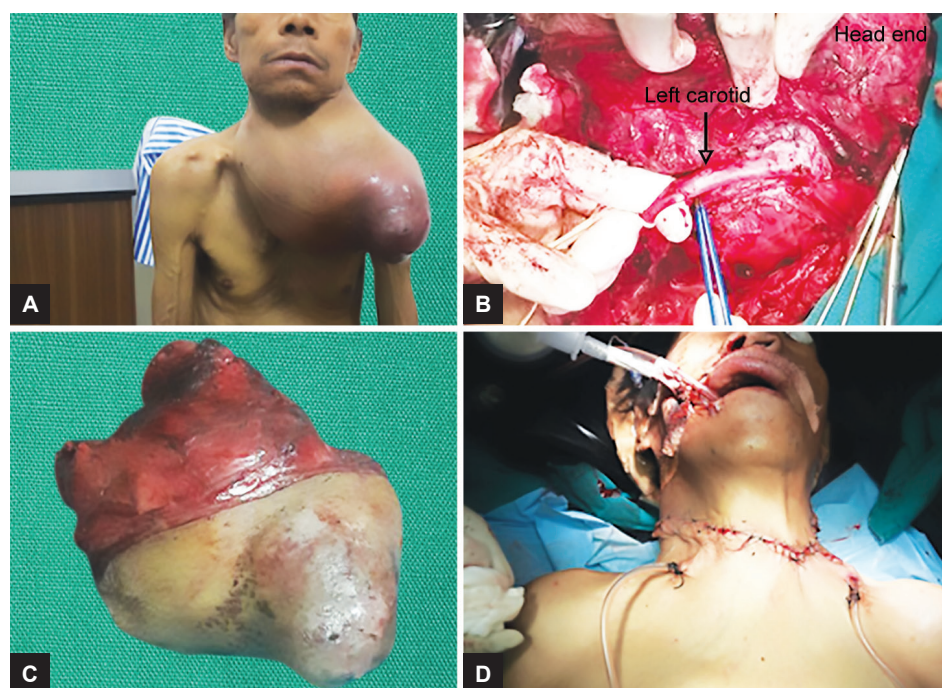
**Keywords:** Complication, Postural drop, Thyroid cancer.

**How to cite this article:** Pradhan R, Shinde P, Pattnaik S, Sathaye S, Raj S, Nazar M, Batool S, Sinha A, Bhutia TD. Challenges faced in operating a 3 Kilogram Thyroid Cancer. *World J Endoc Surg* 2018;10(2):147.

**Source of support:** Nil

**Conflict of interest:** None

<sup>1,2,7,8</sup>Assistant Professor, <sup>3-6</sup>Junior Resident, <sup>9</sup>Senior Resident  
<sup>1</sup>Department of Endocrine Surgery, Dr. Ram Manohar Lohia Institute of Medical Sciences, Lucknow, Uttar Pradesh, India  
<sup>2,7,8</sup>Department of Anaesthesia, Sikkim Manipal Institute of Medical Sciences, Gangtok, Sikkim, India  
<sup>3-6,9</sup>Department of Surgery, Sikkim Manipal Institute of Medical Sciences, Gangtok, Sikkim, India  
**Corresponding Author:** Roma Pradhan, Assistant Professor Department of Endocrine Surgery, Dr. Ram Manohar Lohia Institute of Medical Sciences, Lucknow, Uttar Pradesh, India e-mail: drromapradhan@yahoo.com



**Figs 1A to D:** (A) Preoperative clinical image; (B) intraoperative image; (C) postoperative specimen; (D) postoperative image after surgery