



Proximal Biceps Tendon Congenital Accessory Superior Glenohumeral Ligament and Biceps Tendon fused to Anterior Superior Capsule Under the Coracohumeral Ligament: The Aggeris Fusion

¹Gregory S Motley, ²Claude T Moorman III, ³Brad Guengerich, ⁴Tracy Schuller, ⁵Anna Turbyfill

ABSTRACT

There are multiple congenital differences in the anatomy of the long head biceps tendon origin, course, and sling. Here, we report a case of biceps tendon congenital accessory superior glenohumeral ligament (SGHL) and biceps tendon fused to anterior superior capsule under the coracohumeral ligament without a history of prior shoulder surgery or trauma, "the Aggeris Fusion." The diagnosis of this fusion was possible with "the Ramp Test," originally described by the senior author. "The Ramp Test" was developed to evaluate biceps intra-articular pathology and ultimately diagnose the biceps "Hidden Lesion," described by Walch et al. The reported lesion was found to have a negative (abnormal) Ramp Test, due to the abnormal, congenital fusion. The fusion was released arthroscopically. Postoperatively, the patient progressed successfully. The patient achieved a full range of motion and reports no pain.

Keywords: Arthroscopy, Biceps tendon, Coracohumeral ligament, Hidden lesion, Joint capsule, Proximal biceps tendon, Ramp test, Shoulder, Superior glenohumeral ligament.

Motley GS, Moorman CT III, Guengerich B, Schuller T, Turbyfill A. Proximal Biceps Tendon Congenital Accessory Superior Glenohumeral Ligament and Biceps Tendon fused to Anterior Superior Capsule Under the Coracohumeral Ligament: The Aggeris Fusion. *The Duke Orthop J* 2018;8(1):13-15.

Source of support: Nil

Conflict of interest: None

INTRODUCTION

The following case study introduces a case of biceps tendon congenital accessory SGHL and biceps tendon fused to anterior superior capsule under the coracohumeral ligament, "the Aggeris Fusion."

^{1,2}Attending Surgeon, ³⁻⁵Researcher

^{1,3,4}Southeastern Sports Medicine and Orthopedics, Department of Pardee Hospital, UNC Affiliate, Asheville, North Carolina, USA

²Department of Orthopaedic Surgery, Duke University Medical Center, Durham, North Carolina, USA; Carolinas Medical Center Charlotte, North Carolina, USA

⁵Campbell University, Clinical Research Candidate, Buies Creek North Carolina, USA

Corresponding Author: Anna Turbyfill, Researcher, Campbell University, Clinical Research Candidate, Buies Creek, North Carolina, USA, e-mail: akturbyfill0104@email.campbell.edu

The anatomy of the shoulder, particularly the capsule and the long head biceps tendon, has many known variations.¹ Pouliart et al² described the four main variations of superior capsular structures in a cadaver study. Ide et al³ described variation of the glenohumeral ligament complex, including the Buford complex by cadaver investigation. The study concluded that the Buford complex is a rare variant. Walch et al⁴ described intra-articular pathology, specifically the "Hidden Lesion."

Many factors can contribute to shoulder anatomic variations, which include both surgical and congenital causes. Surgical causes include scarring or altered anatomy from shoulder repair, particularly rotator cuff repair. These procedures are occasionally followed by fusion of the biceps tendon to joint capsule. These types of fusion and scarring typically require a secondary surgery.⁵

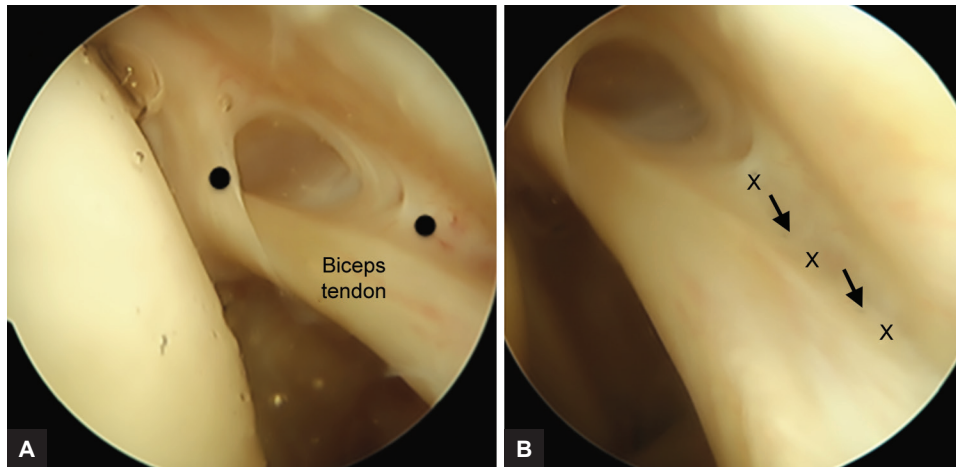
Congenital abnormalities vary greatly and some are thought to contribute to shoulder pathology while others are benign. Congenital abnormalities have been described throughout many studies.

Dierickx et al⁶ described atypical biceps tendon origins taking a "Y" shape. This is established by primary attachment to the rotator cable and secondary attachment medial to the superior glenoid tubercle. This abnormality was not found to contribute to shoulder pathology.⁶

Zhang et al⁷ described abnormal origins of the long head of the biceps tendon, including origins at the anterior edge of the supraspinatus tendon. Due to this placement, the structure may have contributed to symptomatic rotator cuff pathology.

Dierickx et al⁸ described 12 variations of the intra-articular portion of the long head of the biceps tendon. Some of these include fusions with the inferior surface of the capsule. Each of the described variations are thought to be congenital, while only some contribute to shoulder pathology.⁸

Here, we describe the fusion of the proximal biceps tendon to the anterior superior capsule. This abnormality is congenital, as no previous surgery or trauma is present. Additionally, the abnormality is thought to contribute to shoulder pathology.



Figs 1A and B: (A) The arthroscopic picture (A) demonstrates the proximal biceps tendon and the SGHL fused to the joint capsule under the coracohumeral ligament. The accessory SGHL is marked with a black dot. (B) The biceps tendon fusion to the anterior superior capsule is indicated by the row of Xs and arrows

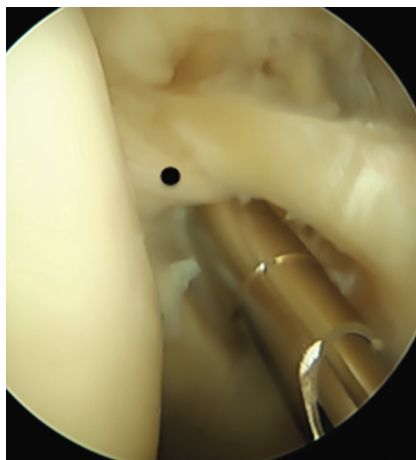


Fig. 2: Arthroscopic release of the congenital lesion was performed and the normal SGHL remains intact with a normal "Ramp Test" now

CASE REPORT

The patient was a 53-year-old female who presented with left anterior shoulder pain. The pain increased with abduction and adduction. The patient had no previous shoulder trauma or surgical procedures. The physical exam showed limited external rotation above shoulder and chest and isolated anterior shoulder pain. There was negative instability on biceps tendon test.

Arthroscopically, it was determined to have a negative "Ramp Test," because the fusion was located at the exit out of shoulder.⁹ Ultimately, the lesion was arthroscopically released as depicted in Figures 1 and 2.

Postoperative procedures included physical therapy to increase strength and range of motion. The patient progressed successfully and made a full recovery. The patient gained full range of motion, reported no pain, and returned to work.

DISCUSSION

It is common for patients to experience posttrauma fusion of the biceps tendon to joint capsule. This requires arthroscopic repair and employment of the Ramp Test in order to determine the health of the intra-articular subluxation of the long head of the biceps tendon.⁹

Various congenital formations of the bicep tendon origin have been well documented. The variations are outlined and described in detail.

To the best of our knowledge, there has been no prior description of the SGHL and biceps tendon being fused to the anterior superior capsule, as reported here. Therefore, we suggest the "Aggeris Fusion" as a novel discovery.

REFERENCES

1. Rockwood, C.; Frederick, M.; Wirth, M.; Lippitt, S.; Fehring, E.; Sperling, J. The shoulder. 4th ed. Philadelphia (PA): Saunders; 2009.
2. Pouliart N, Somers K, Eid S, Gagey O. Variations in the superior capsuloligamentous complex and description of a new ligament. *J Shoulder Elbow Surg* 2007 Nov-Dec;16(6):821-836.
3. Ide J, Maeda S, Takagi K. Normal variations of the glenohumeral ligament complex: An anatomic study for arthroscopic bankart repair. *Arthroscopy* 2004 Feb;20(2): 164-168.
4. Walch G, Nove-Josserand L, Levigne C, Renaud E. Tears of the supraspinatus tendon associated with "hidden" lesions of the rotator interval. *J Shoulder Elbow Surg* 1994 Nov;3(6): 353-360.
5. David, TS.; Andrews, JR. Arthroscopic techniques of the shoulder. New Jersey: SLACK Incorporated; 2009.
6. Dierickx C, Ceccarelli E, Conti M, Vanlommel J, Castagna A. Regarding "aberrant origin of the long head of the biceps: a case series". *J Shoulder Elbow Surg* 2012 Oct;21(12): e20-e22.

7. Zhang AL, Gates CH, Link TM, Ma CB. Abnormal origins of the long head of the biceps tendon can lead to rotator cuff pathology: a report of two cases. *Skeletal Radiol* 2014 Nov;43(11):1621-1626.
8. Dierickx C, Ceccarelli E, Conti M, Vanlommel J, Castagna A. Variations of the intra-articular portion of the long head of the biceps tendon: a classification of embryologically explained variations. *J Shoulder Elbow Surg* 2009 Jul-Aug;18(4):556-565.
9. Motley GS, Osbahr DC, Holovacs TF, Speer KP. An arthroscopic technique for confirming intra-articular subluxation of the long head of the biceps tendon: the ramp test. *Arthroscopy* 2002 Nov-Dec;18(9):E46.