



A Review of Radiographic Measurements to assess the Patellofemoral Joint

¹Christopher K Ewing, ²Nathan L Grimm

ABSTRACT

Radiographic anatomic findings have been defined to help surgeons and physicians understand both normal and pathologic anatomy. These findings have been defined in terms of know angles and lines drawn on radiographs. Through understanding the normal geometry, bony alignment, and range of morphology the provider can more easily identify aberrancies that can potentially be corrected to address a patient's symptoms. One such pathology, patella alta, has had many iterations of radiographic measures to help in diagnosis and treatment. It is important for the surgeon to understand the history of the many measures and the utility of each in determining which measure should be used.

Keywords: Patella, Patella alta, Patellofemoral.

Ewing CK, Grimm NL. A Review of Radiographic Measurements to assess the Patellofemoral Joint. *The Duke Orthop J* 2018;8(1):1-6.

Source of support: Nil

Conflict of interest: None

INTRODUCTION

The use of radiographic lines and angles in orthopedics has been valuable for the evaluation of pathology. These anatomic guides help physicians with their clinical decision-making. Many pathological conditions, such as recurrent patella subluxation, dislocation,¹⁻⁶ and chondromalacia,⁷⁻⁹ to name a few, have been correlated to such lines and angles.

Many have studied the patellofemoral joint and its utility in assessing for pathology, guiding treatment, and predicting outcome.¹⁰⁻¹² Patellar dysfunction is commonly assessed for utilizing the height of the patella, patellar morphology, alignment of anatomical landmarks associated with the patellofemoral joint, and trochlear dysplasia. Some believe that the current definition of patella alta is insufficient and unclear.^{13,14} In reviewing the literature back to the early 20th century, we found

the first radiographic definition of patella alta given by Jansen.¹⁵ He defined patella alta as a condition where the lower pole of the patella is no longer articulating with the trochlea. Boon-Itt¹⁶ found this to be true in his study of the "normal position of the patella." He subsequently defined a "patellar index" for measuring patella alta using this definition, with values >1.0 indicating patella alta.

Blumensaat described a more practical technique that compared a line parallel to the ventral border of the intercondylar fossa that extended out past the patella. He defined normal as the apex of the patella intersecting this line. Since Blumensaat's method, multiple techniques have been described in the literatures that are used to evaluate the height of the patella. Up until 2006, subsequent methods utilized ratios consisting of measurements outside of the patella-trochlear joint.¹⁷⁻²² Using an index directly comparing the patella's position in relation to the trochlea was revived by Biedert and Albrecht,²³ who described the "Patellar Trochlear Index" using magnetic resonance imaging (MRI). He defined a normal knee as having a 31.7% overlap between the distal portion of the patellar articular cartilage and the trochlea, remarkably close to the 25% estimated by Boon-Itt 76 years prior.²³ He defined abnormal as overlap <11%. In contrast, Boon-Itt defined patella alta as no overlap.

Perhaps the most popular of the patellar indices to date is Insall-Salvati due to its convenient normal ratio of one and lack of variability between 20 and 70° of flexion. However, each measurement technique has its own set of challenges and utility. In an article published by Seil et al²⁴ assessing the reliability between patellar height ratios, he determined that patella height classification and patella alta relies heavily on the ratio used. These differences have been thought to be due to variations in anatomical landmarks between patients. They published variability in 68% of patients when classified as alta, baja, or norma for Insall-Salvati, Modified Insall-Salvati, and Caton-Deschamp indices.

The goal of this study is to review the radiographic measurements used to separate normal from abnormal patella and patellofemoral anatomy.

PATELLA ALTA

In 1899, Schulthess²⁵ described patients with patella alta and spastic muscles, noting a protuberance of the femur

^{1,2}Resident Physician

¹US Navy Hospital Camp Pendleton, Oceanside, California, USA

²Department of Orthopaedics, Duke Sports Medicine Center Duke University Medical Center, Durham, North Carolina, USA

Corresponding Author: Nathan L Grimm, Resident Physician Department of Orthopaedics, Duke Sports Medicine Center Duke University Medical Center, Durham, North Carolina, USA e-mail: Nathan.grimm@duke.edu

during physical examination of the knee flexed at 90°. Normally with this degree of flexion the patella descends distally into the trochlear groove forming a rounded appearance of the knee. It was during this same time that the X-ray image was first discovered by Wilhelm Röntgen. Boon-Itt¹⁶ performed 31 years later the first measurements characterizing the position of the patella relative to the trochlea using X-ray. In the article “Normal Position of the Patella,” he describes the “patellar index,” noting that in the normal knee overlap of the patellar articular surface and trochlea is 25%. Biedert and Albrecht²³ described a similar method using MRI 76 years later showing 31.7% overlap of the patellar articular cartilage and trochlear cartilage in the normal knee, amazingly close to that described by Boon-Itt using plain film radiography.

Since the time of Boon-Itt, many have coined indices that are used to describe patella height.

The Patellar Index

Boon-Itt¹⁶ performed radiographic analysis of the motion of the knee during flexion-extension by means of a complex mathematical formula. Although his analysis was complex, his conclusion and methods for assessing the position of the patella were simple. With the knee in 180° of extension he defined an index alpha/beta, where alpha is the distance from the lower edge of the patellar articular surface to the articular surface of the femur, drawn parallel to midshaft femur, and beta is the articular length of the patella.

Blumensaat's Line

In 1938, Dr Blumensaat correlated a line formed by the ventral border of the intercondylar fossa, that with the knee in 30° of flexion would intersect the apex of the patella in the majority of normal knees (Fig. 1). He

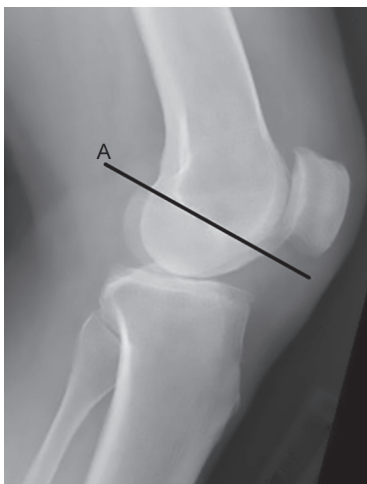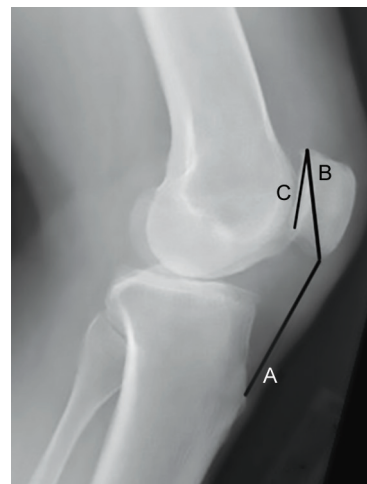


Fig. 1: Blumensaat's line, which is a line drawn through the roof of the intercondylar notch extending anteriorly toward the patella

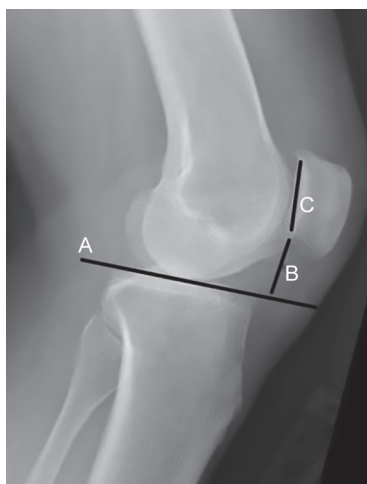defined patella alta as any measurement where the apex of the patella lies above this line. Andersen²⁶ studied patients with recurrent dislocations and found that in 207 out of 286 the apex of the patella was 5 mm proximal to Blumensaat's line, thus showing this to be predictive of patellar instability. However, in a study of 100 patients with normal knee, Brattstrom²⁷ determined that Blumensaat's line varied by 27 to 60°. Therefore, although a good clinical indicator of patella alta, it is not very specific. The following recommendations were made based on this study: For every 10° increase or reduction in angulation of Blumensaat's line, a 10 mm correction is needed. Brattstrom also emphasized the importance of maintaining relaxed quadriceps at the moment of X-ray capture.

Insall-Salvati Index

Insall et al¹⁷ believed Boon-Itt's method was too complex and Blumensaat's method was unreliable due to its inherent variation in angulation. They sought to define a “simple, practical, and reliable” method for measuring patella alta that varied little with joint size or flexion at the knee. This index compares the ratio of the patellar tendon length (LT) to the diagonal length of the bony patella (LP) (Fig. 2). They reported their method to be reliable within 20 to 70° of flexion. One reason being that >20° is theoretically needed to keep the tendon under constant tension and reduce variation in measurements. Additionally, due to the anatomic landmarks, and lack of patellar tendon insertion definition, use of this index in children has not been recommended.²⁸ Furthermore, this method may be limited due to variability of patellar morphology, especially in individuals with long distal nonarticulating facets. Lateral images with poorly defined patellar tendons may also limit the utility of this technique.



Figs 2A to C: The Insall-Salvati ratio of the patellar LT (A), over the patellar bony length (B), with the “modified” version using the patellar articular length (C)

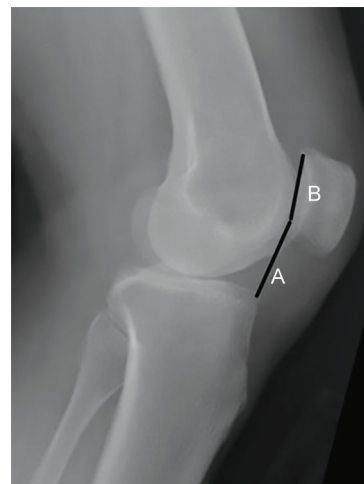


Figs 3A to C: Blackburne–Peel ratio defined by a line drawn parallel to the tibial plateau (A), and the ratio of patellar articular cartilage (C), to the distance of the lower pole of the patella to the tibial plateau line (B)

Normal patella height was defined as a LT:LP ratio of 1.02 ± 0.13 . Patella baja and patella alta were defined as <0.8 and >1.2 respectively. A correction of 0.13 and 0.10 are needed when using this technique on computed tomography (CT) and MRI respectively.²⁹ According to a recent meta-analysis, interobserver reliability for this method was excellent and ranged from 0.78 to 0.86.^{24,30,31} Intraobserver reliability is also excellent and has been reported as high as 0.83.³¹

Blackburne–Peel

Blackburne and Peel¹⁸ described a technique using the ratio of the articular cartilage of the patella to the height of the lower pole of the articular cartilage above the tibial plateau (Fig. 3). In the same article, it was hypothesized that this technique removes the variation in tibial tubercle to anterior tibial plateau distance. A noted requisite to these measurements was for the knee to be flexed beyond 30°. Normal values were reported between the range of 0.54 to 1.06 and patella alta defined as a A/B ratio >1.0 . (95% lay within this range). As with Insall–Salvati index, Blackburne–Peel technique is also not recommended for use in children because the index varies with the slope of the tibial plateau³² and is also affected by the degree of skeletal maturation of the proximal tibial epiphysis.³³ According to Lee et al,²⁹ no correction factor is needed when using this index on MRI, but a 0.09 correction factor is recommended with CT. Chareancholvanich and Narkbunnam³⁴ demonstrated an interobserver reliability of 0.708. Interobserver reliability for this method according to a recent meta-analysis ranged from 0.73 to 0.86; the high-end value determined using Spearman's rank correlation coefficient.^{24,30,31} Intraobserver reliability was found by one study to be 0.75.³¹



Figs 4A and B: Caton–Deschamps ratio defined by the height of the anterior tibial plateau to the inferior margin of the patellar articular surface (A), to the length of the patellar articular surface (B)

Caton–Deschamps

Caton et al³² described a method for assessing patella height using a ratio of distance from the anterior tibial plateau to the inferior portion of the articular surface of the patella to the distance of the bony articular surface of the patella (Fig. 4). Similar to the Insall–Salvati technique, a normal index was defined as 1, with patella alta >1.2 . According to Aparicio et al,²⁸ CD does not vary based on skeletal maturation and is a reliable method for measuring patellar height in children. Thevenin-Lemoine et al³⁵ determined this to be true in children >12 years old, but emphasizes that children <12 should be age-matched to adjust for variation in normal values. Interobserver reliability for this method was found to range from 0.77 to 0.92; the high-end value is determined using Spearman's rank correlation coefficient.^{24,34} Intraobserver reliability was 0.78 according to one study.³¹ It should also be noted that this study investigated chronological age not skeletal age.

In a small study investigating patellar height in adolescent patients with anterior tibial tubercle apophysitis, 58% had a high patella using 1.2 as the threshold (mean 1.22).²⁸ Variability was observed in malaligned radiographs. The author emphasizes the importance of a true lateral with proper alignment of the condyles.

de Carvalho's Index

de Carvalho et al²² published a patellar height index very similar to Caton–Deschamps method, using the ratio of the shortest distance from the tibial plateau to the length of the articular surface of the patella. Although very similar, Caton–Deschamps ratio compared the anterior–superior aspect of the tibial plateau to the articular surface of the patella, which in many cases is equivalent to De Carvalho's index.

Koshino Index

Koshino and Sugimoto²¹ studied 59 normal knees in 36 children aged 3 to 18 years (avg 10.6). The author defined a normal range of 0.9 to 1.3 with 95% confidence interval; only 2 patients in their series of normal knees were out of this range. However, Thevenin-Lemoine et al³⁵ stated that the Koshino index is “a rather complex geometric construct” with variability in flexion of the knee; no clarification or data was found to support this. It was also noted by the author that this technique does not vary greatly between 30 and 90° flexion. However, Thevenin-Lemoine when comparing Insall–Salvati and Blumensaat’s line on this same series of patients, it was estimated that 66.7 and 45.7% of patients had patella alta respectively.

Modified Insall–Salvati (MIS) Index

Grelsamer and Meadows²⁰ sought to define a patellar height measurement technique that is not affected by an abnormally long distal patella like the Insall–Salvati method. This “modified” technique uses a ratio consisting of the distance from the patellar tendon origin to the inferior aspect of the articular surface of the patella and the distance of the articular surface of the patella (Fig. 2). The author used Caton–Deschamps index as a reference ratio to identify subjects with patella alta in a cohort of 300. Totally, 36 cases of patella alta were identified. Modified Insall–Salvati and Insall–Salvati measurements were performed on these 36 cases; 50% of these cases were identified by Insall–Salvati technique and 78% were identified by the MIS. Only 28% of cases were identified by both techniques. The normal mean MIS was 1.5, with 97% of patients in the control group, with a ratio of <2.

Patellar Trochlear Index (PTI)

Biedert and Albrecht²³ evaluated MRIs of 66 patients with no patellofemoral pathology. Due to a lack of reliability and increased variability in identifying patella alta among the indices available, Biedert and Albrecht²³ emphasized the importance of determining patellar height based on the ratio of the articular cartilage of the patella and trochlear cartilage. Boon-Itt¹⁶ provided the same ratio using plain film radiography 76 years earlier. Biedert states, “the only ratio that is accurate for the determination of patellar height and for all patients who are present with a clinical disorder and some complaint about patellofemoral pain is the ratio between the articular cartilage of the patella and trochlear cartilage.” Similar statements were emphasized by Seil et al,²⁴ Jansen,¹⁵ and Boon-Itt,¹⁶ and confirmed by Monk et al³⁶ to have the strongest relationship to patients with subluxation. In the same study by Monk et al,³⁶ patients with

patella subluxation tended to sublux if <30% engagement occurred in full extension.

For assessing the cartilage, Biedert et al method used the slice with the thickest articular cartilage and longest length of the patella. Magnetic resonance images were taken at 180° extension and 15° external rotation. Their mean PTI was 31.7%, similar to the 25% identified by Boon-Itt on plain film radiography. Biedert defined patella alta and patella infera as <12.5 and >50% overlap of the patella articular surface and trochlea respectively. Barnett et al³¹ determined the interrater reliability to be 0.78 and intrarater reliability to be 0.8.

PATELLOTROCHLEAR MORPHOLOGY

Wiberg Classification

Wiberg³⁷ described a qualitative method of classifying the patella based on the size relationship between the medial and lateral facets. Through his studies he identified three types of patella. He defined Type I patella as having an articular ridge located approximately in the center with equal medial and lateral facet lengths. Type II patella have a ridge located more medially with a small medial facet relative to the lateral facet. Wiberg defined Type III patella as having a lateral facet located so far medial that it resulted in a small medial facet with a very steep degree of angulation medially.

Sulcus Angle

Brattstroem³⁸ first studied the “sulcus” angle formed by the medial and lateral femoral condyles and the intercondylar surface (Fig. 5). In this study 100 normal female and 100 male X-rays of the knee were analyzed. Normal ranged from 141 to 143°. Right leg and left leg subluxation respectively ranged from 152.52 ± 1.67 and 155.22 ± 2.14 in females, and 154.24 ± 2.07 and 151.06 ± 1.50 in males.³⁸

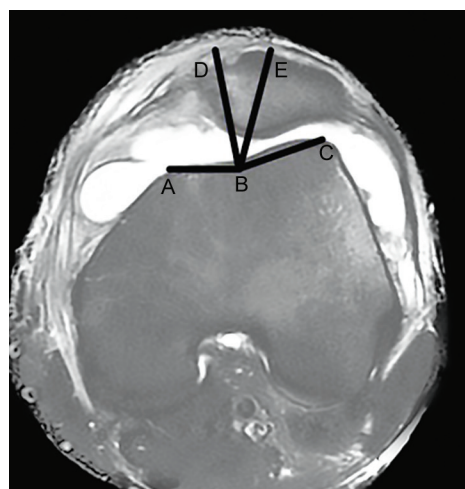


Fig. 5: Sulcus angle ($\angle ABC$) and congruence angle ($\angle DBE$) as measured on MRI

Twenty years later, Aglietti et al¹¹ investigated the sulcus angle, congruency angle, Insall–Salvati, Q-angle, and BP in patients with no history of pathology, history of chondromalacia, and a history of recurrent subluxation. Patients with no pathology had a normal sulcus angle of 137°. In patients with chondromalacia, the average sulcus angle was 139° with zero patients having a sulcus angle value above the 96th percent confidence interval of normal. However, in patients with recurrent subluxation, the sulcus angle and the congruency angle were the most predictive. Out of all variables evaluated, 70% of these patients having a sulcus angle above the 96th percent confidence interval.

The ease at which the sulcus angle measurement can be made makes this an attractive technique to perform in clinic, as was noted by Davies et al.³⁹ However, inter-rater reliability has been shown to be variable depending on the population studied, questioning the utility of the measurement.^{39,40}

Congruency Angle

Merchant et al⁴¹ were the first to describe a measurement relating the patella to the intercondylar sulcus. One-hundred knee images were obtained with the patient supine and knees flexed to 45° (Merchant view). A central X-ray beam was inclined downward at 30° from the horizontal to hit the film cassette at a right angle (30° beam to femur angle). No significant variation was found with beam-to-femur angles of 15 to 75° and knee flexion from 30 to 90°. ^{42,43}

The author notes that significant subluxation is obvious, but for more minor changes this test is useful in determining the degree of subluxation. To obtain the congruency angle, the sulcus angle is first measured and a line bisecting this angle is drawn beginning at the sulcus apex. A second line is drawn from the sulcus apex to the articular ridge of the patella (Fig. 5). An articular ridge lateral to the bisecting line is given a positive value and if medial it is given a negative value. Abnormal was defined as +23° lateral, “well beyond the 95th percentile.”

Aglietti et al,¹¹ as discussed above, investigated the congruency angle in patients with no history of pathology, a history of chondromalacia, and a history of recurrent subluxation. Normal congruency angle was –8°. Patients with chondromalacia had a congruency also averaging –2° with only 17% of the group having angles greater than the 96th confidence interval. Similar to the sulcus angle, 60% of patients with a history of recurrent subluxation had a congruency angle above the 96th percent confidence interval of normal.⁴⁰

A recent study showed the interrater reliability to be low for the congruency angle with 0.8 to 10.4° variance between measurers.⁴⁰

Lateral Patellofemoral Angle (Laurin’s Angle)

Laurin et al⁴⁴ investigated the tilt of the patella by investigating the angle formed by the intersection of a line parallel to the lateral facet and a line drawn across the lateral and medial femoral condylar ridges. Normally, the intersection of these lines forms an angle laterally. The author found that in patients with recurrent subluxation these lines were parallel in 24/30 knees and medial in 6/30. In contrast, in normal knees, the angle opened laterally in 97/100 patients and were parallel in 3/100. As such, this method of assessing patella lay is a quantitative method for assessing the degree of patellar subluxation and risk of recurrence.

CONCLUSION

Patellar pain and instability can be caused by several anatomic anomalies. These can occur in isolation (e.g., patella alta) or in concert with other anomalies (e.g., patella alta and trochlear dysplasia). Several studies have shown that anomalous patellar height alters normal joint reaction forces and can lead to patellofemoral instability.^{42,43} Patellar instability can be determined both clinically, through thorough physical examination findings, as well as through imaging (i.e., radiographs, MRI, or CT). As this review points out, there are several different methods for diagnosing variations in anatomy, such as patella alta and patellofemoral changes, such as trochlear morphology. As we have showed, there are several advantages and disadvantages to each measurement with some data to support the reliability of certain measurements, such as the Insall-Salvati ratio over others.³⁴ As the practicing orthopedic surgeon determines treatment options for the patient with patellar instability, it is important that he/she has a thorough understanding of the diagnostic measurements used to evaluate these patients, the pearls and pitfalls of the individual measurements, and when and how to use them.

REFERENCES

1. Fox TA. Dysplasia of the quadriceps mechanism: hypoplasia of the vastus medialis muscle as related to the hypermobile patella syndrome. *Surg Clin North Am* 1975 Feb;55(1): 199-226.
2. Insall J, Goldberg V, Salvati E. Recurrent dislocation and the high-riding patella. *Clin Orthop Relat Res* 1972 Oct;88: 67-69.
3. Jacobsen K, Bertheussen K. The vertical location of the patella: fundamental views on the concept patella alta, using a normal sample. *Acta Orthop Scand* 1974;45(1-4):436-445.
4. Macnab I. Recurrent dislocation of the patella. *J Bone Joint Surg Am* 1952 Oct;34A(4):957-967, passim.
5. O’Donoghue DH. The prevention and treatment of injuries to athletes. *J Okla State Med Assoc* 1956 Aug;49(8):302-306, passim.

6. Crosby EB, Insall J. Recurrent dislocation of the patella. Relation of treatment to osteoarthritis. *J Bone Joint Surg Am* 1976 Jan;58(1):9-13.
7. Insall J, Falvo KA, Wise DW. Chondromalacia Patellae. A prospective study. *J Bone Joint Surg Am* 1976 Jan;58(1):1-8.
8. Dandy DJ, Poirier H. Chondromalacia and the unstable patella. *Acta Orthop Scand* 1975;46(4):695-699.
9. Devas M, Golski A. Treatment of chondromalacia patellae by transposition of the tibial tubercle. *Br Med J* 1973 Mar;1(5853):589-591.
10. Laurin CA, Dussault R, Levesque HP. The tangential x-ray investigation of the patellofemoral joint: x-ray technique, diagnostic criteria and their interpretation. *Clin Orthop Relat Res* 1979 Oct;144:16-26.
11. Aglietti P, Insall JN, Cerulli G. Patellar pain and incongruence. I: measurements of incongruence. *Clin Orthop Relat Res* 1983 Jun;176:217-224.
12. Zhang GB. The tangential X-ray investigation of normal patellofemoral joint. *Zhonghua Yi Xue Za Zhi* 1993 Oct;73(10):596-598, 637.
13. Karadimas JE, Piscopakis N, Syrmalis L. Patella alta and chondromalacia. *Int Orthop* 1981;5(4):247-249.
14. Leung YF, Wai YL, Leung YC. Patella alta in southern China. A new method of measurement. *Int Orthop* 1996;20(5):305-310.
15. Jansen M. Genu Impressum und Patella alta und ihr Verhalten zu bekannten Erscheinungen, wie Fetteinklemmungen, Knorpelschaden und Patellarluxation. *Ztschr Orthop Chir* 1929;52:314-331.
16. Boon-Itt SB. Normal position of the patella. *Am J Roentgenol* 1930;24:289-394.
17. Insall J, Salvati E. Patella position in the normal knee joint. *Radiology* 1971 Oct;101(1):101-104.
18. Blackburne JS, Peel TE. A new method of measuring patellar height. *J Bone Joint Surg Br* 1977 May;59(2):241-242.
19. Caton J. Method of measuring the height of the patella. *Acta Orthop Belg* 1989;55(3):385-386.
20. Grelsamer RP, Meadows S. The modified Insall-Salvati ratio for assessment of patellar height. *Clin Orthop Relat Res* 1992 Sep;282:170-176.
21. Koshino T, Sugimoto K. New measurement of patellar height in the knees of children using the epiphyseal line midpoint. *J Pediatr Orthop* 1989 Mar-Apr;9(2):216-218.
22. de Carvalho A, Holst Andersen A, Topp S, Jurik AG. A method for assessing the height of the patella. *Int Orthop* 1985 Nov;9(3):195-197.
23. Biedert RM, Albrecht S. The patellotrochlear index: a new index for assessing patellar height. *Knee Surg Sports Traumatol Arthrosc* 2006 Aug;14(8):707-712.
24. Seil R, Muller B, Georg T, Kohn D, Rupp S. Reliability and interobserver variability in radiological patellar height ratios. *Knee Surg Sports Traumatol Arthrosc* 2000 Feb;8(4):231-236.
25. Schulthess W. Zur Pathologie und Therapie der Spastischen Gliederstarre. Zur operativen Behandlung der Skoliose 1899;6:1-13.
26. Andersen PT. Treatment of recurrent dislocation of the patella by the method of McCarroll and Schwartzmann. *Acta Chir Scand* 1959;117:252-257.
27. Brattstrom H. Patella alta in non-dislocating knee joints. *Acta Orthop Scand* 1970;41(5):578-588.
28. Aparicio G, Abril JC, Albinana J, Rodriguez-Salvanes F. Patellar height ratios in children: an interobserver study of three methods. *J Pediatr Orthop B* 1999 Jan;8(1):29-32.
29. Lee PP, Chalian M, Carrino JA, Eng J, Chhabra A. Multimodality correlations of patellar height measurement on X-ray, CT, and MRI. *Skeletal Radiol* 2012 Sep;41(10):1309-1314.
30. Smith TO, Davies L, Toms AP, Hing CB, Donell ST. The reliability and validity of radiological assessment for patellar instability. A systematic review and meta-analysis. *Skeletal Radiol* 2011 Apr;40(4):399-414.
31. Barnett AJ, Prentice M, Mandalia V, Wakeley CJ, Eldridge JD. Patellar height measurement in trochlear dysplasia. *Knee Surg Sports Traumatol Arthrosc* 2009 Dec;17(12):1412-1415.
32. Caton J, Deschamps G, Chambat P, Lerat JL, Dejour H. Patella infera. Apropos of 128 cases. *Rev Chir Orthop Reparatrice Appar Mot* 1982 Feb;68(5):317-325.
33. Aparicio G, Abril JC, Calvo E, Alvarez L. Radiologic study of patellar height in Osgood-Schlatter disease. *J Pediatr Orthop* 1997 Jan-Feb;17(1):63-66.
34. Chareancholvanich K, Narkbunnam R. Novel method of measuring patellar height ratio using a distal femoral reference point. *Int Orthop* 2012 Apr;36(4):749-753.
35. Thevenin-Lemoine C, Ferrand M, Courvoisier A, Damsin JP, Ducou le Pointe H, Vialle R. Is the Caton-Deschamps index a valuable ratio to investigate patellar height in children? *J Bone Joint Surg Am* 2011 Apr;93(8):e35.
36. Monk AP, Doll HA, Gibbons CL, Ostlere S, Beard DJ, Gill HS, Murray DW. The patho-anatomy of patellofemoral subluxation. *J Bone Joint Surg Br* 2011 Oct;93(10):1341-1347.
37. Wiberg G. Roentgenographic and anatomic studies on the femoropatellar joint, with special reference to chondromalacia patellae. *Acta Orthop Scand* 1941;12:319-410.
38. Brattstroem H. Shape of the intercondylar groove normally and in recurrent dislocation of patella. A clinical and x-ray-anatomical investigation. *Acta Orthop Scand Suppl* 1964;68(Suppl 68):61-148.
39. Davies AP, Costa ML, Shepstone L, Glasgow MM, Donell S. The sulcus angle and malalignment of the extensor mechanism of the knee. *J Bone Joint Surg Br* 2000 Nov;82(8):1162-1166.
40. Smith TO, Cogan A, Patel S, Shakokani M, Toms AP, Donell ST. The intra- and inter-rater reliability of X-ray radiological measurements for patellar instability. *Knee* 2013 Mar;20(2):133-138.
41. Merchant AC, Mercer PL, Jacobsen RH, Cool CR. Roentgenographic analysis of patellofemoral congruence. *J Bone Joint Surg Am* 1974 Oct;56(7):1391-1396.
42. Caton JH, Dejour D. Tibial tubercle osteotomy in patellofemoral instability and in patellar height abnormality. *Int Orthop* 2010 Feb;34(2):305-309.
43. Post WR. Anterior knee pain: diagnosis and treatment. *J Am Acad Orthop Surg* 2005 Dec;13(8):534-543.
44. Laurin CA, Lévesque HP, Dussault R, Labelle H, Peides JP. The abnormal lateral patellofemoral angle: a diagnostic roentgenographic sign of recurrent patellar subluxation. *J Bone Joint Surg Am* 1978 Jan;60(1):55-60.