

CASE REPORT

Poncet's Disease in Tubercular Cervical Lymphadenitis

¹Muzamil Latief, ²Muzamil Nazir, ³Farhat Abbas

ABSTRACT

Introduction: Poncet's disease (PD) is a type of reactive arthritis that accompanies tuberculosis (TB) infection. The joint involvement varies both in number and in severity of involvement. Treatment usually involves anti-inflammatory drugs and antituberculosis treatment (ATT).

Case report: We report a female patient who presented with fever with joint swelling and pain, who, on further evaluation, turned out to be harboring tubercular cervical lymphadenitis as confirmed by histopathology of lymph node and tuberculin skin test. Her joint X-rays, joint aspirate, and negative serological markers established diagnosis of PD. She was treated with ATT and nonsteroidal anti-inflammatory drugs (NSAIDs). Patient responded to this treatment and joint signs and symptoms subsided in 3 weeks after institution of treatment. She went on to complete ATT and is doing well on follow-up.

Conclusion: Diseases like PD, though being rare entities, still have very much clinical importance given the possibility of misdiagnosis and wrong treatment which otherwise is very much treatable with ATT and NSAIDs. Hence, clinical suspicion is very important in this disease state.

Keywords: Lymphadenitis, Poncet's disease, Tuberculosis.

How to cite this article: Latief M, Nazir M, Abbas F. Poncet's Disease in Tubercular Cervical Lymphadenitis. *J Postgrad Med Edu Res* 2018;52(3):150-151.

Source of support: Nil

Conflict of interest: None

INTRODUCTION

Tuberculosis is a disease with a potential to almost involve any organ of the human body. It continues to take a toll in many parts of the world with significant disease burden in African countries and Indian subcontinent.¹ Some organs are involved by direct infection of an organ and some manifestations are because of immunologic aspect of the

disease that includes tubercular rheumatism (also called PD).² Poncet's disease presents with active pulmonary or extrapulmonary TB. Joint involvement in PD has a wide spectrum, as it can appear as a part of constellation of tubercular disease and rarely can be first presentation of TB and precedes other signs and symptoms. It is a reactive arthritis associated with active TB. Synovial fluid has no evidence of mycobacterium in the affected joints and bones with no evidence of any other cause for the arthritis.³ Both small and large joint involvement can occur. The pain and swelling can range in severity from minimal to severely limiting the joint movement and hence, incapacitating a patient. The joint involvement in PD can mimic polyarthritis due to other rheumatologic conditions and so a false diagnosis can be made and therefore, any immunosuppression subsequently can be catastrophic.⁴ Given this background and a possibility of missing this diagnosis, we wish to present a case we treated at our hospital, a case of PD in tubercular cervical lymphadenitis.

CASE REPORT

A 38-year-old lady presented to our hospital with complaints of low-grade fever for last 2 months and joint swelling and pain in multiple joints including bilateral wrists and shoulder and knees for last 2 weeks. She had received some antipyretic and analgesic medications intermittently with little relief in symptoms. Patient also had lost 5 kg weight over these 2 months. She denies any hemoptysis and any other comorbidity. On examination, the patient was hemodynamically stable except for tachycardia. She was poor built with pallor and palpable cervical lymphadenopathy on right side with largest lymph node sized 1.5 cm. Painful swollen joints included bilateral wrists, elbows, and knees, and movements at these joints were restricted because of pain. Among involved joints, most inflamed was the right knee. Other systemic examination was unremarkable. Investigations revealed mild neutrophilic leukocytosis and anemia (hemoglobin 9.5 gm/dL), normal liver and renal functions. X-ray chest, electrocardiogram, and X-rays of involved joints were normal. Joint aspirate from right knee revealed white blood cells 8000/mm³ and negative for gram stain, acid-fast bacilli (AFB) stain, and crystals. Rheumatoid factor was negative, so was anticyclic citrullinated peptide and antistreptolysin O titers. Tuberculin skin test was positive (>20 mm). Human immunodeficiency virus serology was negative as was sputum AFB stain. Cervical lymph node biopsy was done

¹Resident, ^{2,3}Postgraduate Resident

¹Department of Nephrology, Gandhi Medical College & Hospital Secunderabad, Telangana, India

²Department of Community Medicine, Maharishi Markandeshwar Institute of Medical Sciences & Research, Ambala, Haryana India

³Department of Pathology, Sher-i-Kashmir Institute of Medical Sciences, Srinagar, Jammu and Kashmir, India

Corresponding Author: Muzamil Latief, Resident, Department of Nephrology, Gandhi Medical College & Hospital, Secunderabad Telangana, India, e-mail: muzamillatief.b@gmail.com

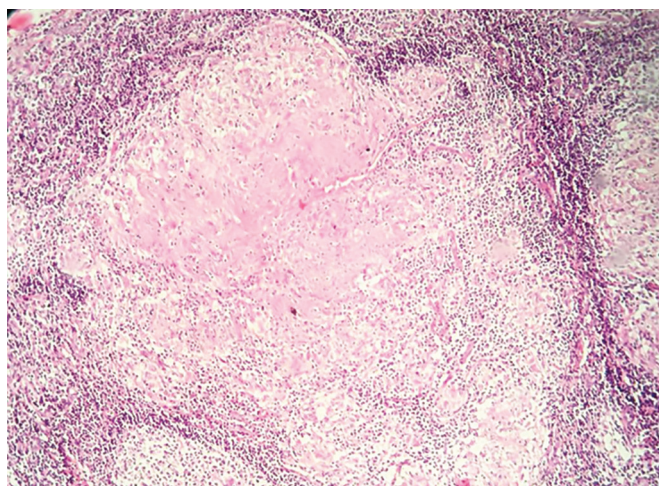


Fig. 1: Granulomatous inflammation of lymph node

which revealed granulomatous inflammation (Fig. 1). So, a diagnosis of PD with tubercular cervical lymphadenitis was considered. Patient was started on indomethacin 50 mg 8 hourly and four-drug weight-based regimen for TB that included rifampicin, isoniazid, pyrazinamide, ethambutol and 20 mg of pyridoxine. Patient began to improve and joint manifestations completely subsided over the subsequent 3 weeks. Fever subsided and lymphadenopathy regressed. Patient has recently completed TB treatment and is doing well and currently is not on any medication.

DISCUSSION

Poncet's disease is a part of the spectrum of tuberculous infection. It is a rare entity and many a times misdiagnosed as other rheumatologic condition. The literature is based on case reports and case series only. Poncet's disease is a reactive arthritis as a consequence of tuberculous infection of an organ other than the joint *per se*.⁵ Tubercular infection can lead to many clinical manifestations due to immunologic and hypersensitivity mechanisms like erythema induratum, erythema nodosum, amyloidosis, and reactive arthritis. This joint involvement is mainly of the ankles, wrists, elbows, and knees.⁶ Literature reveals that the frequency of joint involvement is ankles 63.3%, knees 58.8%, and elbows 23.1%. However, multiple joint involvement is more common than isolated single joint involvement.⁷ Genetic predisposition and association with the expression of specific human leukocyte antigen (HLA DR3 and HLA DR4) has been suggested with PD. This association is because of immune hyperresponsiveness to mycobacterial TB antigens.⁸ Based on antigenic similarity between human cartilages with mycobacterium TB antigens, there is immune cross-reactivity that may result in PD.^{9,10} Literature reveals that PD usually occurs in patients with extrapulmonary TB. Erythema nodosum is an important hallmark of PD.¹¹ Poncet's disease is usually a diagnosis of exclusion and the treatment is with

anti-inflammatory agents like NSAIDs and ATT. Patient's response subsequently to this treatment substantiates the diagnosis. Similar thing happened in our patient who responded very well to NSAIDs and ATT. Diagnostic criteria of PD have been proposed by Rueda et al.⁵ The evidence of TB in our patient was established by lymph node biopsy as in this case reported recently.¹² Incorrect diagnosis and immunosuppression started thereof can worsen the signs and symptoms.¹³

CONCLUSION

Diseases like PD, though being rare entities, still have very much clinical importance given the possibility of misdiagnosis and wrong treatment which otherwise is very much treatable with ATT and NSAIDs. Hence, clinical suspicion is very important in this disease state.

REFERENCES

1. WHO. Fact sheets on tuberculosis. Geneva: WHO; 2018. [cited 2018 Jan]. Available from: <http://www.who.int/mediacentre/factsheets/fs104/en/>.
2. Gupta KB, Prakash P. Recurrent Poncet's disease—a rare presentation. *Ind J Tub* 2001;48:31-33.
3. Silva I, Mateus M, Branco JC. Poncet's disease: a symmetric seronegative polyarthritis with enthesopathy refractory to the therapy. *Acta Reumatol Port* 2013 Jul-Sep;38(3):192-195.
4. Lugo-Zamudio GE, Barbosa-Cobos RE, González-Ramírez LV, Delgado-Ochoa D. Tuberculous rheumatism "Poncet's disease". Case report. *Cir Cir* 2016 Mar-Apr;84(2):169-172.
5. Rueda JC, Crepy MF, Mantilla RD. Clinical features of Poncet's disease. From the description of 198 cases found in the literature. *Clin Rheumatol* 2013 Jul;32(7):929-935.
6. Franco-Paredes C, Díaz-Borjon A, Senger MA, Barragan L, Leonard M. The ever-expanding association between rheumatologic diseases and tuberculosis. *Am J Med* 2006 Jun;119(6):470-477.
7. Wilkinson AG, Roy S. Two cases of Poncet's disease. *Tubercle* 1984 Dec;65(4):301-303.
8. Ames PR, Capasso G, Testa V, Maffulli N, Tortora M, Gaeta GB. Chronic tuberculous rheumatism (Poncet's disease) in a gymnast. *Br J Rheumatol* 1990 Feb;29(1):72-74.
9. Holoshitz J, Klajman A, Drucker I, Lapidot Z, Yaretsky A, Frenkel A, van Eden W, Cohen IR. T lymphocytes of patients with rheumatoid arthritis patients show augmented reactivity to a fraction of mycobacteria cross-reactive with cartilage. *Lancet* 1986 Aug;2(8502):305-309.
10. Pugh MT, Southwood TR. Tuberculous rheumatism, Poncet disease: a sterile controversy? *Rev Rhum Ed Fr* 1993 Dec;60(12):735-740.
11. Kroot EJ, Hazes JM, Colin EM, Dolhain RJ. Poncet's disease: reactive arthritis accompanying tuberculosis. Two case reports and a review of the literature. *Rheumatology (Oxford)* 2007 Mar;46(3):484-489.
12. Dheda K. Tuberculosis and Poncet's disease: the many faces of an old enemy. *Lancet* 2016 Feb;387(10018):618.
13. Adhi F, Hasan R, Adhi M, Hamid SA, Iqbal N, Khan JA. Poncet's disease: two case reports. *J Med Case Rep* 2017 Apr;11(1):93.