

RESEARCH ARTICLE

Evaluation of Greater Palatine Foramen and Incisive Canal Foramen among Saudi Patients using Cone Beam Computed Tomography Scans

¹Muath K Alotaibi, ²Mohammad A Alansari, ³Jarallah M Alqahtani, ⁴Abdullah A Alduhaymi, ⁵Ahmad Assari
⁶Mohammad A Baseer

ABSTRACT

Introduction: The greater palatine foramen (GPF) and incisive canal foramen (ICF) play an important role in administering the local anesthetics.

Aim: To evaluate the anatomic and morphologic variability of GPF and ICF in relation to age and gender of Saudi dental patients using cone beam computed tomography (CBCT) scans.

Materials and methods: This descriptive cross-sectional study evaluated the 182 CBCT scans of Saudi dental patients who were examined for GPF (n = 364) and ICF (n = 182) who had attended a private dental school. The relationship of GPF and ICF to the surrounding structures, midline maxillary suture (MMS) to the posterior border of the maxilla, dimensions and opening direction of ICF, and the dimensions of the canals were evaluated. Chi-square test, independent Student's t-test, and analysis of variance (ANOVA) tests were applied to elicit statistical significance.

Results: Findings revealed that the gender variations were significant in lateral to medial diameter GPF, GPF distance to midline, GPF distance to posterior maxilla, and distance between ICF to GPF. Similarly, age groups showed differences in GPF distance to midline, and distance between ICF and GPF. A significant positive correlation between age and distance of IC to GPF was observed ($r = 0.14$, $p = 0.007$). Age showed a significant positive correlation with IC length ($r = 0.151$, $p = 0.041$).

Conclusion: Age and gender differences were obvious with regard to dimension and morphology of the GPF, ICF, and other adjacent structures among Saudi dental patients as revealed by CBCT scans.

Keywords: Anatomy, Cone beam computed tomography, Greater palatine foramen, Incisive canal, Incisive canal foramen, Morphology, Saudi.

How to cite this article: Alotaibi MK, Alansari MA, Alqahtani JM, Alduhaymi AA, Assari A, Baseer MA. Evaluation of Greater Palatine Foramen and Incisive Canal Foramen among Saudi Patients using Cone Beam Computed Tomography Scans. *J Oral Health Comm Dent* 2018;12(2):56-61.

Source of support: Nil

Conflict of interest: None

INTRODUCTION

Incisive canal, also known as the nasopalatine canal (NPC) or anterior palatine canal, is long thin passage that connects the floor of the nasal cavity to the palate and ends in the oral cavity as a single ICF behind the upper central incisor. The nasopalatine nerve is highly an important anatomical structure and lies in the palatal midline behind the maxillary central incisors.¹ Due to the fact that palate is the most sensitive area of the oral cavity for injections,² a thorough knowledge of the anatomical landmarks and variation of the incisive foramen (IF) is essential prior to surgical procedures like implant placement and local anesthetic injection in the anterior maxilla.³

The greater palatine canal transfers the greater palatine nerve and the palatine artery from the pterygopalatine fossa to the oral cavity through its inferior orifice, the GPF. Greater palatine canal approach is commonly used to give local anesthesia (LA) to the pterygopalatine fossa to anesthetize trigeminal nerve of maxillary division. This technique produces anesthesia of half of the maxilla.^{4,5} Treatment in several areas of the maxilla often requires multiple administration of the anesthetic solution, depending on the site interested and increasing the dosage of the drug and the time of the procedure. To overcome such drawbacks, a maxillary nerve block may be performed to anesthetize the whole area. The greater palatine approach was successful and useful, providing profound anesthesia in the hemi-maxilla, if practiced properly.⁶

Administration of LA plays a major role in the success of various dental procedures as pain control is one of the keys for patient satisfaction, cooperation, and to avoid its associated complications. The precise and accurate location of ICF and GPF is important for several specialties of

¹⁻⁴Intern, ⁵Postgraduate Student, ⁶Assistant Professor

¹⁻⁴Department of Maxillofacial Surgery, Riyadh Colleges of Dentistry and Pharmacy, Riyadh, Kingdom of Saudi Arabia

⁵Department of Maxillofacial Surgery and Diagnostic Sciences Riyadh Colleges of Dentistry and Pharmacy, Riyadh, Kingdom of Saudi Arabia

⁶Department of Preventive Dentistry, Riyadh Colleges of Dentistry and Pharmacy, Riyadh, Kingdom of Saudi Arabia

Corresponding Author: Muath K Alotaibi, Intern, Department of Maxillofacial Surgery, Riyadh Colleges of Dentistry and Pharmacy, Riyadh, Kingdom of Saudi Arabia Phone: +966561101176, e-mail: MuathkhaledQ@Gmail.com

dentistry and otolaryngology, as the failure leads to inadequate anesthesia. Hence, it is essential for practitioners to have a good background of the anatomical relations of the field of work and the areas of needle penetration while administering the local anesthetic solution.^{7,8} The CBCT is a relatively common imaging modality widely used in maxillofacial imaging to localize anatomical structures.⁹ Until now, there are no reported studies on the variability of GPF and IF among Saudi patients using CBCT scans.

Hence, the present study aimed to evaluate the anatomic and morphologic variability of GPF and ICF in relation to age and gender of Saudi dental patients using CBCT scans.

MATERIALS AND METHODS

Ethical Approval

This study was approved by the research center of Riyadh Colleges of Dentistry and Pharmacy (RC/IRB/2016/004).

Study Design and Setting

This cross-sectional descriptive study evaluated the CBCT scans taken from 182 (78 male, 104 female) Saudi patients referred to the oral diagnostic department of private dental university clinics at Riyadh, Saudi Arabia during the period from 2013 to 2016.

The CBCT images were obtained using recommended exposure and patient positioning protocols (85 kVp, 5–7 mA, and 14 seconds) with a CBCT unit (Sirona Galileos, Germany). Images were exported and viewed using digital images analysis software (KDIS 3D imaging software 1.4, Carestream Health Inc.) which allowed the measurement of the landmarks on 287 μ m cuts. This software provides detailed dimensional measurements of ICF and GPF. All images were observed and evaluated by calibrated examiners using a three-dimensional coordinate technique.¹⁰

Each GPF's dimension was measured anteroposteriorly and mediolaterally, the distance from the foramen to the MMS and the posterior border of the palate was measured, and the angle formed by a line from the foramen to the IF with the midline was calculated. Similarly, the anteroposterior and mediolateral dimensions of IF along with canal length and angulations were measured. The classification of the NPC shape was recorded according to the classification in sagittal sections of CBCT images.¹¹ The samples included both mixed, permanent dentition, and edentulous patients. CBCT scans of patients with orthognathic surgery, history of systemic diseases affecting bone (thyroid disease, hyperparathyroidism, diabetes mellitus, chronic renal disease, and osteoporosis), technical errors, and poor-quality images were excluded from the study.

Reliability Assessment

For interexaminer reliability, the four examiners evaluated 30 scans and their results were calculated using the Cronbach's alpha for each point. The average of Cronbach's alpha for the points was found to be 0.74.

Statistical Analysis

Descriptive statistics of age groups, gender, GPF and ICF shape, direction, diameter, and relative location to craniofacial anatomic structures were calculated. The chi-square test of association was applied to test the distribution of opening direction of GPF across different age groups and genders. Fisher's exact test was applied whenever the expected cell count requirement of five failed. The GPF and ICF diameter and distances with adjacent structures were measured in millimeters compared between males and females by applying independent *t*-test. Similarly, ANOVA test was applied to compare mean values between different age groups. Pearson's correlation test was also performed to know the relationship between variables. All the statistical analysis was performed using IBM® Statistical Package for the Social Sciences statistics version 21.0 statistical software package. For all the statistical purposes, a *p*-value of ≤ 0.05 was considered significant.

RESULTS

In this study, a total of 182 CBCT tomograms that belonged to the Saudi dental patients were examined for the ICF and GPF. The mean age of patients was 39.79 ± 14.93 years (11–77 years). The mean age of males was 42.37 ± 15.94 years and that of females was 37.85 ± 13.89 years. Distribution of ICF and GPF among different age groups and gender is shown in Table 1.

Eighty-three (45.6%) CBCT images displayed hour-glass type of IC shape followed by cone 67 (36.8%), funnel 15 (8.2%), and banana 17 (9.3%). Similarly, most of the GPF 221 (60.7%) showed posterolateral opening direction followed by posteromedial 136 (37.4%), anterolateral 5 (1.4%), and anteromedial 2 (0.5%) as shown in Table 2.

Table 1: Distribution of ICF and GPF among different age groups and gender

Variables		ICF		GPF	
		<i>n</i>	%	<i>n</i>	%
Age (years)	≤ 35	78	42.9	152	41.8
	36–50	59	32.4	126	34.6
	Above 50	45	24.7	86	23.6
	Total	182	100	364	100
Gender	Male	78	42.9	156	42.9
	Female	104	57.1	208	57.1
	Total	182	100	364	100

Table 2: Distribution of IC shape and opening direction of GPF

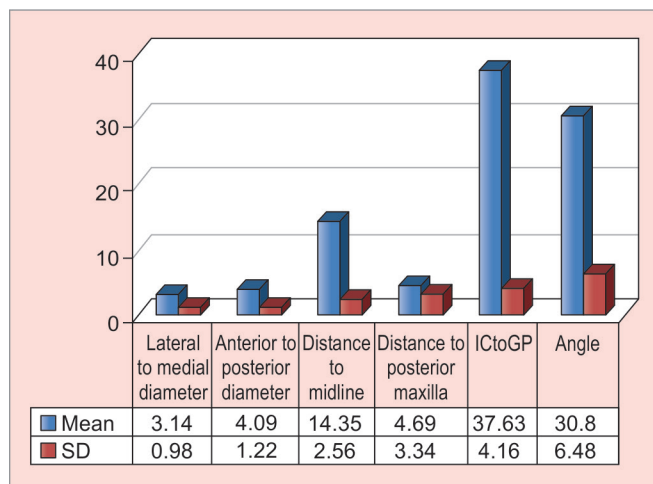
Variables		n	%
IC shape	Hourglass	83	45.6
	Cone	67	36.8
	Funnel	15	8.2
	Banana	17	9.3
	Total	182	100
Opening direction of GPF	Posterolateral	221	60.7
	Posterior to medial	136	37.4
	Anterolateral	5	1.4
	Anteromedial	2	0.5
	Total	364	100.0

Opening direction of GPF did not show any significant association with different age groups and gender $p > 0.05$, as shown in Table 3.

Measurements of GPF showed a lateral to medial diameter of 3.14 ± 0.98 mm, anterior to posterior diameter of 4.09 ± 1.22 mm, distance to midline was found to be 14.35 ± 2.56 mm, and distance to posterior maxilla was found to be 4.69 ± 3.34 mm. The distance between IC and GPF was 37.63 ± 4.16 mm, and opening direction of IC angle was found to be 30.8 ± 6.48 mm as shown in Graph 1.

When lateral to medial diameter of GPF is compared between male (3.33 ± 1.05 mm) and female (2.99 ± 0.89 mm) subjects, a statistically significant difference ($p = 0.001$) was observed. Similarly, CBCT images of males showed a significantly higher distance between GPF and midline (4.16 ± 1.32 mm), distance between GPF and posterior maxilla (5.14 ± 3.64 mm) compared with the female subjects ($p < 0.05$). Further, males (38.50 ± 4.23 mm) showed significantly higher distance from IC to GPF than females (36.99 ± 3.99 mm, $p = 0.001$). Opening direction of IC angle did not show any significant difference between male and female subjects ($p = 0.270$).

Male subjects showed higher values for lateral to medial, anterior to posterior dimensions of ICF when compared with female counterpart without any statistically significant differences ($p > 0.05$). Similarly, IC length (14.27 ± 4.62 mm) was higher in males compared with the



Graph 1: Dimension of GPF and its relation to other structures (in mm)

females (13.08 ± 4.06), and the difference was not statistically significant ($p = 0.065$) as shown in Table 4.

A significant variation of distance between GPF and midline, and distance between ICF and GPF was observed in different age groups considered in the study ($p < 0.05$). The age group above 50 years had significantly higher mean distance of ICF to GPF compared with 36 to 50 years and ≤ 35 years age groups. On the contrary, age groups did not show any significant variations in lateral to medial diameter, anterior to posterior diameter, distance to palatal midline, and direction of IC angle as shown in Table 5.

GPF showed weak, statistically significant relationship with age and distance to midline ($r = 0.111$, $p = 0.034$) and significant positive correlation between age and distance of IC to GPF was also observed ($r = 0.14$, $p = 0.007$). However, a significant weak negative relationship between gender and lateral to medial diameter ($r = -0.175$, $p = 0.001$), distance to midline ($r = -0.119$, $p = 0.024$), distance to palate ($r = -0.117$, $p = 0.025$), and ICF and GPF ($r = -0.180$, $p = 0.001$) was observed with regard to GPF. However, age was the only variable that showed significant positive correlation with IC length ($r = 0.151$, $p = 0.041$) as shown in Table 6.

Table 3: Cross-tabulation between age group, gender, and opening direction of GPF

Variables		Posterior and lateral		Posterior and medial		Anterior and lateral		Anterior and medial		Chi-square	p-value*
		n	%	n	%	n	%	n	%		
Age (years)	≤ 35	94	42.5	56	41.2	2	40	0	0	6.645	0.278
	36–50	71	32.1	53	39.0	2	40	0	0		
	>50	56	25.3	27	19.9	1	20	2	100		
	Total	221	100	136	100	5	100	2	100		
Gender	Male	88	39.8	66	48.5	1	20	1	50	3.828	0.260
	Female	133	60.2	70	51.5	4	80	1	50		
	Total	221	100	136	100	5	100	2	100		

* Fisher's exact test

Table 4: Comparison of measurements of GPF and IC between genders (mm)

Variables	Gender	n	Mean	SD	t-value	p-value	
GPF	Lateral to medial diameter	Male	156	3.33	1.05	3.30	0.001
		Female	208	2.99	0.89		
	Anterior to posterior diameter	Male	156	4.16	1.32	0.94	0.349
		Female	208	4.04	1.14		
	Distance to midline	Male	156	14.70	2.74	2.23	0.027
		Female	208	14.09	2.39		
Distance to posterior maxilla	Male	156	5.14	3.64	2.24	0.025	
	Female	208	4.35	3.05			
ICF to GPF	Male	156	38.50	4.23	0.20	0.001	
	Female	208	36.99	3.99			
Angle	Male	156	31.26	7.71	1.16	0.270	
	Female	208	30.46	5.36			
ICF	Lateral to medial	Male	78	5.16	4.81	1.10	0.273
		Female	104	4.42	4.21		
	Anterior to posterior	Male	78	3.34	3.21	0.165	0.869
		Female	104	3.26	3.59		
	IC length	Male	78	14.27	4.62	1.856	0.065
		Female	104	13.08	4.06		

Bold values refer ($p < 0.05$) to statistically significant difference

Table 5: Comparison of GPF and ICF dimensions between different age groups

Variables	Age	n	Mean	SD	Std. error	f-value	p-value
Lateral to medial diameter	≤35 years	152	3.04	1.05	0.09	1.316	0.269
	36–50 years	126	3.22	0.92	0.08		
	Above 50 years	86	3.19	0.92	0.10		
Anterior to posterior diameter	≤35 years	152	4.24	1.18	0.10	1.957	0.143
	36–50 years	126	3.98	1.30	0.12		
	Above 50 years	86	3.99	1.16	0.13		
Distance to midline	≤35 years	152	14.16	2.44	0.20	3.360	0.036
	36–50 years	126	14.15	2.56	0.23		
	Above 50 years	86	14.97	2.70	0.29		
Distance to palate	≤35 years	152	4.72	3.05	0.25	2.450	0.088
	36–50 years	126	4.25	2.88	0.26		
	Above 50 years	86	5.27	4.27	0.46		
Distance from ICF to GPF	≤35 years	152	36.93	4.06	0.33	3.949	0.020
	36–50 years	126	38.00	3.90	0.35		
	Above 50 years	86	38.33	4.55	0.49		
Angle	≤35 years	152	30.50	5.83	0.47	2.303	0.101
	36–50 years	126	30.29	6.08	0.54		
	Above 50 years	86	32.10	7.88	0.85		

Bold values refer ($p < 0.05$) to statistically significant difference

DISCUSSION

The CBCT provides in-depth qualitative and quantitative information that is difficult to obtain through the conventional methods of imaging. Due to this, CBCT is making great changes within the field of imaging dentistry. However, concerns related to CBCT are the dose of radiation exposure and duration of exposure.¹ The CBCT is widely used within the field of implantology due to its advantages of discerning minute anatomical details.

This is the first study to evaluate the GPF ($n = 364$) and ICF ($n = 182$) in relation to adjacent structure among the Saudi dental patients by utilizing CBCT scans. Study results revealed considerable variation in opening

direction, anteroposterior diameter, lateral to medial diameter, distance to midline, distance to posterior maxilla, and distance of IC to GPF.

While administering local anesthetic injection, the direction of greater palatal canal should be borne in mind. A wide variation in the opening direction of the GPF was reported in the literature. Opening of the foramen was directed inferiorly in anteromedial direction in more than half of the Nigerian and more than 90% of Indian skulls.¹² Saralaya and Nayak¹³ found that it was forward and medially directed in 46.2% and forward in 41.3%. However, the present study showed more than 60% of the GPF opened in posterolateral direction among

Table 6: Pearson's correlation between variables

Foramen	Variables	Correlation	p-value	
GPF	Age	Gender	0.026	0.619
		Opening direction	0.016	0.758
	Lateral to medial diameter		0.07	0.185
		Anterior to posterior diameter	-0.089	0.091
		Distance to midline	0.111*	0.034
	Distance to palate	0.048	0.363	
	Incisive canal to GPF	0.140**	0.007	
	Angle	0.085	0.106	
	Gender	Age group	0.026	0.619
		Opening direction	-0.059	0.261
		Lateral to medial diameter	-0.175**	0.001
		Anterior to posterior diameter	-0.05	0.339
		Distance to midline	-0.119*	0.024
		Distance to palate	-0.117*	0.025
Incisive canal to GPF		-0.180**	0.001	
Angle	-0.061	0.246		
ICF	Age	Incisive canal	0.151*	0.041

*Correlation is significant at the 0.05 level; ** Correlation is significant at the 0.01 level

Saudi sample. This variation could be the reason for occasional difficulties encountered while inserting the point of the needle into GPF and pterygopalatine canal.¹⁴

The maximum observed anteroposterior, medial to lateral GPF diameter was nearly 6 times that of the minimum value. The maximum observed distance to midline was four times higher than the minimum.

Our study reported mean anteroposterior diameter of GPF of 4.09 ± 1.22 mm, which is within the range of 4.5 to 5.3 mm, reported in a recent systematic review.⁸ This could be due to the fact that study sample consisted of dentulous, edentulous, and mixed dentition patients. However, the mean anteroposterior diameter of GPF among Lebanese sample was higher than in the present study.¹⁵

In the present study, average distance to midline from GPF was found to be 14.35 ± 2.56 mm, which is similar to the other reported studies,^{16,17} and lower than that reported by other studies.^{8,18} On the contrary, other studies have measured distance to midline from GPF on both right and left sides and found side-related differences in GPF findings.^{8,15} No such side-related distance was considered in this study; instead, an average distance was calculated.

Previous studies have reported that the mean distance from the posterior border of maxilla to the GPF was 3.5 and 3.7 mm in Nigerian and Indian skulls respectively.¹² Similarly, studies have also reported a mean distance of 4.11 and 4.2 mm in Indian and Chinese skulls.^{13,19} In this study, a mean distance from the posterior border of maxilla to the GPF was found to be 4.69 ± 3.34 mm, which

lies within the limits of other mentioned studies. This variability could be due to the maxilla-palatine suture growth and eruption of teeth occurring on the maxilla.

The distance from the GPF to the ICF was found to be 37.63 ± 4.16 mm. This measurement is almost similar to the other reported studies.^{13,20}

The mean angle formed between MMS and the line from the IF and GPF was higher than previously reported studies by Sarlaya and Nayak. The importance of this angle lies in that it would help dental practitioner to determine the angle to be made by the needle for anesthetic infiltration into GPF, as locating MMS is an easily identifiable landmark.

The present study findings clearly showed significant gender differences in GPF geometry, supporting old reports of smaller GPF measurements in females.^{21,22} This finding is not unique due to differences in males-females in various craniofacial structures.^{23,24} However, the anterior to posterior diameter of GPF did not reach statistical significance when compared between genders. This could be due to the measurement error or insufficient numbers of male/female subsamples.

The anatomical variations in the morphology and dimensions of the IC remain inadequately reported among Saudi population. This study showed large variability of IC shape. Hourglass type was the most common IC reported in this study. This finding is contrary to other reported studies in which cylindrical-shaped canal was most commonly observed.^{3,11,25}

Mean length of IC varied in different studies and it ranged from 8.1 to 12 mm.^{3,25-27} However, in this study, mean IC length was found to be 13.67 mm, which is within the limits of previously reported studies. One of the reasons could be that the study sample included both dentulous and edentulous subjects.

In the present study, male subjects showed relatively higher mean values of IC length, lateral to medial, and anterior to posterior diameter of IF without any significant differences. These increased mean values could be due to the fact that males have larger craniocaudal measurements of the face compared with the females. This study finding is similar to previously reported studies.^{3,25} The IC showed a significant positive correlation with the age, suggesting changes in IC length.

Accuracy of the measurements of GPF and IC and IF could have been affected by several factors, such as performance of the examiners, sensitivity of the mouse, software program used, and selected reference points. Moreover, imaging technique, patient position during exposure, and time and settings of the exposure parameters all could have played an important role in obtaining CBCT images.

CONCLUSION

This study pointed out anatomic location and variability of the GPF and IC in relation to adjacent structures among Saudi patients. The anatomic deviations in terms of dimension and morphology of GPF and IC are important that need CBCT assessment for treatment planning of various dental procedures involving palate. Hourglass IC and posterolateral opening direction of GPF were common findings in Saudi dental patients. Age and gender differences were obvious with regard to dimension and morphology of the GPF, ICF and other adjacent structures as revealed by CBCT scans.

REFERENCES

- Panjnoush M, Norouzi H, Kheirandish Y, Shamshiri AR, Mofidi N. Evaluation of morphology and anatomical measurement of nasopalatine canal using cone beam computed tomography. *J Dent Tehran Iran* 2016 Aug;13(4):287-294.
- Uckan S, Dayangac E, Araz K. Is permanent maxillary tooth removal without palatal injection possible? *Oral Surg Oral Med Oral Pathol Oral Radiol Endod* 2006 Dec;102(6):733-735.
- Thakur AR, Burde K, Guttal K, Naikmasur VG. Anatomy and morphology of the nasopalatine canal using cone-beam computed tomography. *Imaging Sci Dent* 2013 Dec;43(4):273-281.
- Norton NS. *Netter's head and neck anatomy for dentistry*. 2nd ed. Philadelphia, PA: Elsevier Health Sciences; 2011. p. 553
- Schunke M, Schulte E, Schumacher U. *Thieme atlas of anatomy: head and neuroanatomy*. New York, NY: Thieme; 2007. p. 17
- Aoun G, Zaarour I, Sokhn S, Nasseh I. Maxillary nerve block via the greater palatine canal: an old technique revisited. *J Int Soc Prev Community Dent* 2015 Oct;5(5):359-364.
- Torpy JM, Lynn C, Golub RM. JAMA patient page. Local anesthesia. *JAMA* 2011 Sep 28;306(12):1395.
- Tomaszewska IM, Kmietek EK, Pena IZ, Średniawa M, Czyżowska K, Chrzan R, Nowakowski M, Walocha JA. Computed tomography morphometric analysis of the greater palatine canal: a study of 1,500 head CT scans and a systematic review of literature. *Anat Sci Int* 2015 Sep;90(4):287-297.
- Ikuta CRS, Cardoso CL, Ferreira-Júnior O, Lauris JRP, Souza PHC, Rubira-Bullen IRF. Position of the greater palatine foramen: an anatomical study through cone beam computed tomography images. *Surg Radiol Anat SRA* 2013 Nov;35(9):837-842.
- Assari A, Alasmari B, Aleid M, Salem M. Characteristics of mandibular parameters in different age groups. A CBCT assessment. *EC Dent Sci* 2017;14(2):95-103.
- Mardinger O, Namani-Sadan N, Chaushu G, Schwartz-Arad D. Morphologic changes of the nasopalatine canal related to dental implantation: a radiologic study in different degrees of absorbed maxillae. *J Periodontol* 2008 Sep;79(9):1659-1662.
- Ajmani ML. Anatomical variation in position of the greater palatine foramen in the adult human skull. *J Anat* 1994 Jun;184(Pt 3):635-637.
- Saralaya V, Nayak SR. The relative position of the greater palatine foramen in dry Indian skulls. *Singapore Med J* 2007 Dec;48(12):1143-1146.
- Slavkin HC, Canter MR, Canter SR. An anatomic study of the pterygomaxillary region in the craniums of infants and children. *Oral Surg Oral Med Oral Pathol* 1966 Feb;21(2):225-235.
- Aoun G, Nasseh I, Sokhn S, Saadeh M. Analysis of the greater palatine foramen in a Lebanese population using cone-beam computed tomography technology. *J Int Soc Prev Community Dent* 2015 Dec;5(Suppl 2):S82-S88.
- Sharma NA, Garud RS. Greater palatine foramen—key to successful hemimaxillary anaesthesia: a morphometric study and report of a rare aberration. *Singapore Med J* 2013 Mar;54(3):152-159.
- Nimigean V, Nimigean VR, Buțincu L, Sălăvăștru DI, Podoleanu L. Anatomical and clinical considerations regarding the greater palatine foramen. *Romanian J Morphol Embryol Rev Roum Morphol Embryol* 2013;54(3 Suppl):779-783.
- Hwang SH, Seo JH, Joo YH, Kim BG, Cho JH, Kang JM. An anatomic study using three-dimensional reconstruction for pterygopalatine fossa infiltration via the greater palatine canal. *Clin Anat N Y N* 2011 Jul;24(5):576-582.
- Wang TM, Kuo KJ, Shih C, Ho LL, Liu JC. Assessment of the relative locations of the greater palatine foramen in adult Chinese skulls. *Acta Anat (Basel)* 1988;132(3):182-186.
- Chrcanovic BR, Custódio ALN. Anatomical variation in the position of the greater palatine foramen. *J Oral Sci* 2010 Mar;52(1):109-113.
- Sheikhi M, Zamaninaser A, Jalalian F. Length and anatomic routes of the greater palatine canal as observed by cone beam computed tomography. *Dent Res J* 2013 Mar;10(2):155-161.
- Dave MR, Yagain VK, Anadkat S. A study of the anatomical variations in the position of the greater palatine foramen in adult human skulls and its clinical significance. *Int J Morphol* 2013;31:578-583.
- Bigoni L, Velemínská J, Brůzek J. Three-dimensional geometric morphometric analysis of cranio-facial sexual dimorphism in a Central European sample of known sex. *Homo Int Z Vgl Forsch Am Menschen* 2010 Feb;61(1):16-32.
- Didia BC, Orish C, Ibeachu PC. Macrometric and micrometric study of sexual dimorphism in moramina of middle crania fossa of adult Nigerians. *Int J Morphol* 2010;28:519-524.
- Liang X, Jacobs R, Martens W, Hu Y, Adriaensens P, Quirynen M, Lambrechts I. Macro- and micro-anatomical, histological and computed tomography scan characterization of the nasopalatine canal. *J Clin Periodontol* 2009 Jul;36(7):598-603.
- Mraiwa N, Jacobs R, Van Cleynenbreugel J, Sanderink G, Schutyser F, Suetens P, van Steenberghe D, Quirynen M. The nasopalatine canal revisited using 2D and 3D CT imaging. *Dentomaxillofac Radiol* 2004 Nov;33(6):396-402.
- Song W-C, Jo D-I, Lee J-Y, Kim J-N, Hur M-S, Hu K-S, Kim HJ, Shin C, Koh KS. Microanatomy of the incisive canal using three-dimensional reconstruction of microCT images: an ex vivo study. *Oral Surg Oral Med Oral Pathol Oral Radiol Endod* 2009 Oct;108(4):583-590.