

# Surgical Management of Giant Thoracic Schwannoma in Adults: Our Experience

<sup>1</sup>MA Naveen, <sup>2</sup>R Bharath

## ABSTRACT

Spinal schwannomas are the benign tumors arising from the nerve root sheath and account for 25% of all spinal tumors in adults. Giant spinal schwannomas are rare in the thoracic spine and pose a surgical challenge for complete excision. All the patients in our series underwent parascapular costotransversectomy approach, and this article aims at the surgical steps, merits, and demerits of the approach.

**Materials and methods:** Five patients with giant thoracic spinal schwannomas presented with nonspecific symptoms were diagnosed and operated by the authors at D3 to D5 levels. All the patients underwent complete tumor excision in a single stage by parascapular costotransversectomy approach.

**Results:** Totally, 5 patients (4 females and 1 male) with ages varying from 40 to 52 years underwent complete tumor excision in a single stage by parascapular costotransversectomy approach. No major complication was noted in our series. One patient developed transient nerve root deficit, which improved over 2 months.

**Conclusion:** Parascapular costotransversectomy approach for complete excision of giant thoracic spinal schwannomas is a safe and effective approach. It provides direct access to the lesion and does not necessitate spinal instrumentation.

**Keywords:** Cystic schwannoma, Giant thoracic schwannomas, Parascapular costotransversectomy, Spinal schwannoma.

**How to cite this article:** Naveen MA, Bharath R. Surgical Management of Giant Thoracic Schwannoma in Adults: Our Experience. *J Spinal Surg* 2018;5(2):69-72.

**Source of support:** Nil

**Conflict of interest:** None

## INTRODUCTION

Spinal schwannomas are the benign tumors arising from the nerve root sheath and account for 25 to 30% of all spinal tumors in adults.<sup>1</sup> Giant spinal schwannoma is defined as a lesion, which extends to more than two vertebral levels. These tumors are usually encapsulated,

well demarcated, and can occur in diverse locations including the thoracic region.<sup>2</sup> Giant spinal schwannomas usually have an indolent course due to the slow tumor growth and generally present with back pain. However, in our case series, all the patients presented with nonspecific symptoms like cough and chest pain. The surgical approach of parascapular costotransversectomy to the thoracic spine lesion was originally described by Menard and was popularized by Capener.<sup>3</sup>

## MATERIALS AND METHODS

The authors present their experience with the parascapular costotransversectomy approach in the management of five patients with giant thoracic spinal schwannoma. There were four females and a male patient with age ranging from 40 to 52 years. The most common complaints were cough and chest pain. All five patients were operated at D3 to D5 levels and the mean tumor size was 6 cm in its maximum diameter (Fig. 1).

## Surgical Technique

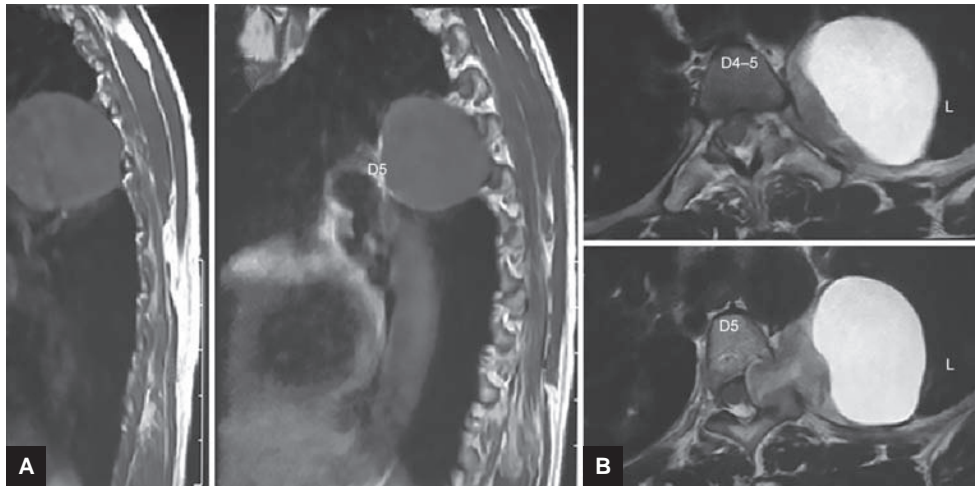
The patient was placed in a prone position on bolsters, and the vertebral level to be operated was identified using C-arm imaging. The corresponding rib, rather than the vertebrae, has to be identified and marked pre-operatively. All the pressure points were padded adequately. The incision used was paramedian-curvilinear, with the convexity of the curve on the ipsilateral side of the lesion (Fig. 2). The skin flap was reflected laterally and fascia incised and dissected following which the trapezius and latissimus dorsi muscles were exposed. The muscles were transected parallel to the rib using electrocautery to minimize bleeding (Fig. 3).

The rib under consideration is now exposed. Subperiosteal dissection is carried out medially to separate the attached muscles and the vascular bundle from the rib. If the exposure is not adequate, the upper and the lower rib can also be denuded and excised along with the transverse process. The costotransverse joint has not less than five ligaments, and the joint can be resected *en bloc*. The head of the rib is now disarticulated from the attached vertebrae. Normally 6 to 7 cm of the rib is resected, but the length can vary depending on the pathology. Before excising the rib, the underlying pleura needs to be separated and preserved cautiously (Fig. 4).

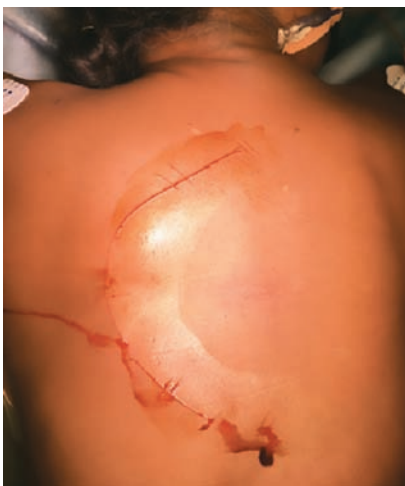<sup>1</sup>Assistant Professor, <sup>2</sup>Consultant

<sup>1,2</sup>Department of Neurosurgery, Kempegowda Institute of Medical Sciences Hospital and Research Centre, Bengaluru Karnataka, India

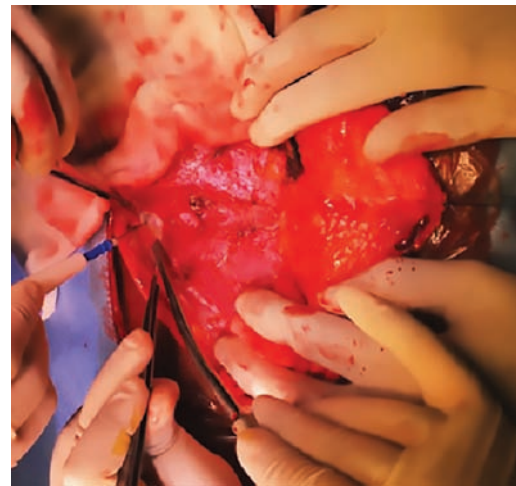**Corresponding Author:** MA Naveen, Assistant Professor Department of Neurosurgery, Kempegowda Institute of Medical Sciences Hospital and Research Centre, Bengaluru, Karnataka India, Phone: +919986655585, e-mail: navinmdy@gmail.com



**Figs 1A and B:** Preoperative MRI showing cystic schwannoma at D4 to D6 level



**Fig. 2:** Photograph showing the paramedian-curvilinear incision with the convexity of the curve toward the side of the lesion (left side in the above case)



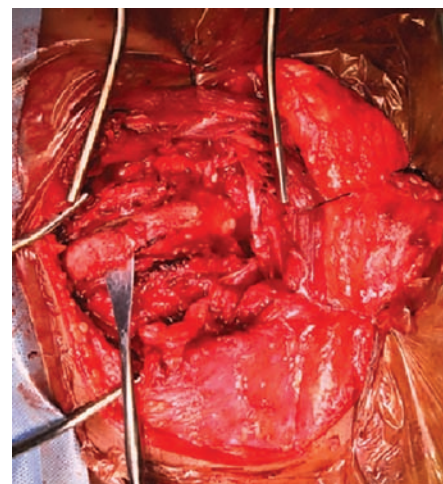
**Fig. 3:** The muscles being cut using the electrocautery and gaining access to the lesion

To visualize the lateral portion of the dura, the pedicle can be drilled either partly or completely, which allows direct access to the tumor (Fig. 5).

The large cystic tumor-like condition in our case was seen abutting the adjacent pleura, which made it difficult in separating the tumor from the latter (Fig. 6). The cystic tumor was aspirated in our case to decompress the size of the tumor, which also helps in dissection of the neural elements. The direction of tumor dissection has to be away from the spinal cord to minimize damage to the neural elements. The tumor removal is then carried out carefully and completely with the capsule (Fig. 7).

## RESULTS

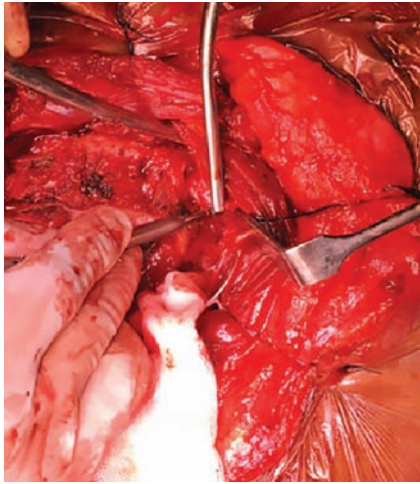
Gross total excision was performed in all five patients. Intercostal drain was inserted in all the patients to avoid chest complications. All five patients were extubated on table and no major complications were encountered in our study. One patient developed transient nerve root deficit



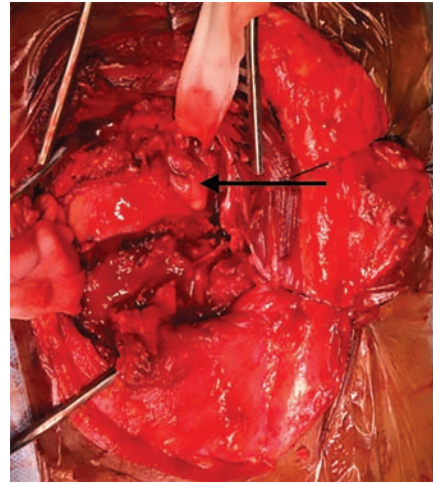
**Fig. 4:** Following subperiosteal resection, the rib is being separated from the underlying pleura and the rib is severed for the exposure of the tumor

in the form of paresthesia, which resolved in subsequent follow-up. Histopathological examination of the lesion in all five patients revealed cystic schwannoma (Fig. 8).

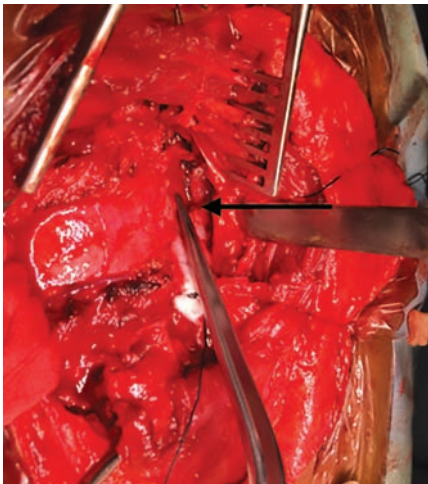



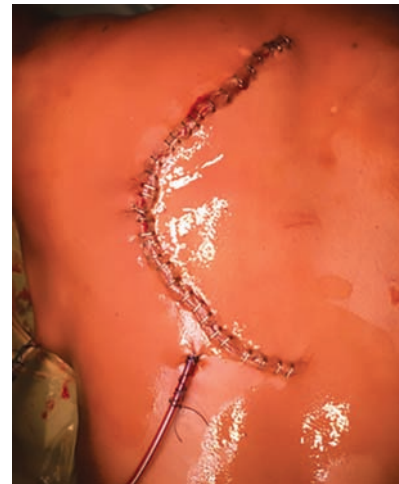
**Fig. 5:** Intraoperative photograph showing drilling of the pedicle



**Fig. 6:** After removing the ribs, the complete tumor is visualized and is abutting the adjacent pleura



**Fig. 7:** Intraoperative photograph showing the cord after complete removal of the tumor



**Fig. 8:** Photograph following wound closure with chest tube and drain *in situ*

## DISCUSSION

Spinal schwannomas are benign, encapsulated, slow-growing tumors that arise from the nerve root sheath. They are mostly heterogeneously solid and rarely cystic in nature. Giant spinal schwannoma is defined as a lesion that extends over two or more vertebral levels. When the spinal schwannoma erode vertebral bodies and invade the myofascial planes, then it is termed as invasive spinal schwannoma.<sup>4</sup> The spinal schwannomas are most often located in the lumbar, thoracic, and cervical regions, with most of the reported literature showing the location of the tumor below the T8 level.<sup>2,5</sup> Giant spinal schwannomas usually have an indolent course due to the slow tumor growth rate. The presentation of symptoms can be extremely diverse depending on the location of the tumor.<sup>6</sup> These lesions present with local pain, paresthesias, numbness, motor weakness, and nonspecific symptoms including cough and chest pain. Cystic schwannomas have a high risk of causing

progressive symptomatic worsening as a result of cyst expansion. Spinal schwannomas may become symptomatic at any age, but peak incidence is between the fourth and fifth decades.<sup>7</sup> Magnetic resonance imaging (MRI) is the imaging modality of choice for these lesions. It shows the exact location, extent of the lesion, and involvement of the adjacent structures.

Cystic schwannomas show T1 hypointensity and T2 hyperintensity and have to be differentiated from Tarlov cyst, neurenteric cyst, and cystic teratoma.<sup>8</sup> This was a similar finding in our case series.

The surgical approach of parascapular costotransversectomy for thoracic schwannomas has been well documented. Such approaches avoid the need for stage surgeries, and allow complete removal of the tumor with minimal damage to the neural structures.<sup>9</sup> Cyst aspiration and debulking of the tumor are the keys for manipulation of the tumor wall and separation from the neural elements. The main advantage of this approach is

that it allows access to the vertebral body, anterior and lateral epidural space, and the intervertebral foramen. The approach is less morbid and does not necessitate spinal stabilization.

## CONCLUSION

Giant schwannomas are rare in the upper thoracic spine. They can present with cough and chest pain without any neurological deficit. Parascapular costotransversectomy approach for the giant upper thoracic schwannoma is a simple surgical procedure, which allows complete resection of the tumor in one stage without compromising the spinal stability. This approach has evolved to avoid the difficulties and morbidity associated with anterior and transthoracic approaches to an anatomically complex, transitional, and challenging region.

## REFERENCES

1. Kyoshima K, Horiuchi T, Zenisaka H, Nakazato F. Thoracic dumbbell intra and extramedullary schwannoma. *J Clin Neurosci* 2005 May;12(4):481-484.
2. Conti P, Pansini G, Mouchaty H, Capuano C, Conti R. Spinal neurinomas: retrospective analysis and long term outcome of 179 consecutively operated cases and review of the literature. *Surg Neurol* 2004 Jan;61(1):34-43.
3. Seddon HJ. Pott's paraplegia: prognosis and treatment. *Br J Surg* 1935 Apr;22(88):769-799.
4. Yu NH, Lee SE, Jahng TA, Chung CK. Giant invasive spinal schwannoma: clinical features and surgical management. *Neurosurgery* 2012 Jul;71(1):58-66.
5. Asahara H, Kawari A, Harada Y, Senda M, Inove H. Spinal schwannomas: a review of 42 cases. *Acta Med Okayama* 1996 Feb;50(1):25-28.
6. Yang I, Paik E, Huh NG, Parsa AT, Ames CP. Giant thoracic schwannoma presenting with abrupt onset of abdominal pain: a case report. *J Med Case Rep* 2009 Oct;3:88.
7. Seppala MT, Haltia MJ, Sankila RJ, Jaaskelainen JE, Heiskanen O. Long term outcome after removal of spinal schwannoma: a clinicopathological study of 187 cases. *J Neurosurg* 1995 Oct;83(4):621-626.
8. Beall DP, Googe DJ, Emery RL, Thompson DB, Campbell SE, Ly JQ, DeLone D, Smirniotopoulos J, Lisanti C, Currie TJ. Extramedullary intradural spinal tumors: a pictorial review. *Curr Probl Diagn Radiol* 2007 Sep-Oct;36(5):185-198.
9. Fessler RG, Dietze DD Jr, Millan MM, Peace D. Lateral parascapular extrapleural approach to the upper thoracic spine. *J Neurosurg* 1991 Sep;75(3):349-355.