

CASE REPORT

Dermoid Cyst of Neck: A Diagnostic Dilemma and a Therapeutic Challenge

¹Sultanipura N Somashekhar, ²Atul Kulkarni

ABSTRACT

Dermoid cysts are benign congenital tumors of ectoderm origin usually arising from the midline where the fusion of embryonic structures of both sides occurs. However, dermoid cyst can occur on the lateral part of the floor of the mouth. Neck swellings are difficult to diagnose clinically and are close to vital structures. An adult female who presented with a swelling in the right submandibular region of 3-year duration was evaluated and treated surgically. Ranula is a type of mucocele, a disorder of salivary gland usually found in the floor of the mouth. We hereby present this rare mode of presentation of a dermoid cyst with a diagnostic dilemma and a surgical challenge.⁴

Keywords: Computed tomography, Dermoid cyst, Extraoral approach, Floor of mouth, Ranula.

How to cite this article: Somashekhar SN, Kulkarni A. Dermoid Cyst of Neck: A Diagnostic Dilemma and a Therapeutic Challenge. *Int J Head Neck Surg* 2017;8(3):125-127.

Source of support: Nil

Conflict of interest: None

INTRODUCTION

Dermoid cysts are developmental lesions found inside normal organs or tissues as a result of the inclusion of tissue from diverse sources (i.e., ectoblastic, mesoblastic, or endoblastic) caused by a defect in the fusion of the embryonic lateral mesenchymatic mass (mainly the first and second arches) during the 5th week of embryonic development.¹

Meyer² updated the concept of dermoid cyst to describe the following histological variants: True dermoid cyst, the epidermoid cyst, and the teratoid cyst.

True dermoid cysts are cavities lined with epithelium showing keratinization and with identifiable skin on the cyst wall. Epidermoid cysts are lined with simple squamous epithelium with a fibrous wall and no attached structures. The lining of teratoid cyst varies from simple squamous to a ciliate respiratory epithelium containing

derivatives of ectoderm, mesoderm, and/or endoderm. All three histological types contain a thick, greasy-looking material.²

CASE REPORT

An 18-year-old female presented with a slowly enlarging painless swelling in right submandibular region extending to left side for a period of 3 years (Fig. 1). Swelling was not associated with any pressure symptoms like dysphagia, dyspnea, and no other associated symptoms, such as fever, previous history of trauma. The only associative symptom present with the swelling was difficulty in articulating speech. On examination of patient, a lobulated swelling of 8 × 5 cm firm in consistency was noted in right submandibular region extending to the left submandibular region. Intraorally, the swelling was less prominent and only a fullness in the floor of the right side of the mouth was noted. It was a bidigitally palpable cystic swelling with negative transillumination test. Ear, nose, and indirect laryngoscopy was unremarkable. With a clinical diagnosis of dermoid cyst, the following investigations were carried out: Ultrasonography of the neck reported ranula of the floor of the mouth; computed tomography (CT) head and neck showed a biloculated cystic lesion with contents having 0 to 15 HU, lesion pushing tongue and submandibular gland posteriorly and extending to cervical region with no evidence of enhancement s/o ranula (Fig. 2); magnetic resonance imaging (MRI) of neck showed biloculated lesion with

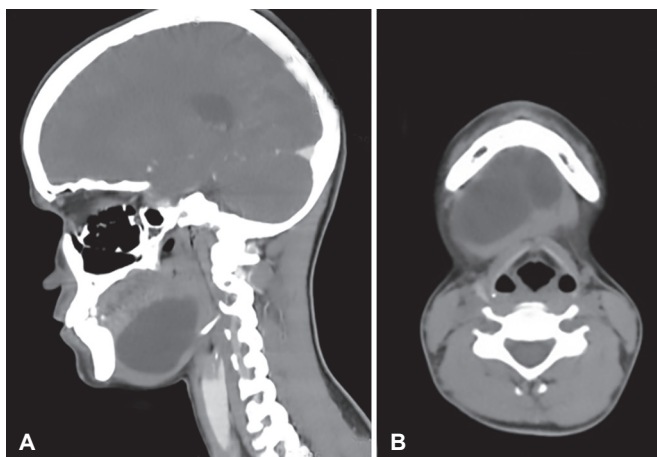


Fig. 1: Preoperative picture of patient with submandibular swelling

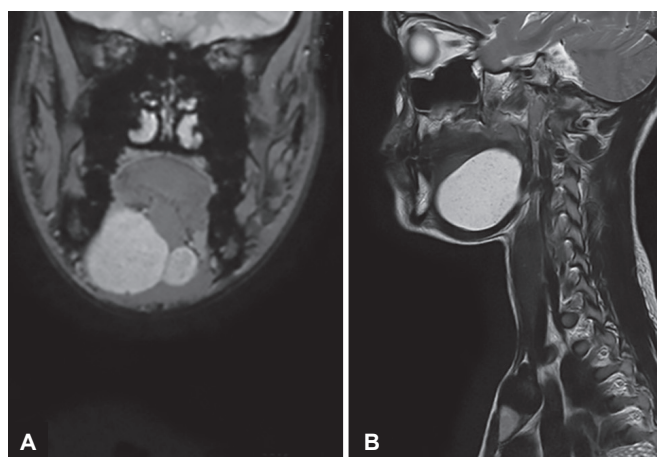
¹Professor, ²Postgraduate

^{1,2}Department of General Surgery, J.J.M. Medical College Davangere, Karnataka, India

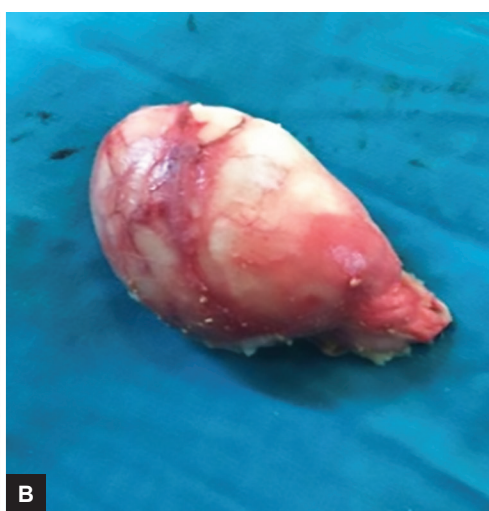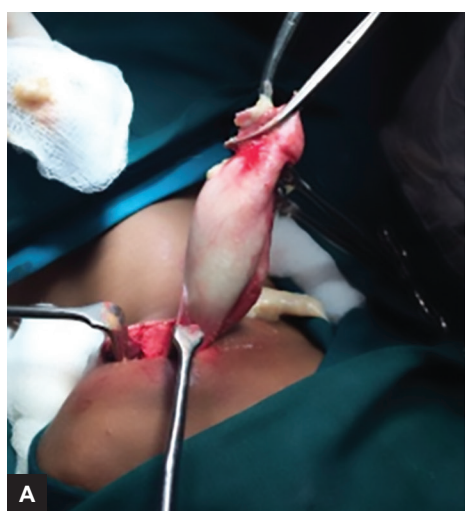Corresponding Author: Sultanipura N Somashekhar, Professor Department of General Surgery, J.J.M. Medical College Davangere, Karnataka, India, e-mail: drsoms91@gmail.com



Figs 2A and B: Computed tomography scan head and neck showing a biloculated lesion with location and extent



Figs 3A and B: Magnetic resonance imaging neck showing biloculated lesion and extent



Figs 4A and B: Intraoperative pictures

smooth round borders in submandibular region with mixed attenuation and scattered calcifications, extending to the opposite side suggestive of ranula (Fig. 3).

Fine-needle Aspiration Cytology Suggestive of Dermoid Cyst

A submandibular incision was made and the platysma was separated intraoperatively. The swelling was found deep to mylohyoid muscle and extending into right submandibular region from the anterior part of mandible to angle of mandible anteroposteriorly. Swelling was dissected completely. White pasty material with debris was found to be the content.

Histopathology suggested that the cyst contained keratinizing stratified squamous epithelial lining wall with debris s/o epidermoid cyst.

DISCUSSION

Dermoid cysts of the floor of the mouth are typically present in the second or third decades of life as a painless,

slow-growing mass in the floor of mouth, submentum, and/or anterior neck in the midline usually.³ Lateral presentation of swelling in the floor of mouth is rare. Clinical examination showing a bilateral swelling firm in consistency with negative transillumination test makes us to think of a rare possibility of bilateral dermoid cyst. However, ultrasonography, MRI, and CT showed the swelling to be ranula with the location, extent, and attenuation of contents suggesting as ranula.⁵ Radiological investigations are not accurate in diagnosing the condition, but provide a probable diagnosis and help in planning for surgery in delineating the extent of the lesion. Fine-needle aspiration cytology (FNAC) suggested it to be a dermoid cyst. While FNAC of the cyst may provide sufficient diagnostic material, it is complicated by potential sampling bias, given the copious keratinaceous cyst contents and relatively scarce epithelium and will often yield inconclusive, variable results.⁵ Preoperative findings and histopathology reports confirmed it to be a dermoid cyst in lateral floor of the mouth (Fig. 4). Surgical excision and biopsy is diagnostic. Surgery is mandatory and curative.⁵

Surgical Approach

Routine dermoid cyst in the midline is approached intraorally because of cosmetic reason; however, the approach depends on size of the cyst and its relation to muscles of the neck and oral cavity.⁴ Intraoral approach has a high risk of injury to lingual and hypoglossal nerves with poor exposure. Extraoral approach as we did in our case is more suitable for large cysts crossing the midline and its relation to the neck muscles as defined in MRI.²

CONCLUSION

Lateral dermoid cysts are rare, yet are considered as differential diagnosis of neck swellings. In cystic masses FNAC value is limited, and CT/MRI will help in extent of mass, to arrive at a probable diagnosis, to plan for treatment, i.e., surgical approach. Type of surgical approach

can be decided based on two factors: location and size of lesion.^{2,4} Histopathological examination is confirmatory in these cases.⁵

REFERENCES

1. Makos C, Noussios G, Peios M, Gougousis S, Chouridis P. Dermoid cysts of the floor of the mouth: two case reports. *Case Rep Med* 2011 Jul;2011:362170.
2. Meyer I. Dermoid cysts (dermoids) of the floor of the mouth. *Oral Surg Oral Med Oral Pathol* 1955 Nov;27(11):1149-1164.
3. Abdulai AE, Avogo D, Nuamah IK, Baddoo H, Gyasi RK. Large lateral dermoid cyst mimicking plunging ranula: A case report. *Int J Case Rep Images* 2014 Jan;5(6):408-412.
4. Bhatnagar A, Verma VK, Patel PK. Intraoral excision of large submental dermoid. *Indian J Dent Res* 2013 Nov-Dec;24(6):765-767.
5. Graham RM, Thomson EF, Woodward RT, Sloan P. Lateral dermoid cyst. *Br J Oral Maxillofac Surg* 2008 Mar;46(2):131-132.