



CASE REPORT

Dermoid Cyst of Pancreas

¹Brahma Dutta, ²Pravin Suryawanshi, ³Praful Pawar

ABSTRACT

Pancreatic dermoid cyst is a rare clinical entity. We report the case of a 26-year-old female who presented with epigastric pain and weight loss for 1 month duration. Ultrasonography and computed tomography (CT) showed large solid cystic mass in the tail of pancreas. At surgery, the entire mass was excised. Histopathologic report revealed it to be a dermoid cyst.

Keywords: Computed tomography, Dermoid cyst, Mature cystic teratoma, Pancreas.

How to cite this article: Dutta B, Suryawanshi P, Pawar P. Dermoid Cyst of Pancreas. MGM J Med Sci 2017;5(1):37-39.

Source of support: MGMIHS

Conflict of interest: None

INTRODUCTION

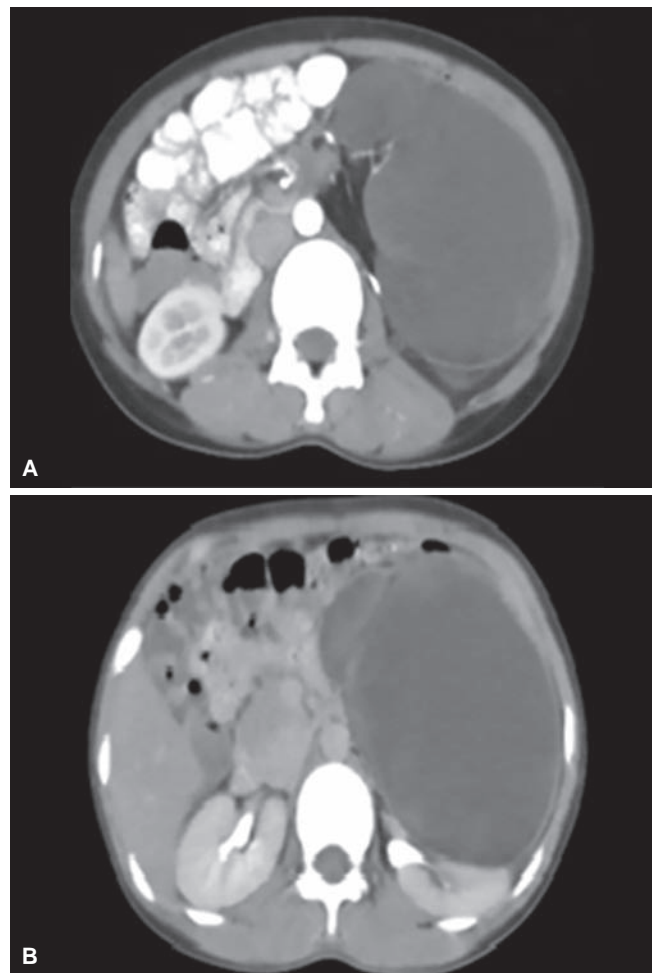
Pancreatic dermoid cyst is a rare germ cell neoplasm with very few published case reports. World literature reports only 35 cases with complete data.¹ Dermoid cyst of the pancreas, also called cystic teratoma, was first described in 1918 by Kerr.² In 1922, it was included by Primrose³ in the classification of cystic pancreatic lesions. Dermoid cysts occur in all ages, have no sex preference, and are commonly found in ovaries,⁴ but may occur in any pathway of ectodermal cell migration. The pancreas is an extremely rare primary site of dermoid cyst with some predilection for the head region.⁵ Clinical picture is nonspecific,⁶ and the preoperative diagnosis is difficult.

CASE REPORT

- A 26-year-old woman was admitted in MGM Hospital, Aurangabad, Maharashtra, India, with epigastric pain, anorexia, weight loss, and backache of 1 month duration. The patient had no significant medical history. On examination, there was mild tenderness in the epigastrium. All laboratory investigations were normal.

- Ultrasonography of abdomen and pelvis showed a large cystic lesion (15 × 11 × 9 cm, approximately 880 cm³) arising from the tail of pancreas and displacing left kidney posterolaterally.
- Computed tomography scan revealed lobulated cystic lesion of 12 × 9 × 14 cm in size, with dense foci of calcification and fat in left lumbar region along tail of pancreas, displacing left kidney posterolaterally and abutting spleen (Fig. 1). No definite lymphadenopathy was seen at the celiac axis origin or in peripancreatic area. The mass appeared to be a peritoneal dermoid cyst.

After preoperative workup, the patient underwent surgery. A large cystic mass of 25 × 10 × 17 cm was seen arising from the tail of pancreas (Fig. 2). It was adherent to transverse colon, omentum, left kidney, left renal vein, spleen, splenic vein, and inferior mesenteric vein (Fig. 3).



Figs 1A and B: Dermoid cyst along pancreatic tail region displacing left kidney posteriorly (A) and abutting spleen laterally (B)

¹Resident, ²Professor and Head, ³Lecturer

¹⁻³Department of Surgery, MGM Medical College & Hospital Aurangabad, Maharashtra, India

Corresponding Author: Brahma Dutta, Resident, Department of Surgery, MGM Medical College & Hospital, Aurangabad Maharashtra, India, Phone: +918551049988, e-mail: duttabrahma@gmail.com

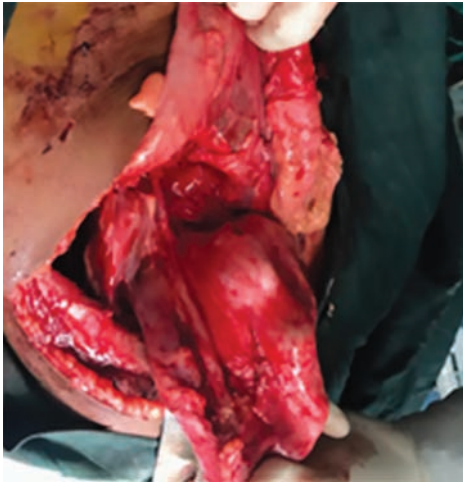

Fig. 2: Dermoid cyst arising from pancreatic tail region

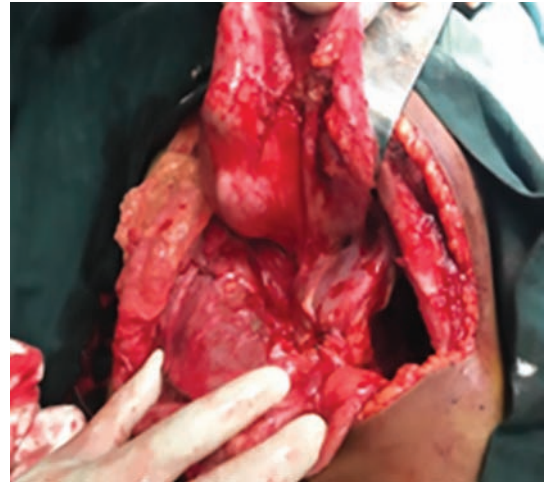


Fig. 3: Dermoid cyst adhered to transverse colon

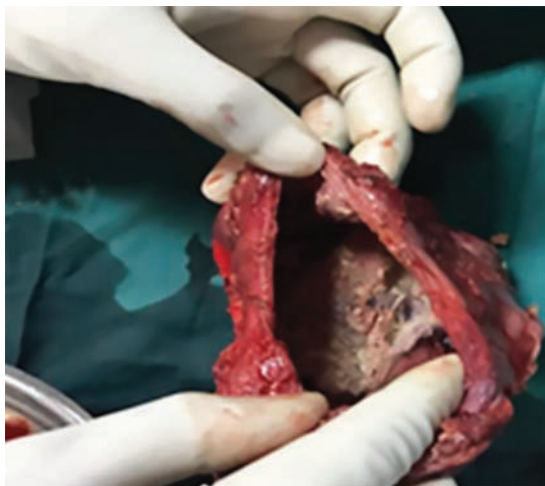

Fig. 4: Surgical specimen shows that the cyst is filled with finely granular, grayish white, keratinaceous, and sebaceous material

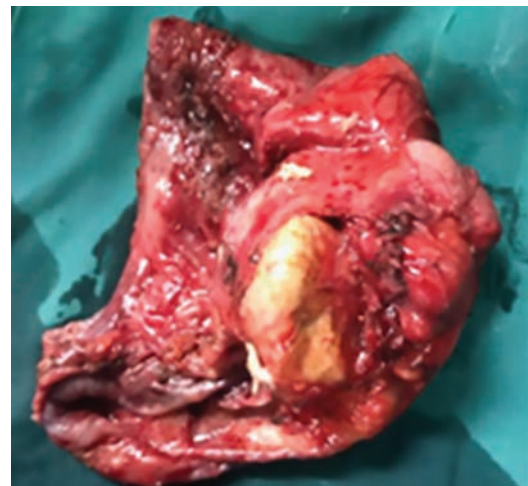

Fig. 5: Macroscopic view of the dermoid cyst

The mass was excised *in toto*. Its cut surface showed pultaceous material, hair, bone, and areas of hemorrhage (Figs 4 and 5). On microscopic examination, cyst wall was lined with stratified squamous epithelium with keratin flakes. Adipose tissue, cartilage, and bony trabeculae were also seen.

DISCUSSION

Teratomas are widely believed to arise from embryonic inclusions of skin at the time of neural groove closure, hence, their characteristic midline localization. Two subtypes of teratomas have been described: Mature and immature. Mature teratomas are further classified as either solid or cystic. Cystic teratomas are also known as "dermoid cysts." Although dermoid cysts most commonly develop within the ovaries, they have been shown to occur anywhere along the route of ectodermal cell migration, usually in the midline. Other reported sites are testis, cranium, brain, mediastinum, omentum, retroperitoneum,

and sacrococcygeal region. Pancreatic dermoid cysts are extremely rare.⁷ They may appear in any site in the pancreas, being more common in the head region. In this case, tumor was found in the pancreatic tail.

Dermoid cysts of the pancreas are true cysts. The cyst wall, which surrounds the lesion, is lined by a single layer of keratinizing stratified squamous epithelium, and the underlying connective tissue may contain adnexal tissue, sebaceous glands, lymphoid tissue, and even inflammatory cells. Dermoid cysts often contain thick, pasty, doughy sebaceous secretions. Fully differentiated tissues from one or more germ cell layers, most commonly the ectoderm, including hair, teeth, bone, cartilage, and dermal appendages, such as hair follicles, sweat glands, and sebaceous material, are also usually encountered.⁸ The difficulty in preoperative diagnosis of pancreatic dermoid cysts is well emphasized in the literature. The presence of fat/fluid or hair/fluid levels is considered pathognomonic of dermoids in other locations, but they are found in only a minority of cases.⁹

In our case, the cyst showed pultaceous material, hair, and bone with areas of hemorrhage. Yu et al¹⁰ reported a dermoid cyst of the pancreas in a 2-year-old child. The cystic wall contained smooth muscle, pancreatic tissue, lymphoid tissue, intestinal tissue, and glial tissue. The case report by Markovskyt and Russin¹¹ was diagnosed preoperatively as dermoid cyst with the use of fine-needle aspiration.

Computed tomography scan imaging is considered to be highly specific and virtually pathognomonic for diagnosis of dermoid cyst of pancreas. Computed tomography accurately estimates the density of all the included tissues, such as soft tissue, fluid, fat, calcification, and teeth.

Treatment of dermoid cysts is through surgical removal, as done in the present case. Being located in the tail region of the pancreas, technically surgery was easier than if it was located in head or body, which have a mortality rate of up to 2%.¹²

CONCLUSION

Pancreatic dermoid cysts are very rare benign neoplasms. To our knowledge, only 35 cases have been reported so far in world literature. Surgical resection remains the gold standard of treatment. It is recommended that surgical excision be undertaken for any symptomatic lesion as well as for any lesion larger than 2 to 3 cm in size. Excision of the lesion provides definitive diagnosis and is curative. Prognosis is excellent.

REFERENCES

1. Lushpai VP. A case of pancreatic teratoma. *Klin Khir* 1997; 7-8:100.
2. Kerr AA. Cysts and pseudocysts of the pancreas: with report of cases. *Surg Gynecol Obstet* 1918 July;27(1):40-44.
3. Primrose A. Pancreatic cyst and pseudocyst. *Surg Gynecol Obstet* 1922 Apr;34(4):431-436.
4. Lane J, Vance A, Finelli D, Williams G, Ravichandran P. Dermoid cyst of the pancreas: a case report with literature review. *J Radiol Case Rep* 2012 Dec;6(12):17-25.
5. Seki M, Ninomiya E, Aruga A, Yamada K, Koga R, Saiura A, Yamamoto J, Yamaguchi T, Takano K, Fujita K, et al. Image-diagnostic features of mature cystic teratomas of the pancreas: report on two cases difficult to diagnose preoperatively. *J Hepatobiliary Pancreat Surg* 2005;12(4):336-340.
6. Degrate L, Misani M, Mauri G, Garancini M, Maternini M, Moltrasio F, Cuttin MS, Romano F, Uggeri R. Mature cystic teratoma of the pancreas. Case report and review of the literature of a rare pancreatic cystic lesion. *JOP* 2012 Jan;13(1): 66-72.
7. Tucci G, Muzi MG, Nigro C, Cadeddu F, Amabile D, Servadei F, Farinon AM. Dermoid cyst of the pancreas: presentation and management. *World J Surg Oncol* 2007 Aug;5:85.
8. Koomalsingh KJ, Fazylov R, Chorost MI, Horovitz J. Cystic teratoma of the pancreas: presentation, evaluation and management. *JOP* 2006 Nov;7(6):643-646.
9. Jacobs JE, Dinsmore BJ. Mature cystic teratoma of the pancreas: sonographic and CT findings. *AJR Am J Roentgenol* 1993 Mar;160(3):523-524.
10. Yu CW, Liu KL, Lin WC, Li YW. Mature cystic teratoma of the pancreas in a child. *Pediatr Radiol* 2003 Apr;33(4): 266-268.
11. Markovsky V, Russin VL. Fine-needle aspiration of dermoid cyst of the pancreas: a case report. *Diagn Cytopathol* 1993;9(1):66-69.
12. Le Borgne J, de Calan L, Partensky C. Cystadenomas and cystadenocarcinomas of the pancreas. A multiinstitutional retrospective study of 398 cases. *Ann Surg* 1999 Aug;230(2): 152-161.