

## CASE REPORT

# Dentigerous Cyst associated with Unerupted Mandibular Second Molar: An Unusual Entity

<sup>1</sup>Sakshi Kamra, <sup>2</sup>Keerthilatha M Pai, <sup>3</sup>Ravindranath Vineetha, <sup>4</sup>Abhay Kamath, <sup>5</sup>Adarsh Kudwa

## ABSTRACT

Dentigerous cyst is a common pathologic entity. After radicular cyst, dentigerous cysts are the most frequent odontogenic cysts diagnosed, accounting for 20% of all mandibular cysts. Typically, they are associated with impacted teeth, usually third molars. Its presentation in association with unerupted permanent second molar is very unusual and rare and very few cases have been reported in the literature. In this report, we describe the case of a pediatric patient with a dentigerous cyst in association with unerupted permanent second molar.

**Keywords:** Dentigerous cyst, Second molar, Unerupted, Unilocular.

**How to cite this article:** Kamra S, Pai KM, Vineetha R, Kamath A, Kudwa A. Dentigerous Cyst associated with Unerupted Mandibular Second Molar: An Unusual Entity. *J Health Sci Res* 2018;9(1):31-33.

**Source of support:** Nil

**Conflict of interest:** None

## INTRODUCTION

Dentigerous cyst starts by separation of the follicle from around the crown of unerupted tooth.<sup>1</sup> It is also named tooth-containing cyst as it encloses the crown of an unerupted tooth at the cemento-enamel junction.<sup>2</sup> They can be associated with an odontoma or developing tooth and even deciduous teeth. It is the second most common type of odontogenic cysts, accounting for 49% of all cystic lesions, with posterior mandible as the most commonly affected site.<sup>3</sup> These cysts are more common in male patients with predilection during the second and third decade of life.<sup>1</sup> Commonly affected teeth in order of occurrence are mandibular third molars, permanent

maxillary canine, permanent maxillary third molar, and less commonly permanent central incisor. Occurrence of such a cyst with permanent second molar is uncommon, with an incidence of 1.1%.<sup>4</sup> Most dentigerous cysts are mainly developmental in origin, but may have an inflammatory pathogenesis. Patients are mostly asymptomatic in early stages unless there is an acute inflammatory exacerbation of the lesion. Pain, swelling, mild sensitivity, tooth mobility, and displacement follow if the cyst reaches size more than 2 cm in diameter.<sup>1</sup> Radiographically, it is characterized by a well-defined, unilocular radiolucent lesion surrounding the crown of an unerupted tooth associated with three variants: central, lateral, and circumferential type.<sup>5</sup>

Histologically, dentigerous cyst is lined with non-keratinized stratified squamous epithelium consisting of mucosebaceous, ciliated, and rarely, sebaceous cells. The epithelial-connective tissue interface is typically flattened, but becomes highly irregular when associated with inflammation.<sup>1</sup>

We hereby present a case of dentigerous cyst associated with unerupted mandibular second molar which is an unusual site for its occurrence in a pediatric patient and discuss its management.

## CASE REPORT

A 12-year-old boy presented to the Department of Oral Medicine and Radiology with a complaint of swelling in the lower right back tooth region of the jaw since 2 months, which was gradually increasing in size. Patient did not report any bleeding or discharge associated with the region. No history of trauma was reported. His past medical history was noncontributory. Extraorally, a diffuse swelling 3 cm × 3 cm in size was present on the right side of the face (Fig. 1). Intraoral examination revealed exophytic proliferative growth 2 cm × 2 cm in size, soft in consistency distal to 46 associated with pus discharge (Fig. 2). The overlying mucosa was inflamed and erythematous. There was both buccal and lingual cortical bone expansion; 46, 85 were slightly displaced lingually. Upon palpation, the swelling was well circumscribed and firm. Lymph nodes were nontender. Panoramic radiograph showed a pericoronal radiolucency of approximately 4 cm × 4 cm in size associated with the crown of unerupted 47 present distal to 46.

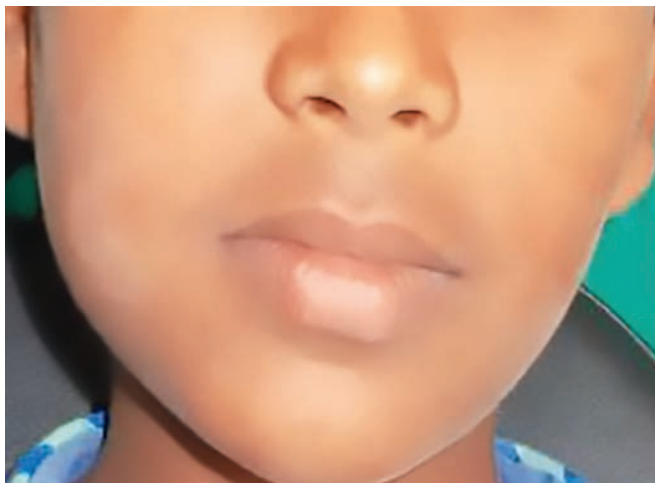<sup>1</sup>Oral and Maxillofacial Radiologist Head, <sup>2</sup>Professor, <sup>3,4</sup>Professor and Head, <sup>5</sup>Assistant Professor

<sup>1</sup>Department of Dental Radiology, City X ray & Scan Clinic New Delhi, India

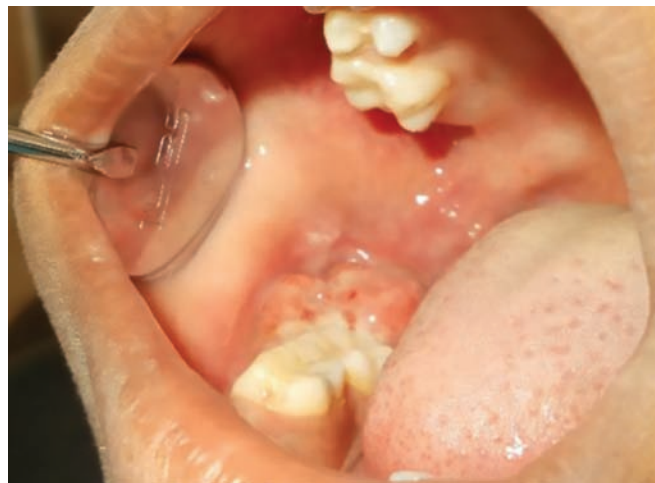<sup>2,3</sup>Department of Oral Medicine and Radiology, Manipal College of Dental Sciences, Manipal, Karnataka, India

<sup>4,5</sup>Department of Oral Surgery, Manipal College of Dental Sciences, Manipal, Karnataka, India

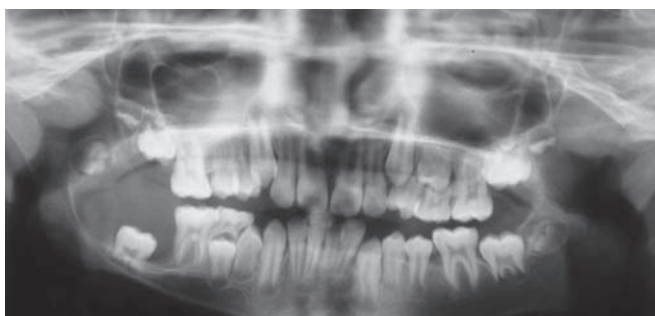**Corresponding Author:** Sakshi Kamra, Oral and Maxillofacial Radiologist Head, Department of Dental Radiology, City X ray & Scan Clinic, New Delhi, India, Phone: +918860426969, e-mail: sakshi\_tis2006@yahoo.co.in



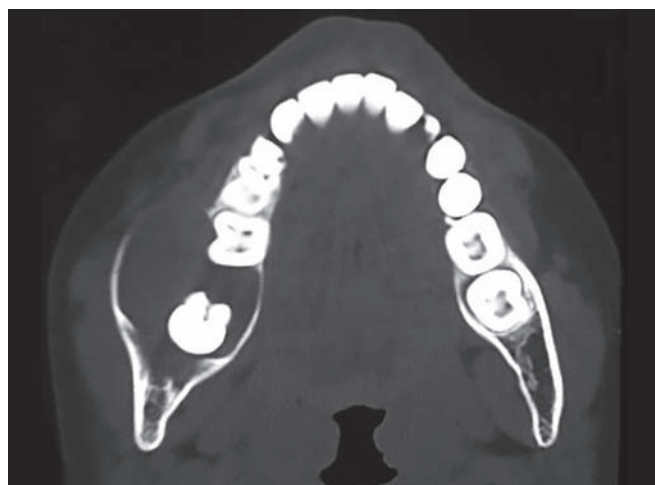**Fig. 1:** Clinical picture of extraoral swelling on the right side of face



**Fig. 2:** Intraoral picture showing swelling distal to 46

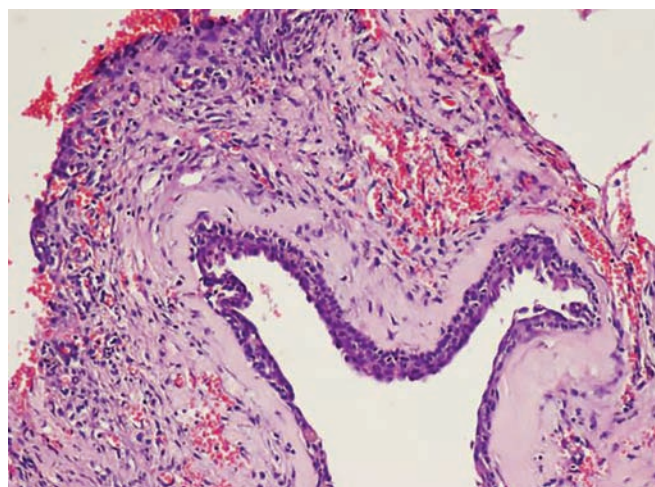


**Fig. 3:** Panoramic radiograph showing a pericoronal radiolucency associated with the crown of unerupted 47



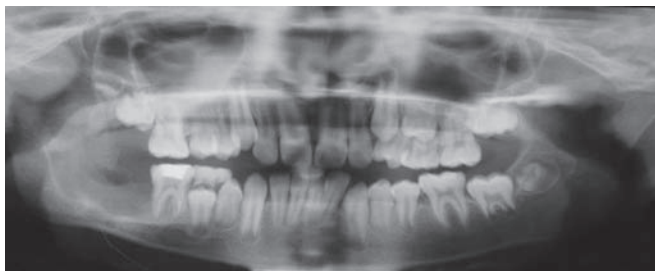
**Fig. 4:** Computed tomography scan showing the buccal and lingual cortical expansion with perforation on the buccal aspect

Showing the anterioposterior and superoinferior extension of the lesion region of 46 to the midpart of ramus of mandible and superoinferiorly from tooth bud of 48 till cemento enamel junction of unerupted 47. It was a unilocular radiolucency with ill-defined septae and corticated borders; 47 was pushed inferiorly and tooth bud 48 was pushed superiorly 2 cm below the sigmoid notch. No other pathological radiolucencies were evident on the contralateral side (Fig. 3). Dentigerous cyst, solid ameloblastoma, intraoral tumor, and soft tissue sarcoma were considered as radiographic provisional diagnosis. Fine needle aspiration cytology was done, which showed inflammatory cells. Computed tomography (CT) scan also showed the buccal and lingual cortical expansion with perforation on the buccal aspect (Fig. 4). Patient underwent scalpel excision under general anesthesia following strict aseptic conditions. Epithelial lining was identified and curetted out. 47 and tooth bud of 48 were extracted. Since the clinical presentation of lesion looked aggressive, Carnoy's solution was applied according to standard protocols. The specimen was sent for histopathology which revealed cystic lumen lined by 2 to 5 layered nonkeratinized stratified squamous epithelium, at places showing hyperplasia. Capsular tissue was dense to delicate, resembling primitive connective tissue stroma



**Fig. 5:** Histopathology section showing cystic lumen lined by 2 to 5 layered nonkeratinized stratified squamous epithelium, showing hyperplasia with focal infiltration of chronic inflammatory cells

with focal infiltration of chronic inflammatory cells; it also shows evidence of vascular spaces, extravasated red blood cells, rosettes, and Rushton bodies (Fig. 5). The



**Fig. 6:** Postoperative panoramic radiograph after 45 days

final diagnosis of dentigerous cyst was made based on clinical, radiographic, and histopathological presentation. Patient is on regular follow-up (Fig. 6). Complete healing is evident of wound and cystic cavity and no recurrence has been reported.

## DISCUSSION

Dentigerous cyst is an odontogenic cyst that develops by accumulation of fluid in the follicular space of unerupted tooth after the crown completion.<sup>5</sup> The occurrence of such a cyst in second permanent molar is infrequent and rare. The commonly suggested pathogenesis is mainly “developmental” that is formed by accumulation of fluid between the reduced enamel epithelium and the enamel or within the enamel organ and eruption of the crown of the permanent tooth into a radicular cyst of its deciduous predecessor. A variation to this concept is occurrence of an “inflammatory” etiology, which states that the inflammation at the apex of a deciduous tooth may lead to the development of an inflammatory follicular cyst. The etiology makes this case special as the likelihood of inflammatory pathogenesis is more but there is no deciduous predecessor for a second permanent molar. Radiographically, it presents with a well-defined unilocular radiolucency associated with the crown of an impacted or unerupted tooth. These cysts can be classified as central, lateral, or circumferential based on their radiographic presentation. Central dentigerous cysts surround the crown of the tooth and are the most common type. The lateral variant grows alongside the root of the tooth and partially surrounds the crown of the tooth. Circumferential dentigerous cysts surround both the crown and root of the affected tooth. Histologically,

dentigerous cysts may or may not display inflammation. If not inflamed, the dentigerous cyst has a relatively loose fibrous connective tissue wall, and the epithelial lining consists of 2 to 4 layers of cuboidal cells. In the inflamed type, the fibrous wall is more collagenized, with varying infiltration of chronic inflammatory cells. The epithelial lining shows hyperplasia, with the development of rete ridges and squamous features. A keratinized surface is sometimes seen.<sup>6</sup>

The differential diagnosis includes normal follicular space, odontogenic keratocyst, ameloblastoma, adenomatoid odontogenic tumor, and ameloblastic fibroma. If the follicular space exceeds 5 mm, a dentigerous cyst is more likely. The diagnosis is based on a combination of radiographic and histologic features.<sup>6</sup>

The usual treatment is careful enucleation of the cyst together with removal of the unerupted or impacted tooth. Chances of recurrence after enucleation are rare.<sup>1</sup> Rarely, an untreated dentigerous cyst undergoes transformation into an ameloblastoma, squamous cell carcinoma, or intraosseous mucoepidermoid carcinoma.<sup>6</sup>

In conclusion, dentigerous cysts can attain considerable size and there is a possible development of tumor from dentigerous cyst lining; often they are asymptomatic and discovered on routine radiographic examination. Hence, early diagnosis and management is of paramount importance in reducing the morbidity.

## REFERENCES

1. Jindal G, Batra H, Kaur S, Vashist D. Dentigerous cyst associated with mandibular 2nd molar: an unusual entity. *J Maxillofac Oral Surg* 2015 Mar;14(Suppl 1):154-157.
2. Nagaveni NB, Umashankara KV, Radhika NB. Inflammatory dentigerous cyst associated with an endodontically treated primary second molar: a case report. *Arch Orofac Sci* 2011; 6(1):27-31.
3. Sands T, Tocchio C. Multiple dentigerous cysts in a child. *Oral Health* 1998 May;88(5):27-29.
4. Shear, M.; Speight, PM. *Cysts of the oral and maxillofacial region*. 4th ed. Johannesburg: Blackwell; 2007.
5. Sharma M, Pardhe ND, Gupta S, Mittal M, Gaikwad A, Pathak M. Inflammatory dentigerous cyst: a rare entity. *J Res Adv Dent* 2014 Jan;3(Suppl 2):4-7.
6. Aziz SR, Pulse C, Dourmas MA, Roser SM. Inferior alveolar nerve paresthesia associated with a mandibular dentigerous cyst. *J Oral Maxillofac Surg* 2002 Apr;60(4):457-459.