

CASE REPORT

Gingival Lichen Planus: A Rare Clinicohistopathologic Report

¹Arati C Koregol, ²Shashikala Dorle, ³Savita Koregol, ⁴Nagaraj B Kalburgi, ⁵Kanniappa S Sireesha, ⁶Apoorva K Wagh

ABSTRACT

Lichen planus is an autoimmune disease that involves the mucosa of the oral cavity. Pathogenesis of oral lichen planus (OLP) is the target of controversy. Thus, the objective of this article is to report a case of OLP in a 62-year-old male patient and to discuss the main aspects of disease in relation to etiopathogenesis and treatment. Biopsy findings showed focal degeneration of basal cell layer with lymphocytic band in the dermis, parakeratotic horny pearls, and atrophic epidermis with effaced rete ridges. Accurate diagnosis is necessary so that the correct treatment can be established.

Keywords: Autoimmune disease, Civatte bodies, Etiopathogenesis, Oral lichen planus, Wickham's striae.

How to cite this article: Koregol AC, Dorle S, Koregol S, Kalburgi NB, Sireesha KS, Wagh AK. Gingival Lichen Planus: A Rare Clinicohistopathologic Report. *J Health Sci Res* 2018;9(1):15-19.

Source of support: Nil

Conflict of interest: None

INTRODUCTION

Oral lichen planus is plagiaristic word from the Greek word "Leichen" meaning tree moss and Latin word "planus" meaning flat/even. Oral lichen planus is a chronic immunologic inflammatory mucocutaneous disorder which was first described by Dr Erasmus Wilson in 1869.¹ Even though mystery surrounds the etiology of OLP, Sugerman et al² considered that specific and nonspecific mechanisms may be involved in the etiopathogenesis of OLP. The specific mechanism involves the auto-cytotoxic CD8+ T-cells directed toward basal keratinocytes triggering apoptosis of the basal cells of the oral epithelium, and the nonspecific mechanism

comprises of degranulation of mast cells and activation of matrix metalloproteinases.^{3,4}

The oral manifestations of lichen planus have been classified into three types as elucidated in the literature as reticular lesions, including white lines, papules, and plaques; atrophic or erythematous lesions; and erosive lesions, including ulcers and bullous lesions. Reticular forms are usually asymptomatic and sometimes discovered during a routine oral clinical examination, the erythematous forms are painful, causing discomfort to the patient.^{5,6} It is universal and is mostly seen in the fifth to sixth decades of life.³ It is frequently seen in the middle-aged people and seldom in children. This lesion has bilateral presentation and is twice more common in women than in men.⁷ It can also affect skin, nails, esophagus, glans penis, and vulva.⁸ Weyl in 1885 initially described the characteristic surface markings on lichen planus as papules, and it was termed as Wickham's striae by Louis Frederic Wickham in 1895.⁹ Lesions are symmetrical, and the frequently involved region is buccal mucosa. Malignant transformation is extremely low.^{9,10}

Aiming to better understand the clinical behavior, the histopathology, and the main treatment for patients with OLP, we propose to present this case report and to discuss their management.

CASE REPORT

A 62-year-old male patient from Bagalkot district, Karnataka, presented to the outpatient department of P.M. Nadagouda Memorial Dental College and Hospital with a chief complaint of burning sensation in the mouth for the past 1 month. The burning sensation was found to aggravate on eating spicy foods. No burning sensation was noted in the eyes or other parts of the body. The medical history and family history was nonsignificant. Patient gave negative history about drug intake. On extraoral examination, no cutaneous lesions were present. No dermal lesions were found elsewhere on the body of the patient.

INTRAORAL EXAMINATION

Multiple bilateral erythematous lesion interspersed with grayish white striae and desquamative areas were seen on both upper and lower buccal gingiva (Fig. 1)

¹Professor, ²Private Practitioner, ³Assistant Professor, ⁴Professor and Head, ^{5,6}Postgraduate Student

^{1,2,4-6}Department of Periodontics, P.M. Nadagouda Memorial Dental College and Hospital, Bagalkot, Karnataka, India

³Department of Dermatology, Al-Ameen Medical College, Bijapur Karnataka, India

Corresponding Author: Arati C Koregol, Professor, Department of Periodontics, P.M. Nadagouda Memorial Dental College and Hospital, Bagalkot, Karnataka, India, e-mail: aratikperio@yahoo.co.in

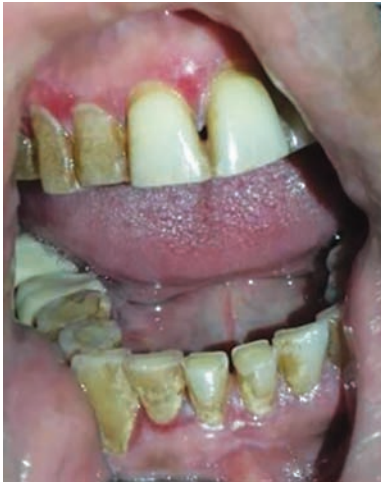

Fig. 1: Lesion on upper and lower buccal gingiva

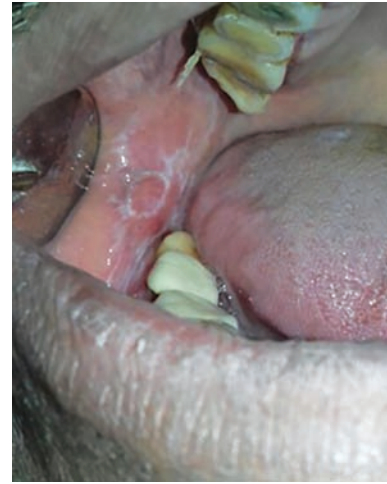

Fig. 2: Lesion on cheek mucosa

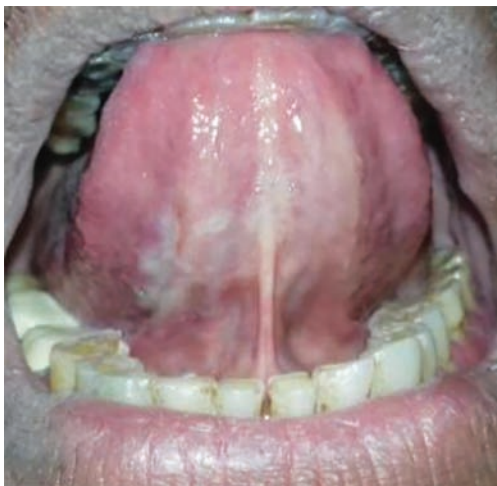

Fig. 3: Lesion on ventral aspect of tongue

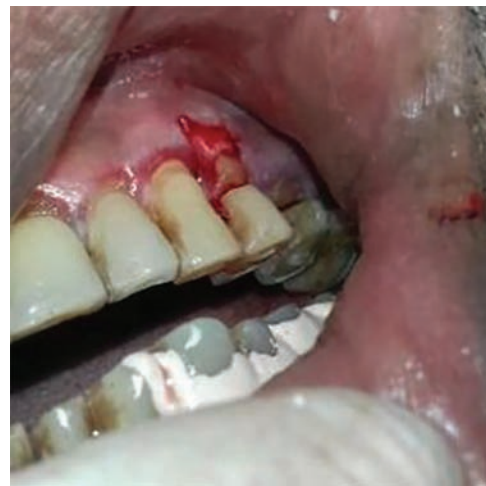

Fig. 4: Biopsy specimen from the buccal side of maxillary premolar region

involving marginal and attached gingiva as well as on the mucosa of the cheek (Fig. 2). The lesion was also seen involving dorsal and ventral aspect of the tongue (Fig. 3). Anteroposteriorly, the lesion extended from occlusal level of molars to the retromolar area. Superoinferiorly, it extended up to the buccal vestibule. The lesion on palpation was tender and nonscrapable. The patient had generalized attrition of teeth and had porcelain fused to ceramic crowns placed in relation to 46 and 47. The patient had cervical abrasions in relation to 21, 23, 24, 25, and 26.

So, based on the history given by the patient and the clinical examination carried out, a provisional diagnosis of lichen planus was made involving left and right buccal mucosa, dorsal and ventral aspect of tongue. The clinical presentations for oral erosive lichen planus, pemphigoid, and pemphigus vulgaris being identical were considered as differential diagnosis, and thus it was decided to carry out biopsy to establish the final diagnosis.

Routine hematological and biochemistry investigations were performed, which yielded negative results.

An incisional biopsy was performed obtaining a wedge of tissue measuring about 0.5×0.5 cm including both the epithelium and connective tissue from the most prominent area, which was the buccal side of the maxillary (Fig. 4) and mandibular first premolar. Coe pak was placed to avoid irritation, aid in healing, and for patient comfort. Care was taken to obtain an elliptical wedge of mucosa which extended beyond the affected area. However, as the lesion was generalized involving both the arches, performing a biopsy was challenging, with the epithelium stripping away from the underlying connective tissue. Further, the specimen was sent to the laboratory for examination. As the patient was unable to afford the immunofluorescence test, only histopathologic assessment was performed.

HISTOPATHOLOGICAL REPORT

Macroscopic Features

The histopathological report revealed two bits of tissues in formalin measuring 0.5×0.5 cm which were brownish

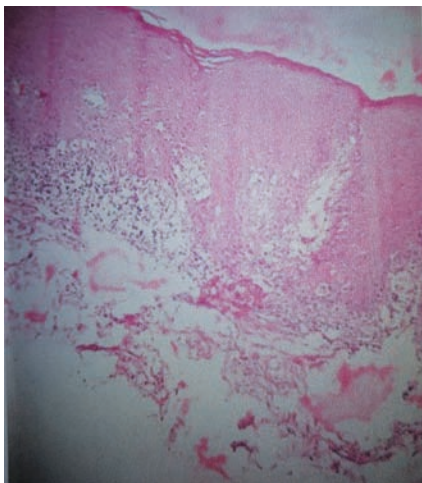


Fig. 5: Histopathology of the lesion—hematoxylin and eosin-stained specimen shows stratified squamous epithelium overlying fibrocellular connective tissue. Sparse to moderate band like inflammatory infiltrate just beneath the epithelium chiefly composed of lymphocytes and occasionally plasma cells were seen. Blood capillaries are also evident

white in color, soft and firm in consistency, and irregular in shape.

Microscopic Features

Histopathology revealed the section showing stratified squamous epithelium with areas of ortho- or parakeratosis, acanthosis, spongiosis, and hydropic degeneration of the basement layer which was separated from fibrocellular connective tissue. Sparse to moderate subepithelial band like inflammatory cell infiltrate chiefly is composed of lymphocytes and occasional plasma cells and arranged in a band-like pattern. Blood capillaries were also evident (Fig. 5). Based on clinical, radiographic, and histopathological findings, the final diagnosis was of reticular lichen planus on buccal mucosa and ventral surface of tongue, whereas atrophic lichen planus on gingiva was arrived.

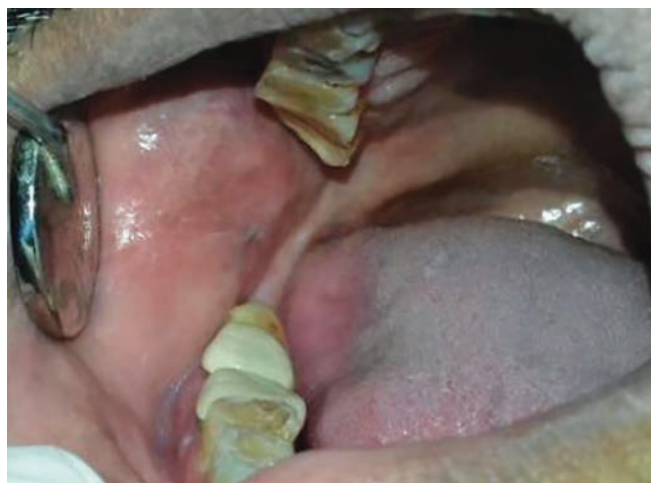

Fig. 6: Regression of lesion on cheek mucosa

The following medications were prescribed. Initially, topical application of corticosteroids were prescribed but as the patient was unresponsive to topical steroids, systemic treatment including Prednisolone (Omnacortil) tablets were prescribed for 30 days with the tapering dose of 20 mg OD for first 10 days and 10 mg OD for next 10 days and 5 mg OD for last 10 days along with systemic application of clobetasol for symptomatic relief. Further, the patient was recalled for evaluation of oral lesions. A recall after 1 month showed regression of lesion. Healing was satisfactory at all the sites (Figs 6 to 9).

DISCUSSION

Lichen planus is a chronic autoimmune disease with an unknown etiology that is marked by invasion of lymphocytic infiltrate within the epithelial tissue inducing epithelial cell apoptosis and chronic inflammation.¹¹ The patient in this case report was a male of 62 years, which falls into the age range in which lichen planus is most commonly reported. The precise etiology of this condition is unknown, but, in their review, Ismail et al¹² reported

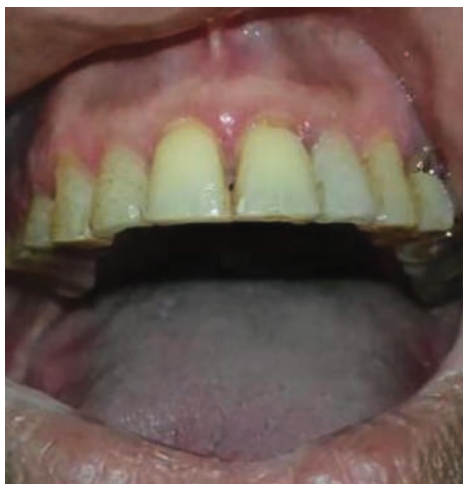

Fig. 7: Regression of lesion on gingiva

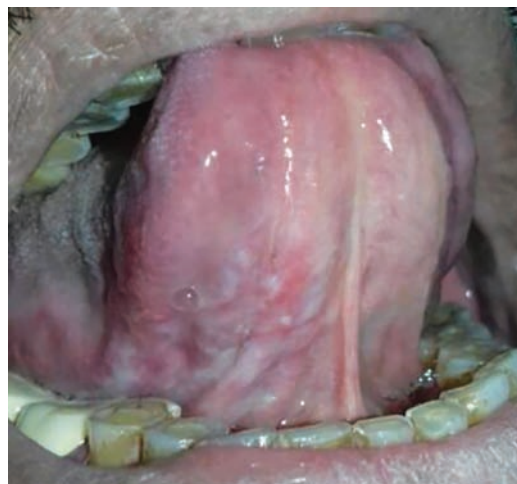

Fig. 8: Regression of the lesion on ventral aspect of tongue

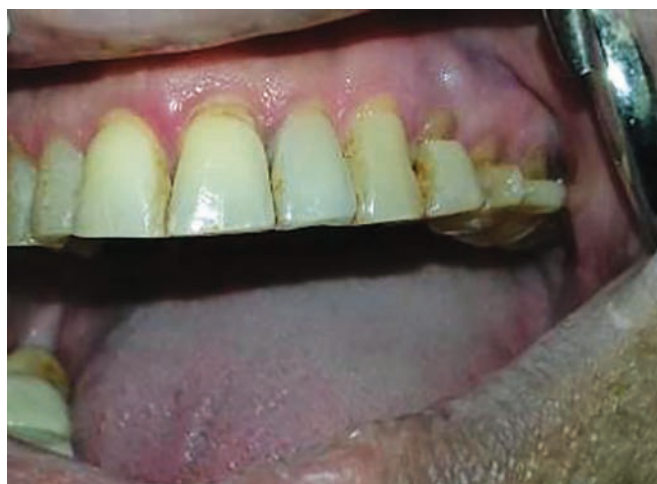

Fig. 9: Regression of lesion on buccal aspect of gingiva

the causative and exacerbating factors for OLP and lichenoid reactions, such as drugs like antimalarial, diuretics, antiretroviral, dental materials like dental amalgam, composite, resin-based materials, metals, chronic liver disease, hepatitis C virus, genetics, and tobacco chewing. In our case, there was no such situation that could have provoked OLP reactions.

There exist endogenous or exogenous factors that initiate cell-mediated immunity in individuals genetically predisposed to the disease which plays a crucial role in the pathogenesis of the disease. Tissue destruction occurs on activation of T lymphocytes and increased production of cytokines that result in increased expression of the intercellular adhesion molecule and the major histocompatibility complex type II by keratinocytes. This process results in immune vacuolar degeneration, lysis of cells in the basal layer, and, finally, dissolution of the cells of the basal layer.¹³

One of the most frequent causes of acute exacerbation of the disease is stress.^{13,14} Therefore, the education of patients with OLP can minimize their anxiety.¹³ Reticular, papular, plaque-like, erosive, atrophic, and bullous forms are the six clinical forms of OLP that have been described.^{12,13} A more simple clinical classification consists of three types of lesions: Reticulated lesions, atrophic or erythematous lesions, and erosive lesions.¹³ The lesions may occur following the gingival outline, and hyperkeratotic radiating striae can be found at the periphery of the erosive region. When erosive OLP involves the attached gingival tissue, it is called desquamative gingivitis.

Clinically, the lesions in the oral cavity are generally multiple and bilateral.^{11,12,14} OLP can involve anywhere in the oral cavity; however, it is most prevalent in the buccal mucosa, gingiva, and tongue.^{12,14} Whitish striae in a reticulated pattern is considered to be the most common clinical presentation.^{11,14}

Cutaneous form of lichen planus shows typical skin lesions that are described as purplish, polygonal, planar,

pruritic papules, and plaques.¹⁵ These dermal lesions of lichen planus are most commonly seen on the flexor surfaces of the legs and arms, especially the wrists.¹⁶ If the patient is found to have skin manifestations, referral to a dermatologist is needed for further evaluation and treatment of the skin lesions.¹⁵

Differential diagnoses include lichenoid eruptions associated with medications, lichenoid lesions associated with contact with restorative materials, leukoplakia, lupus erythematosus and graft *vs* host disease, and chronic ulcerative stomatitis.¹⁵

The diagnosis of OLP is based on clinical and histopathological findings. Histopathologically, classic features include the presence of a band of lymphocytic infiltrate in the subepithelial region, liquefactive degeneration of the basal layer, Civatte bodies, which are the numerous eosinophilic colloid bodies along the epithelial interface with variable degrees of focal ortho- or parakeratosis and irregular acanthosis.^{13,14} The patient showed generalized attrition of teeth. Attrition *per se* has no role in the etiology of lichen planus, but role of stress in generalized attrition as well as lichen planus cannot be denied.

According to Ismail et al,¹² good oral hygiene maintenance can enhance healing and lessen symptoms and exacerbating factors. Various treatment modalities, such as surgical management, including cryosurgery and carbon dioxide laser, has been proposed for OLP lesions, but surgical excision is not recommended as the first-choice treatment due to the inflammatory condition, which can recur.

The miserable complication of OLP is the development of squamous cell carcinoma. Epithelial dysplasia is considered to be the risk of malignancy of the lesion. Malignant potential of erosive lichen planus is more when compared with other types of lichen planus.

Management of OLP

Treatment of OLP depends on symptoms, the extent of oral and extraoral clinical involvement, medical history, and other factors. The objective of treating lichen planus is to control the different outbreaks that exist, given that the lesions are usually not completely cured. Such treatment differs according to the clinical form present in each case. Generally, the reticular forms are not treated, whereas the atrophic and erosive forms are primarily treated with topical corticosteroids, such as high-potency 0.05% fluocinolone ointment or 0.05% clobetasol propionate with 100,000 IU/mL of nystatin in Orabase.¹⁷ In cases where such treatment proves to be inefficient, perilesional infiltrations of corticosteroids, such as 10 to 20 mg triamcinolone acetonide or short-term regimens of 40 mg Prednisolone daily for 5 days followed by 10 to

20 mg daily for additional 2 weeks may be prescribed.¹⁸ These are only used systemically in those patients for whom all the previous courses of therapy have failed.¹⁹ An elixir of dexamethasone, clobetasol, and triamcinolone can be used in patients with oral involvement.²⁰

CONCLUSION

Oral lichen planus is the most frequent and very common oral dermatosis encountered by dental practitioners. It is imperative that the lesion be identified precisely, and proper treatment be administered at the earliest. A proper perceptive of the pathogenesis of the disease becomes important for providing the right treatment.

CLINICAL SIGNIFICANCE

Lichen planus is an autoimmune mucocutaneous disease that causes pain and discomfort for the patient and does not have an effective treatment unless a suitable protocol of correct identification of lesions by biopsy and histopathological analysis and the use of anti-inflammatory drugs is being followed. Regular clinical monitoring of lesions should be carried out for an effective treatment outcome.

REFERENCES

- Gorouhi F, Davari P, Fazel N. Cutaneous and mucosal lichen planus: a comprehensive review of clinical subtypes, risk factors, diagnosis, and prognosis. *Sci World J* 2014 Jan 30;2014:742826.
- Sugerman PB, Savage NW, Walsh LJ, Zhao ZZ, Zhou XJ, Khan A, Seymour GJ, Bigby M. The pathogenesis of oral lichen planus. *Crit Rev Oral Biol Med* 2002;13(4):350-365.
- Patil A, Prasad S, Ashok L, Sujatha GP. Oral bullous lichen planus: case report and review of management. *Contemp Clin Dent* 2012 Jul;3(3):344-348.
- Eversole LR. Immunopathogenesis of oral lichen planus and recurrent aphthous stomatitis. *Semin Cutan Med Surg* 1997 Dec;16(4):284-294.
- Bornstein MM, Hakimi B, Persson GR. Microbiological findings in subjects with asymptomatic oral lichen planus: a cross-sectional comparative study. *J Periodontol* 2008 Dec;79(12):2347-2355.
- McCartan BE, Healy CM. The reported prevalence of oral lichen planus: a review and critique. *J Oral Pathol Med* 2008 Sep;37(8):447-453.
- Cheng S, Kirtschig G, Cooper S, Thornhill M, Leonardi-Bee J, Murphy R. Interventions for erosive lichen planus affecting mucosal sites. *Cochrane Database Syst Rev* 2012 Feb 15;(2):CD008092.
- Neville, BW.; Damm, DD.; Allen, CM., et al. Multiple chapters. In oral and Maxillofacial pathology. Philadelphia: WB Saunders; 2009.
- Carrozzo M. How common is oral lichen planus? *Evid Based Dent* 2008;9(4):112-113.
- Wilson E. On lichen planus. *J Cutan Med Dis Skin* 1869;3: 117-132.
- Scully C, Carrozzo M. Oral mucosal disease: Lichen planus. *Br J Oral Maxillofac Surg* 2008 Jan;46(1):15-21.
- Ismail SB, Kumar SK, Zain RB. Oral lichen planus and lichenoid reactions: etiopathogenesis, diagnosis, management and malignant transformation. *J Oral Sci* 2007 Jun;49(2): 89-106.
- Einsen D. The clinical features, malignant potential, and systemic associations of oral lichen planus: a study of 723 patients. *J Am Acad Dermatol* 2002 Feb;46(2):207-214.
- Epstein JB, Wan LS, Gorsky M, Zhang L. Oral lichen planus: progress in understanding its malignant potential and the implications for clinical management. *Oral Surg Oral Med Oral Pathol Oral Radiol Endod* 2003 Jul;96(1):32-37.
- Greenberg, MS.; Glick, M. *Burket's Oral medicine: Red and White lesions of the oral mucosa*. 10th ed. Elsevier; 2003.
- Edwards PC, Kelsch R. Oral lichen planus: clinical presentation and management. *J Can Dent Assoc* 2002 Sep;68(8): 494-499.
- Gonzalez-Moles MA, Ruiz-Avila I, Rodriguez-Archilla A, Morales-Garcia P, Mesa-Aguado F, Bascones-Martinez A, Bravo M. Treatment of severe erosive gingival lesions by topical application of clobetasol propionate in customs tray. *Oral Surg Oral Med Oral Pathol Oral Radiol Endod* 2003 Jun;95(6):688-692.
- Nisengard RJ, Levine R. Diagnosis and management of desquamative gingivitis. *Periodont Insights* 1995;2:4.
- Eisen D, Carrozzo M, Bagan Sebastian JV, Thongprasom K. Number V Oral lichen planus: clinical features and management. *Oral Dis* 2005 Nov;11(6):338-349.
- Sousa FA, Rosa LE. Oral lichen planus: clinical and histopathological considerations. *Braz J Otorhinolaryngol* 2008 Mar-Apr;74(2):284-292.