

## CASE REPORT

# Management of Primary Hyperhidrosis with Sympathetic Block

<sup>1</sup>Nitin A Menon, <sup>2</sup>Dwarkadas K Baheti, <sup>3</sup>Nitin N Dange

## ABSTRACT

Hyperhidrosis is an unusual condition characterized by excessive sweating, which results in social embarrassment and work place impairment. Although a number of treatment options are available, the use of sympathetic block in certain patients is an important tool as a part of multimodal approach in the management of this condition.

**Keywords:** Epidural catheter, Hyperhidrosis, Sympathetic block.

**How to cite this article:** Menon NA, Baheti DK, Dange NN. Management of Primary Hyperhidrosis with Sympathetic Block. *Indian J Phy Med Rehab* 2017;28(4):140-142.

**Source of support:** Nil

**Conflict of interest:** None

## INTRODUCTION

Hyperhidrosis is a condition characterized by sweating in excess of what is needed for maintenance of physiologic homeostasis. The prevalence of this condition worldwide is about 3%, whereas in India, it is reported to be higher, particularly in summer.<sup>1</sup>

It is of two main types: Primary and Secondary.

Primary is seen in adolescents and young adults and half of these patients report a similar condition in a family member. The most common sites of excessive sweating are axilla, soles, palms, and face in that order. It is accompanied by a variety of psychological impairments, most common being depression and work place limitations.<sup>2</sup>

Secondary is due to medical conditions like drug intake, endocrinopathies, malignancies, or certain neurological diseases.<sup>3</sup>

The treatment options are topical applications, oral anticholinergic medications, local botulinum toxin

injections, axillary curettage, liposuction, and sympatholytic techniques, which can be either neurolytic sympathetic block or surgical sympathectomy.<sup>4</sup>

## CASE REPORT

A 23-year-old man, working as a clerk in the army, visited our pain clinic with a complaint of profuse sweating in both palms and soles resulting in disturbed working conditions, such as writing and embarrassment during social interactions. These symptoms were absent during sleep and he had no family history of similar complaints. The clinical examination and investigations, such as ultrasound of abdomen, blood work-up including thyroid studies, serum cortisol levels, and blood sugar levels were all normal. He was put on low dose anti-cholinergic medications with minimum or no relief of symptoms. After a detailed discussion of pros and cons and obtaining informed written consent, he was posted for diagnostic lumbar epidural followed by sympathetic block.

An epidural catheter was inserted at L3 level with fluoroscopic control and infusion of injection Ropivacaine (0.2%) at three milliliters (mL) per hour was started to achieve temporary sympathetic block. After 4 to 5 hours of infusion, the sweating reduced considerably; however, it was noticed that the patient had difficulty in dorsiflexion of left foot. The right foot was normal. It was decided to reduce the rate of infusion to 2 mL per hour. Within few hours of reduced rate of infusion, the difficulty in dorsiflexion in left foot got corrected and he was encouraged to ambulate and perform his usual activities.

The sweating in hands and legs decreased from a patient-reported score of 100/100 pre-procedure to 25/100 after insertion of epidural catheter. This was suggestive of successful sympathetic block. The complete catheter was removed after 48 hours and a drug wash-out period of 36 hours was given. Taking his age into consideration and effective diagnostic lumbar sympathetic block, neurolytic lumbar sympathetic block of left side and local anesthetic right stellate ganglion block were planned.

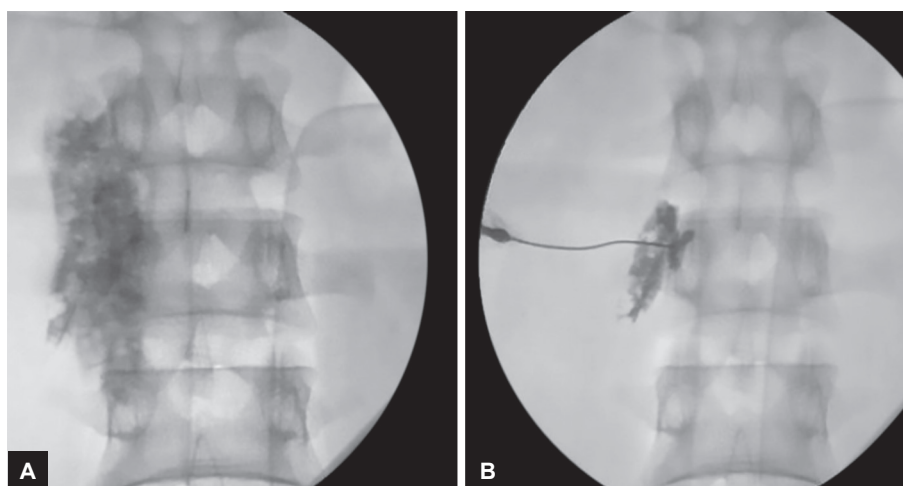
With anesthetist stand-by, monitoring of vital signs and under fluoroscopy, neurolytic left lumbar sympathetic block (Fig. 1) and right local anesthetic stellate ganglion block (Fig. 2) were performed. The neurolysis was done with 6 mL of Phenol (6%) solution in glycerol

<sup>1</sup>Fellow, <sup>2,3</sup>Consultant

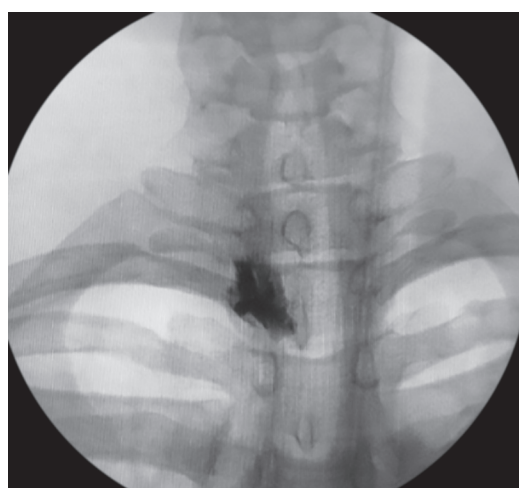<sup>1,2</sup>Department of Chronic Pain, Lilavati Hospital & Research Centre, Mumbai, Maharashtra, India

<sup>3</sup>Department of Neurosurgery, Lilavati Hospital & Research Centre, Mumbai, Maharashtra, India

**Corresponding Author:** Nitin A Menon, Fellow, Department of Chronic Pain, Lilavati Hospital & Research Centre, Mumbai Maharashtra, India, Phone: +912226568000, e-mail: nitinam@gmail.com



**Figs 1A and B:** Lumbar sympathetic block—dye spread and neurolytic drug spread



**Fig. 2:** Stellate ganglion block

and equal volumes of 0.5% injection Bupivacaine. This was immediately followed by an injection of a mixture of injection Lignocaine 1% (5 mL) plus injection Bupivacaine 0.25% (5 mL) into right stellate ganglion. The patient had signs and symptoms of Horner's syndrome, such as pin point right pupil and hoarseness of voice for a few hours. Otherwise, both the procedures were uneventful.

He was counselled regarding the nature of the condition, its management, and stress reduction. The patient was discharged two days after the performance of neurolytic block with sweating scores of 25/100. He was advised to continue oral anti cholinergic agent—1 mg of oral Glycopyrrolate and 10 mg Amitriptyline per day.

## DISCUSSION

This patient can be labelled as primary hyperhidrosis (palmo-plantar) because of young age of onset, focal symptoms, no sweating during sleep, and absence of any systemic medical condition. In some cases, the small areas of focal hyperhidrosis can be managed by initially

applying starch-iodine to the site of increased sweating, which stains purple followed by botulinum toxin injection to such stained areas.<sup>5</sup> However, the cost of the procedure may be a limiting factor in many patients as in this case. The other options are radio frequency ablation of sympathetic ganglion and endoscopic surgical sympathectomy.<sup>6,7</sup> The reported rate of patient satisfaction for surgical procedures is 65%.<sup>8</sup> The side effects include compensatory and gustatory sweating, Horner's Syndrome, and neuralgia, which, in some cases, may be worse than the earlier problem.<sup>9</sup>

Sympathetic blocks can be used when focal hyperhidrosis affects a relatively large area and the patient does not wish to undergo surgical treatment. It has the advantage of being relatively safe with minor side effects, such as bleeding, groin pain (due to genitofemoral neuropathy), and potential risk of damaging vital neural or vascular structures.<sup>10</sup> Kim et al,<sup>11</sup> in a study of 69 patients who underwent lumbar chemical sympatholytic block for plantar hyperhidrosis, reported that 56 patients (81.1%) were partially or fully satisfied with the results. Dondelinger and Kurtziel<sup>12</sup> performed T3 level sympathetic neurolytic block on 12 patients using computed tomography guidance for palmar hyperhidrosis and reported results comparable to those achieved by surgery.

Bilateral sympatholysis or sympathectomy is not advisable in one sitting due to risk of severe hypotension and loss of sexual function as observed by Quayle.<sup>13</sup> We feel, in this patient, the oral medications which were not very useful earlier were probably effective now due to the additive effect of sympatholytic block.

## CONCLUSION

Hyperhidrosis is a less known condition which causes psychological and social impairment. Sympathetic blockade is safe, with fewer side effects as compared to

surgery, cost-effective, and may be an additional option of treatment along with multi-disciplinary approach.

### What was Known

Sympathetic blocks help in hyperhidrosis.

### What is New

- Sympathetic neurolysis can be used for primary hyperhidrosis affecting relatively larger body area.
- Epidural infusion prior to definitive block may help in deciding the usefulness of neurolytic procedure.
- Sympatholysis might improve the efficacy of drug treatment.

### REFERENCES

1. Muthusamy A, Gajendran R, Ponnas S, Thangavel D, Rangan V. A study on the impact of hyperhidrosis on the quality of life among college students. *J Clin Diagn Res* 2016 Jun;10(6):CC08-CC10.
2. Lakraj AAD, Moghimi N, Jabbari B. Hyperhidrosis: anatomy, pathophysiology and treatment with emphasis on the role of botulinum toxins. *Toxins* 2013 Apr;5(4):821-840.
3. Haider A, Solish N. Hyperhidrosis: an approach to diagnosis and management. *Dermatol Nurs* 2004 Dec;16(6):515-517.
4. Stashak AB, Brewer JD. Management of hyperhidrosis. *Clin Cosmet Investig Dermatol* 2014;7:285-299.
5. Haider A, Solish N. Focal hyperhidrosis: diagnosis and management. *Can Med Assoc J* 2005 Jan;172(1):69-75.
6. Lee JY, Sim WS, Kang RA, Lee EK, Yang JY, Kim DY. Lumbar sympathetic pulsed radiofrequency treatment for primary erythromelalgia: a case report. *Pediatr Dermatol* 2017 Jan/Feb;34(1):e47-e50.
7. Cerfolio RJ, DeCampos JRM, Bryant AS, Connery CP, Miller DL, McKenna RJ, Krasna MJ. The society of thoracic surgeons expert consensus for the surgical treatment of hyperhidrosis. *Ann Thoracic Surg* 2011 May;91(5):1642-1648.
8. Rajesh YS, Pratap CP, Woodyer AB. Thoracoscopic sympathectomy for palmar hyperhidrosis and Raynaud's phenomenon of the upper limb and excessive facial blushing: a five year experience. *Postgrad Med J* 2002 Nov;78(925):682-684.
9. Mahendiran S, Burkhart CN, Burkhart CG. Hyperhidrosis: a review of a medical condition. *Open Dermatol J* 2009;3:195-197.
10. Menon R, Swanepoel A. Sympathetic blocks. Continuing education in anaesthesia. *Critical Care Pain* 2010 Jun;10(3):88-92.
11. Kim WO, Yoon KB, Kil HK, Yoon DM. Chemical lumbar sympathetic block in the treatment of plantar hyperhidrosis: a study of 69 patients. *Dermatol Surg* 2008 Oct;34(10):1340-1345.
12. Dondelinger RF, Kurdziel JC. Percutaneous phenol block of the upper thoracic sympathetic chain with computed tomography guidance. *Acta Radiol* 1987;28(5):511-515.
13. Quayle JB. Sexual function after bilateral lumbar sympathectomy and aorto-iliac by-pass surgery. *J Cardiovasc Surg* 1980 Mar-Apr;21(2):215-218.