

Comparative Study of Electrophysiological Improvement in Carpal Tunnel Syndrome by Local Infiltration of Steroid vs Ultrasonic Therapy

¹Mohit Kataruka, ²Rajesh Pramanik, ³Rathindranath Haldar

ABSTRACT

Introduction: Carpal Tunnel Syndrome (CTS) was effectively treated by lots of conservative management including splints, exercise, different types of heat modality like Ultrasound treatment (UST), steroid, etc. This is our humble attempt to explore and find out the electrophysiological improvement pattern after treatment with ultrasonic therapy and methylprednisolone injection in CTS. This analytical study was conducted at the Department of Physical Medicine and Rehabilitation (PMR), IPGME&R, SSKM Hospital, Kolkata from January 15, 2012 to July 15, 2013.

Materials and methods: After getting the institutional ethical committee clearance, patients with symptoms of nerve compression at wrist were included in the study group according to the inclusion and exclusion criteria and randomly divided into two groups. Group I received UST for 15 minutes per session for 15 days to the palmer carpal tunnel area at a frequency of 1 MHz and intensity of 1.0 W/cm², pulsed mode, with a transducer of 5 cm², and group II received 40 mg methylprednisolone injection. The patients were examined after intervals of 2, 4 and 8 weeks post intervention.

Results: The results of our study suggest that there was a marked improvement for all the clinical and electrophysiological parameters in both the groups, but there is no statistically significant difference between the groups.

Conclusion: Ultrasound treatment and intralesional steroid injection are both effective methods of treatment for CTS with clinical and electrophysiological improvement. This is one of the effective modalities of treatment for CTS.

Keywords: Carpal tunnel syndrome, Methyl prednisolone, Nerve conduction study, Ultrasound treatment.

How to cite this article: Kataruka M, Pramanik R, Haldar R. Comparative Study of Electrophysiological Improvement in Carpal Tunnel Syndrome by Local Infiltration of Steroid vs Ultrasonic Therapy. Indian J Phy Med Rehab 2017;28(4):122-129.

Source of support: Nil

Conflict of interest: None

¹Major, ²Associate Professor, ³Professor and Head

¹Department of Sports Medicine, Military Hospital, Khadakwasla NDA, Pune, Maharashtra, India

^{2,3}Department of Physical Medicine and Rehabilitation, Institute of Post Graduate Medical Education & Research, Kolkata, West Bengal, India

Corresponding Author: Rajesh Pramanik, Associate Professor Department of Physical Medicine and Rehabilitation, Institute of Post Graduate Medical Education & Research, Kolkata, West Bengal, India, e-mail: rpramanik2000@yahoo.com

INTRODUCTION

Carpal tunnel syndrome is the most common entrapment neuropathy in the upper extremity usually presents with numbness, parenthesis, weakness, and atrophy of intrinsic hand muscles. Over the years, CTS has been effectively treated by lots of conservative management which includes splints, exercise, different types of heat modality like UST, etc. Local infiltration of methyl-prednisolone is a very quick and easy but effective treatment option being practiced for the last few decades. Splinting the wrist is the most common conservative intervention^{1,2} and may be recommended in conjunction with tendon and nerve gliding exercises.^{3,4} Anatomic studies demonstrate that pressure in the carpal tunnel is at its lowest when the wrist is placed in a neutral position, and is at its highest when the wrist moves into flexion and extension.⁵ The wrist should be splinted in 0 to 5° of extension.⁶ Rozmaryn et al⁴ found that subjects who performed tendon and nerve gliding exercises had fewer surgeries than the subjects who did not perform the exercises.⁷ Ultrasound treatment within the range of 0.5 to 2.0 w/cm² may accelerate the healing process in the damaged tissue; in the early stage of healing, ultrasound may decrease the edema and increase blood flow and delivery of oxygen. Further, it may increase collagen deposition and remodeling.^{8,9}

With the invention of newer instrument like electrophysiological studies, an early diagnosis of CTS is relatively easy with more sensitivity and specificity. There is paucity of literature regarding the electrophysiological improvement pattern due to treatment of deep heat like UST etc., and local infiltration of steroid. There are little evidences available comparing the clinical symptomatology and functional improvement pattern in this clinical entity. This is our humble attempt to explore, to find out, and to compare the electrophysiological improvement pattern after treatment with local infiltration of steroid and ultrasonic therapy in CTS.

Aims and objectives of my study were to compare the efficacy of infiltration of steroid *vs* ultrasonic therapy in CTS by an electrophysiological pattern.

MATERIALS AND METHODS

This randomized open label parallel group control study was conducted at the Department of Physical

Medicine and Rehabilitation (PMR), IPGME&R, SSKM Hospital, Kolkata from January 15, 2012 to July 15, 2013. After getting the institutional ethical committee clearance, 70 patients with symptoms of nerve compression at wrist were included in the study group according to the following inclusion and exclusion criteria.

Inclusion Criteria

- Unilateral CTS for more than 3 months
- Age between 18 and 65 years

Exclusion Criteria

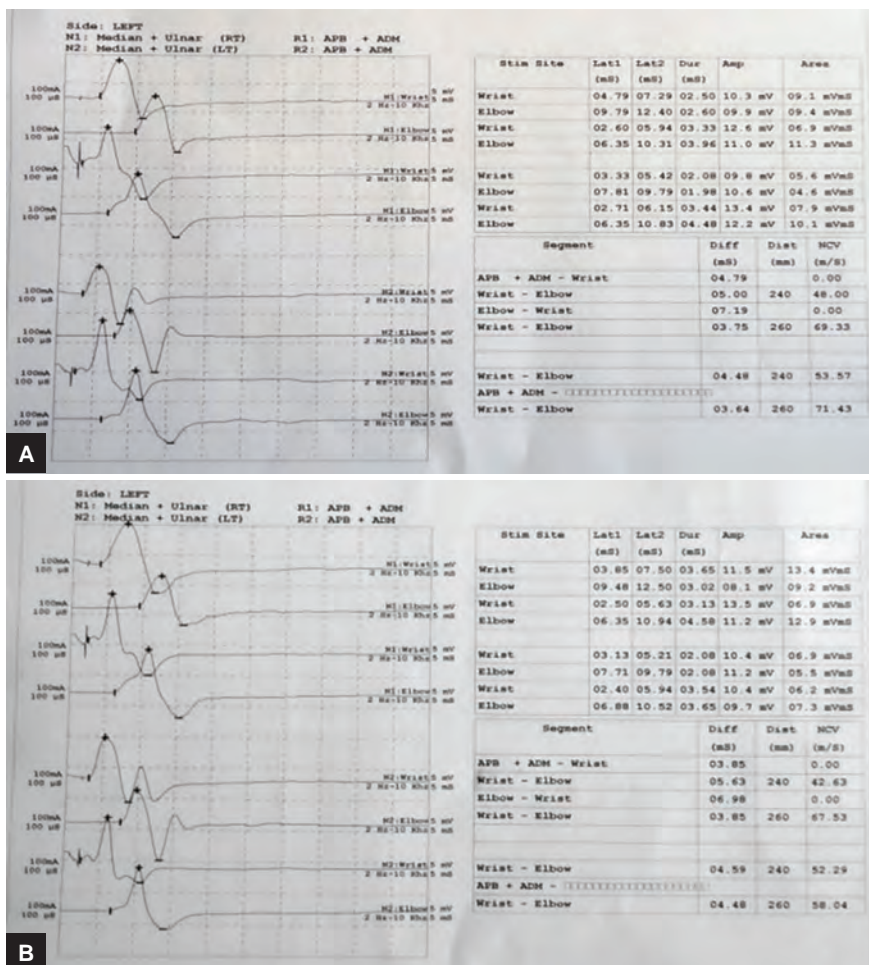
- Bilateral CTS
- Age less than 18 years and more than 65 years
- Diabetes, hypothyroidism, acromegaly, rheumatoid arthritis, pregnancy
- Patients using oral contraceptive pills
- H/O trauma
- Constant numbness, loss of sensation, or thenar atrophy lasting longer than 1 year
- Patients with bleeding disorder
- Contraindications for steroid(hypersensitivity to steroid, local skin infection) and ultra sonic therapy

METHOD

After getting the ethical committee clearance, patients who fulfilled the above criteria for selection were selected. After taking consent from the patients, the patients were randomly divided into two groups—groups I and II. Then, the prefixed proforma was filled up by taking detailed history, clinical examination, and electrophysiological examination (Fig. 1). Both the groups were educated regarding management protocol, proper (Figs 2 and 3) positioning of hand, advice to do nerve gliding exercise and advice to use orthosis (Fig. 4), vitamin B12 (1500 mg) for 3 weeks, and paracetamol tablet 500 mg twice daily for 7 days. Apart from the above, group I received UST (Fig. 5) and group II received steroid injection (Fig. 6). The patients were examined after intervals of 2, 4, and 8 week post intervention.

Study Tools

- Nerve conduction study machine (RMS EMG EP MK II)
- Ultrasonic therapy machine
- Injection methylprednisolone



Figs 1A and B: NCS of one of the patients at different time intervals




Fig. 2: Procedures of median nerve-gliding exercise

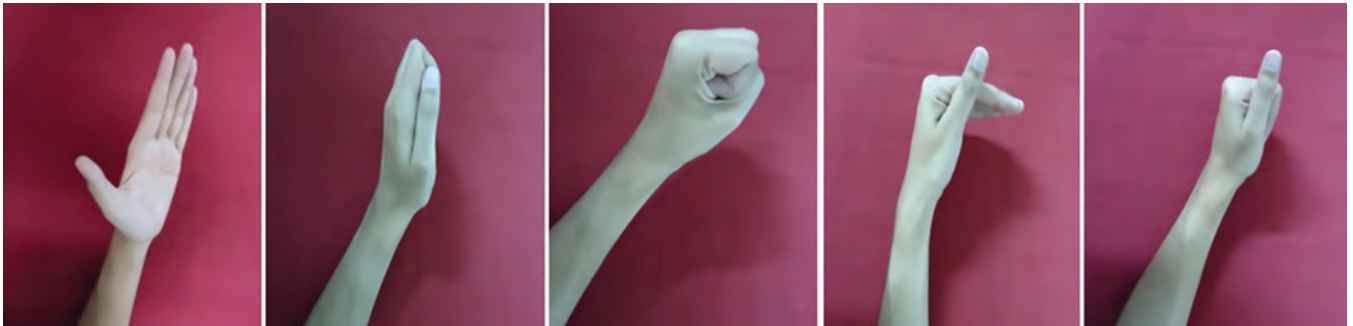
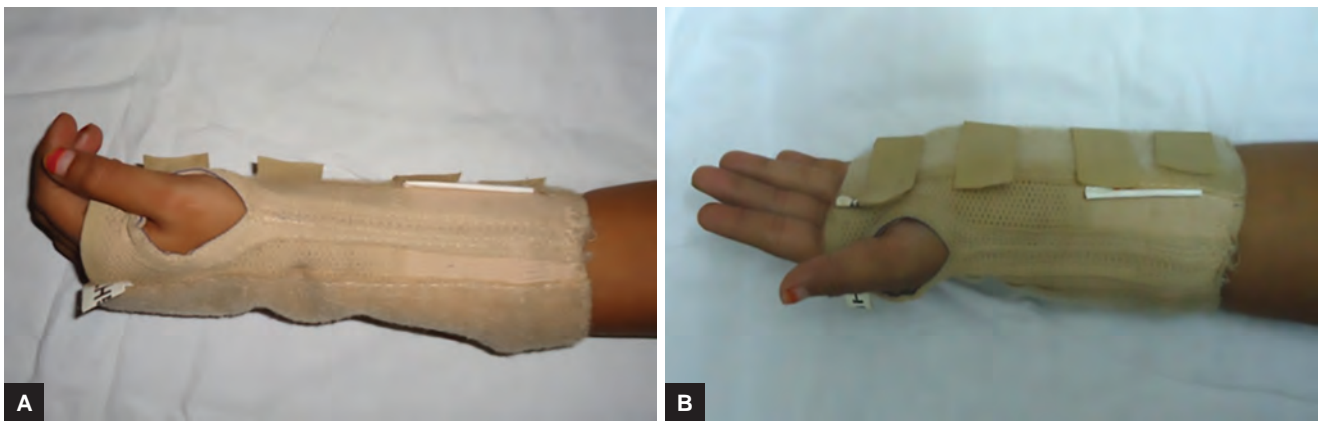


Fig. 3: Procedures of median tendon-gliding exercise



Figs 4A and B: Static wrist hand orthosis used in our patients

In the nerve conduction study (NCS) machine, we recorded the following parameters:

- Motor nerve conduction study—median and ulnar amplitude, velocity, and their latencies.
- Sensory nerve conduction study—median and ulnar amplitude and their latencies.

Exercise

- During the median nerve-gliding exercise, the median nerve was mobilized by putting the hand and wrist in six different positions.¹⁰
- During tendon-gliding exercises, the fingers were placed in five discrete positions. These were straight, hook, fist, table top, and straight fist.¹⁰


During these exercises, the neck and the shoulder were in a neutral position, and the elbow was in supination and 90° of flexion. Each position was maintained for 5 seconds. The exercises were applied as five sessions daily. Each exercise was repeated 10 times at each session.^{11,12}

ORTHOSIS

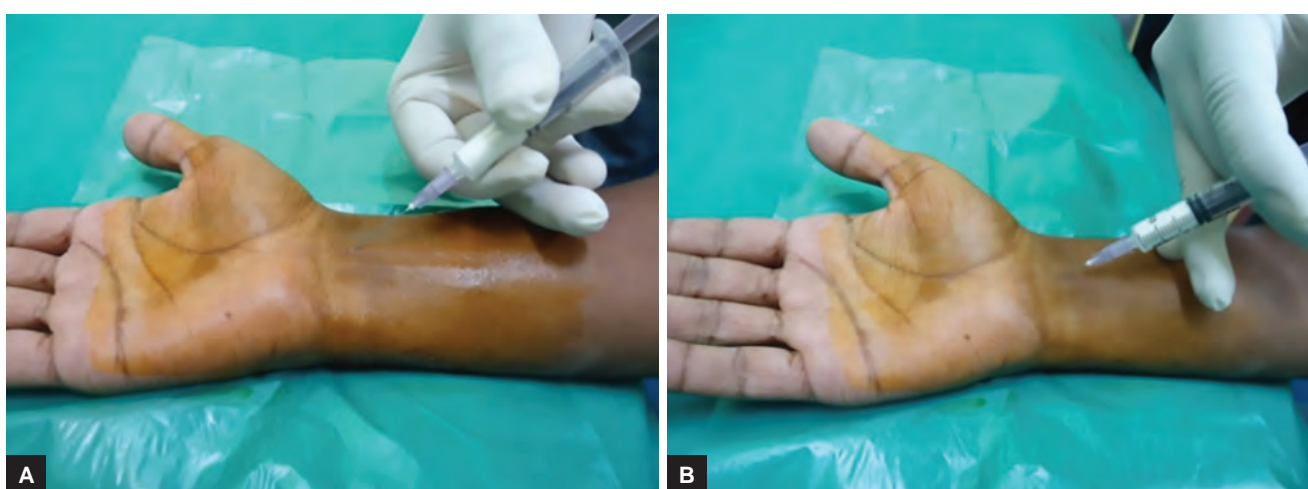All patients were advised to use static wrist hand orthosis as night splint, keeping the wrist in 0 to 5° of extension.¹³

Steroid Injection

After informed consent was obtained, the carpal tunnel was injected with 40 mg methylprednisolone plus 0.5 mL



Figs 5A and B: The procedure of UST in CTS patient



Figs 6A and B: The procedure of steroid injection in CTS under sterile condition

of 2% lignocaine after taking proper aseptic precaution by standard protocol.¹⁴

Ultrasonic Therapy

The ultrasound treatment was administered 15 minutes per session to the palmar carpal tunnel area at a frequency of 1 MHz and intensity of 1.0 W/cm^2 , pulsed mode 1:4, with a transducer of 5 cm^2 and with aquasonic gel as the couplant. A total of 15 UST were performed once a day, five times a week, for 3 weeks.¹¹

RESULTS AND ANALYSIS

After collecting all data, we analyzed all numerical data by using statistical tools.

For statistical analysis, we used the following software:

- Statistica version 6 [Tulsa, Oklahoma: StatSoft Inc., 2001]
- Graph Pad Prism version 5 [San Diego, California: Graph Pad Software Inc., 2007]

All numerical data were compared between groups by student independent sample t-test when they were normally distributed and Mann-Whitney test if otherwise. The chi-square test/officers exact test was employed for intergroup comparison of categorical variability. All analysis was two tailed and $p < 0.05$ was considered statistically significant.

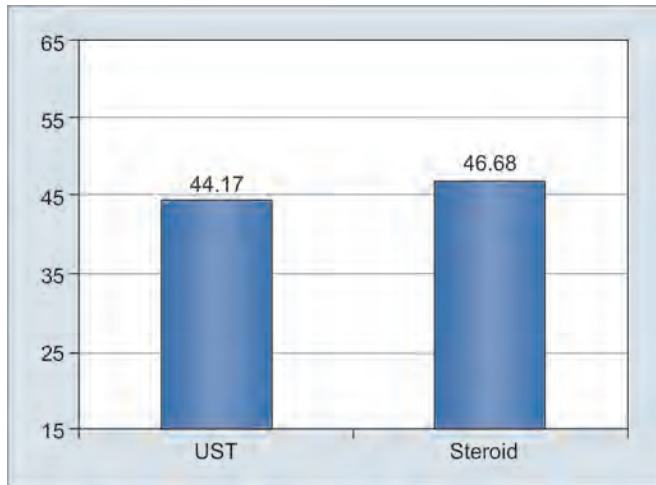
DEMOGRAPHIC PROFILE

Age Distribution

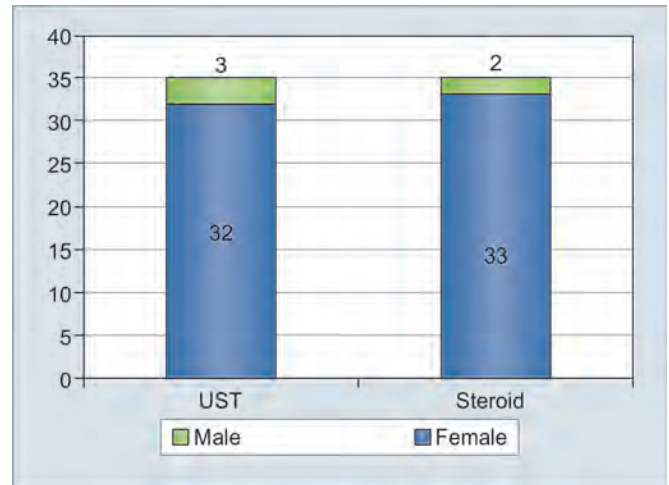
Age was normally distributed with the mean age for the UST group 44.17 and for the same for the steroid group was 46.6857, and there was no statistically significant difference between the groups (Graph 1).

Sex Distribution

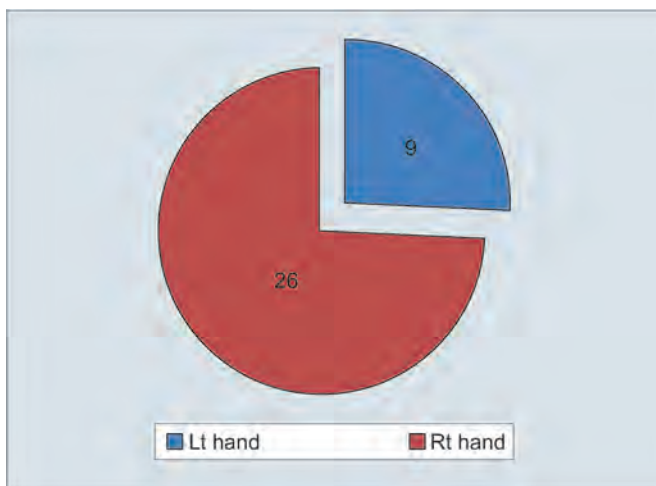
In our study, there were 35 patients in each group, of which 32 were female in the UST group and 33 were female in the steroid group (Graph 2).



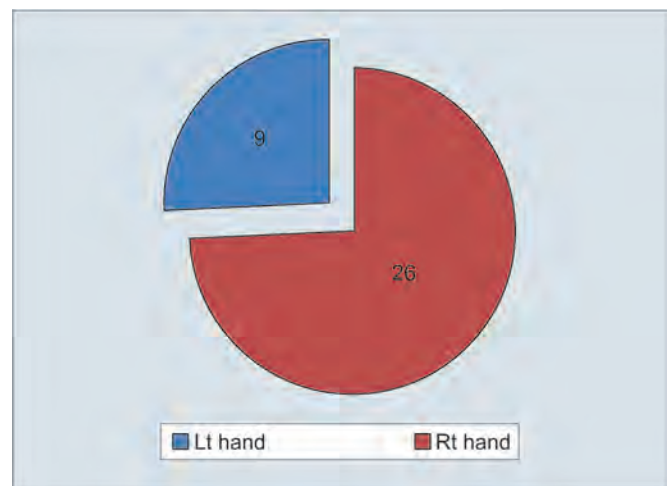
Graph 1: The mean age of the groups which is pretty well comparable in both the groups



Graph 2: Female preponderance in both the groups (91.43% in the UST group and 94.29% in the steroid group) with very good comparative sex distribution between the groups



Graph 3: Handedness of the UST group



Graph 4: Handedness of the steroid group

Hand Involvement

The above pictures are showing very good comparable groups with equal number of patients (26 right hand and 9 left hand) with dominant hand (right) in both the groups (Graphs 3 and 4).

CLINICAL AND ELECTROPHYSIOLOGICAL PARAMETERS

Table 1 shows that there is a significant improvement in phalen, VAS, FSS, SSS, and the improvement persists till the end of study. On the contrary, significant improvement in electrophysiological parameters was evident at the end of the study.

Table 2 shows that there is a significant improvement in clinical and electrophysiological parameters throughout the study.

From Table 3, it is evident that there is no significant difference between the groups except clinical parameters at the end of the study.

DISCUSSION

Carpal tunnel syndrome, the most common entrapment neuropathy of upper limb, is one of most commonly treated clinical entity in the Department of PMR. In our randomized parallel group control study, conducted at IPGME&R, over a period of eighteen months from January 15, 2012 to July 15, 2013, we looked for the efficacy of UST and steroid injection in patients with CTS affecting unilateral hand. After getting the ethical committee clearance, we included a total of 35 patients in each group previously we included 50 patients in the UST group.

At the beginning of this study, we see that mostly females in their middle age with mean age of 5th decade were affected. In our study, the dominant hand (mostly right hand) was more commonly affected with the ratio of right to left being 74.29 and 25.71% respectively, in both the groups.

The results of our study suggest that there was a marked improvement for all the clinical parameters in



Table 1: Changes by UST in different clinical and electrophysiological parameters over time

Parameters	0 week	2 weeks	4 weeks	8 weeks	p^{0-2}	p^{0-4}	p^{0-8}	p^{2-4}	p^{2-8}	p^{4-8}
Phalen	24.86	48.71	66.71	85.43	**	***	***	*	***	NS
Visual analog scale	7.34	4.71	3.34	2.34	**	***	***	*	***	NS
SSS	3.14	3.02	2.80	2.35	**	***	***	***	***	***
FSS	2.90	2.72	2.44	2.10	**	***	***	***	**	***
M_LAT	7.62	7.50	7.36	7.18	NS	NS	*	NS	NS	NS
LatMotM-U	2.96	2.82	2.70	2.50	NS	NS	*	NS	NS	NS
LatSenM-U	1.27	1.17	1.02	1.04	NS	***	***	*	NS	NS

* $p < 0.05$; ** $p < 0.01$; *** $p < 0.001$; NS: Nonsignificant; FSS: Functional severity score; SSS: Symptom severity score; M_LAT: Mean of median motor latency; LatMotM-U: Mean of difference of median and ulnar motor latency; LatSenM-U: Mean of difference of median and ulnar sensory latency

Table 2: Changes by steroid in different clinical and electrophysiological parameters over time

Parameters	0 week	2 weeks	4 weeks	8 weeks	p^{0-2}	p^{0-4}	p^{0-8}	p^{2-4}	p^{2-8}	p^{4-8}
Phalen	26.7	54.4	89.14	108.57	**	***	***	**	***	NS
Visual analog scale	7.71	4.37	2.4	1.14	***	***	***	*	***	NS
SSS	3.39	3.04	2.88	1.91	**	***	***	***	***	***
FSS	3.25	3.01	2.65	1.96	**	***	***	***	**	***
M_LAT	8.47	8.04	7.63	7.42	NS	***	***	NS	**	NS
LatMotM-U	3.49	2.95	2.47	2.23	**	***	***	*	***	NS
LatSenM-U	1.79	1.50	1.31	1.20	***	***	***	*	***	NS

* $p < 0.05$; ** $p < 0.01$; *** $p < 0.001$

Table 3: Comparison between the groups

Parameters	p^0	p^2	p^4	p^8
Phalen	0.939	0.238	0.003	0.001
Visual analog scale	0.310	0.385	0.030	0.001
SSS	0.019	0.264	0.002	0.001
FSS	0.012	0.081	0.083	0.930
M_LAT	0.082	0.208	0.534	0.616
LatMotM-U	0.202	0.736	0.544	0.492
LatSenM-U	0.106	0.057	0.111	0.347

both the groups. The same significant improvement was also found in the electrophysiological parameter in both the groups. The clinical and electrophysiological improvement was seen not only at the end of the treatment, but also they were maintained at the end of 8 weeks.

In our study, improvement of phalen and VAS was seen throughout the study for both the groups, and it was persistent till the end of this study, though the improvement was mainly up to 4 weeks, and there was not much improvement of phalen and VAS between 4 and 8 week, but there was a significant change between the groups at 4 and 8 weeks.

Bakhtiary et al,¹⁵ by using UST of frequency of 1 MHz and an intensity of 1.0 W/cm², with pulsed mode duty cycle of 1:4 for 15 days, also got significant improvement in pain ($p < 0.001$) at the end of treatment and at 4 weeks' time.

Agarwal¹⁴ had done a study by using 40 mg of local methyl prednisolone injection in CTS patients and improvement in phalen and VAS was seen in 93.7 and

81% of patients at 3 and 12 months respectively. We also got similar type of results.

Badarny et al¹⁶ had done a study by using a low-dose (12 mg) methylprednisolone acetate using a novel approach, and the favorable response rate for VAS after 1 month was 74% for pain.

For functional and symptom severity score, both the parameters show a significant improvement with time for both the groups, but there was no statistically significant difference between the groups, except symptom severity score at 8 weeks.

Baysal et al,¹¹ in their study, also got $p < 0.05$ at 8 weeks by using UST, nerve gliding exercise, and splinting, and they found a significant improvement in the functional status score and symptom-severity score at the end of the treatment immediately and at 8 weeks' follow-up. We also got a similar type of result by using UST for 3 weeks.

In Agarwal et al¹⁴ study, using steroid injection for CTS, they had shown a marked improvement in symptom severity and functional scores with 40 mg of methyl prednisolone injection.

In our study, there was improvement in electrophysiological values over the time by using both the treatment modalities (UST and steroid). Though the change in the median motor latency and the difference in the median and ulnar motor latency from 0 to 8 weeks were significant and others were not in the case of patients treated with UST, these changes were mostly significant for the steroid group except from 4 to 8 weeks. There were no

statistically significant differences between the groups in electrophysiological parameters.

Bakhtyary et al¹⁵ got similar results using 1 MHz and an intensity of 1.0 W/cm², with pulsed mode duty cycle of 1:4. Oztas et al¹⁷ had shown that UST has definitively a better role compared to placebo using UST in CTS, showing clinical improvement in all parameters and decreased motor nerve conduction velocity and increased motor distal latency (MDL).

In our study, improvement in the difference of median and ulnar sensory latency was significant between 2 to 4 and 8 weeks in patients with CTS by using UST, but significant changes in the median motor latency and difference in the median and ulnar motor latency occurred only between 0 and 8 weeks. Baysal et al,¹¹ in their study using UST for CTS, found that the median sensory distal latency (SDL) was significantly decreased at the end of the treatment and also at 8 weeks' follow-up ($p < 0.05$). A significant improvement was not recorded in the median MDL at the end of the treatment and at 8 weeks' follow-up ($p > 0.05$). We have got similar results in our study.

In Agarwal et al¹⁴ study, they had shown a marked improvement in symptoms with steroid injection, with a significant improvement in the mean values of the nerve conduction parameters distal motor latency at the wrist (DML) and distal sensory latency at the wrist (DSL W). In our study, we got similar results over 8 weeks' time using 40 mg of methyl prednisolone injection.

Bilgici et al¹⁸ had done a study on patients of CTS either with steroid or with UST. Both the groups showed a statistically significant improvement ($p < 0.01$) in pain, symptom severity, and functional score at 4 weeks and 8 weeks, and no statistically significant difference was observed between the groups. We also got similar results for the functional severity score, but we got statistically significant differences in VAS and symptom severity between the groups ($p < 0.05$). Bilgici et al¹⁸ showed that the median nerve motor latency decreased at 4 and 8 weeks compared to baseline in both the groups ($p < 0.01$), but no statistically significant difference was observed between the groups ($p > 0.05$). In our study, the change in the median motor latency for UST is significant in overall time period, but for steroid group, it was significant throughout the time period, but still there was no statistically significant difference between the groups. Bilgici et al¹⁸ observed significant improvement in sensory conduction over the time for both the groups without any statistically significant difference between the groups. In our study, we got a significant improvement in the difference between the median and ulnar sensory latency without any significant changes between the groups.

CONCLUSION

In our study, mostly females in their middle age with the mean age of 5th decade were affected with CTS with right hand (dominant hand) mostly affected. A clinical improvement was seen by both UST and steroid injection (statistically significant $p < 0.05$). Both the modalities were effective for electrophysiological improvement for CTS, but no one was better than the other, and both forms of treatment were effective not only to reduce the symptom severity score but also to minimize the functional severity score.

REFERENCES

1. Duncan KH, Lewis RC Jr, Foreman KA, Nordyke MD. Treatment of carpal tunnel syndrome by members of the American Society for Surgery of the Hand: results of a questionnaire. *J Hand Surg Am* 1987 May;12(3):384-391.
2. Scholten RJ, de Krom MC, Bertelsmann FW, Bouter LM. Variation in the treatment of carpal tunnel syndrome. *Muscle Nerve* 1997;20(10):1334-1335.
3. Akalin E, El O, Peker O, Senocak O, Tamci S, Gülbahar S, Cakmur R, Oncel S. Treatment of carpal tunnel syndrome with nerve and tendon gliding exercises. *Am J Phys Med Rehabil* 2002 Feb;81(2):108-113.
4. Rozmaryn LM, Dovel S, Rothman ER, Gorman K, Olvey KM, Bartko JJ. Nerve and tendon gliding exercises and the conservative management of carpal tunnel syndrome. *J Hand Ther* 1998 Jul-Sep;11(3):171-179.
5. Weiss ND, Gordon L, Bloom T, So Y, Rempel DM. Position of the wrist associated with the lowest carpal-tunnel pressure: implications for splint design. *J Bone Joint Surg Am* 1995 Nov;77(11):1695-1699.
6. Randall LB. *Physical medicine and rehabilitation*. 4th ed. 2011 by Saunders ELSEVIER at Philadelphia p. 518.
7. Brininger TL, Rogers JC, Holm MB, Baker NA, Li ZM, Goitz RJ. Efficacy of a fabricated customized splint and tendon and nerve gliding exercises for the treatment of carpal tunnel syndrome. A randomized controlled trial. *Arch Phys Med Rehabil* 2007 Nov;88(11):1429-1435.
8. Nacimiento AC, Bartels M, Loew F. Acute effects of dexamethasone on normal and on posttraumatic spinal cord polysynaptic reflex activity and axonal conduction. *Surg Neurol* 1986 Jul;26(1):13-16.
9. Qin C, Greenwood-Van Meerveld B, Myers DA. Corticosterone acts directly at the amygdala to alter spinal neuronal activity in response to colorectal distension. *J Neurophysiol* 2003 Mar;89(3):1343-1352.
10. Kisner C, Colby LA. *Therapeutic exercise foundations and techniques*. 5th ed. 2007 by F. A. Davis Company 1915 Arch Street Philadelphia, PA 19103 p. 375.
11. Baysal O, Altay Z, Ozcan C, Ertem K, Yologlu S, Kayhan A. Comparison of three conservative treatment protocols in carpal tunnel syndrome. *Int J Clin Pract* 2006 Jul;60(7):820-828.
12. Totten PA, Hunter JM. Therapeutic techniques to enhance nerve gliding in thoracic outlet syndrome and carpal tunnel syndrome. *Hand Clin* 1991 Aug;7(3):505-520.
13. Braddom RL. *Physical medicine and rehabilitation*. 4th ed. 2011 by Saunders ELSEVIER at Philadelphia pp. 1084-1085.

14. Agarwal V, Singh R, Sachdev A, Wiclaiff Shekhar S, Goel D. A prospective study of the long-term efficacy of local methyl prednisolone acetate injection in the management of mild carpal tunnel syndrome. *Rheumatology* 2005 May;44(5):647-650.
15. Bakhtiary AH, Rashidy-Pour A. Ultrasound and laser therapy in the treatment of carpal tunnel syndrome. *Aus J Physiother* 2004;50(3):147-151.
16. Badarny S, Rawashdeh H, Meer J, Abed S, Habib G. Repeated electrophysiologic studies in patients with carpal tunnel syndrome following local corticosteroid injection using a novel approach. *IMAJ* 2011 Jan;13(1):25-28.
17. Oztas O, Turan B, Bora I, Karakaya MK. Ultrasound therapy effect in carpal tunnel syndrome. *Arch Phys Med Rehabil* 1998 Dec;79(12):1540-1544.
18. Bilgici A, Ulosoy H, Kuru O, Cantruck F. The comparison of ultrasound and local steroid injection plus splinting in the treatment of carpal tunnel syndrome: a randomized controlled trial. *Bratisl Lek Lystiy* 2010;111(12):659-665.