

CASE REPORT

Atypical Cases of Internal Disk Disruption mimicking Radiculopathy: A Case Series Study

¹Ravi S Sharma, ²Gautam Das, ³Palak Chavda, ⁴DR Suyashi

ABSTRACT

Internal disk disruption (IDD) is a common cause of disabling low back pain (LBP) in a substantial number of young, healthy adults. The IDD is a common entity; nearly 30 to 50% of subjects with chronic LBP have IDD. Most of the patients experience a diffuse, dull ache or a deep-seated, burning, lancinating pain in the back. Referral of pain into the hips and lower limbs is not uncommon. In acute cases, a history of lifting trauma precedes the back pain. In the chronic stage, pain and muscle spasm are less dramatic and more nondescript. Typically, there is no objective evidence of radiculopathy, even in those who have a radicular pattern of pain referral. We report four cases with history of gradual-onset LBP of moderate intensity radiating up to lower limb. There was associated weakness and numbness along the lower limb. The area of distribution of pain was similar to radicular pattern. Tingling and burning sensation were also evident along with the pain. Pain was mainly restricted over the buttock along with lower extremity area. Examination findings revealed similar pain in almost all the cases, revealing mild tenderness over buttock on deep palpation, and the flexion, adduction and internal rotation (FAIR) test was weakly positive. Most of the magnetic resonance imaging (MRI) findings were normal except for the presence of a hyperintense zone (HIZ) in area adjoining disk. So, the first differential diagnosis of piriformis syndrome was made. Diagnostic piriformis injections were performed with local anesthetic in a fan-shaped manner along the direction of muscle fibers without significant improvement. Considering the IDD as another differential diagnosis, also evident by the presence of HIZ in MRI, ramus communicans block was performed. There was significant pain reduction along with improvement of other symptoms like weakness, tingling, and burning sensation following the ramus communicans block.

Keywords: Internal disk disruption, Radiculopathy, Ramus communicans block.

How to cite this article: Sharma RS, Das G, Chavda P, Suyashi DR. Atypical Cases of Internal Disk Disruption mimicking Radiculopathy: A Case Series Study. *J Recent Adv Pain* 2018;4(1):39-43.

Source of support: Nil

Conflict of interest: None

^{1,3}Fellow, ²Director, ⁴Junior Resident

¹⁻³Department of Pain Management, DARADIA: The Pain Clinic Kolkata, West Bengal, India

⁴Department of Anatomy, All India Institute of Medical Sciences Jodhpur, Rajasthan, India

Corresponding Author: Ravi S Sharma, Fellow, Department of Pain Management, DARADIA: The Pain Clinic, Kolkata, West Bengal, India, Phone: +919993116929, e-mail: drravishankar-sharma4u@gmail.com

INTRODUCTION

Internal disk disruption, first proposed by Crock,¹ has been defined as lumbar spinal pain, with or without referred pain, stemming from an intervertebral disk, caused by internal disruption of the normal structural and biochemical integrity of the symptomatic disk.² The prevalence of IDD has been estimated to be 39% in 92 patients with chronic LBP.³ In a more recent study, it has been estimated at 42%.⁴ Most of the patients have a varying degree of sitting intolerance, and lumbar spine movements are slow, guarded, and restricted. There is a history of lifting trauma preceding the back pain in acute cases. Pain and muscle spasm are less dramatic and more nondescript in persistent cases.⁵ There is a sensation of a weak, unstable back along with referral of pain into the hips. But the radicular symptoms following a particular dermatome are usually not associated with IDD. Here, we report unusual cases of IDD where along with LBP (particularly buttock pain) there was weakness, tingling, and numbness in the lower extremity along a particular dermatome. So, we made two differential diagnoses. As most of the presentations were similar to piriformis syndrome, initially we performed diagnostic piriformis injection, which resulted in inadequate pain relief. Thereafter, ramus communicans block was performed at the above vertebrae level under C-arm considering IDD as our second differential diagnosis due to presence of HIZ in the MRI. Following the block, there was near-complete pain relief along with significant improvement in weakness and other radicular symptoms.

CASE REPORTS

Case 1

A 41-year-old male presented with a history of gradual onset LBP of moderate intensity [numeric rating scale (NRS 6)] since 4 years. Initially, there was mild pain and discomfort in the left buttock, but with time, this pain progressed to involve the whole of the left limb reaching up to left sole. The area of distribution of pain was similar to S1 dermatome. It was associated with weakness, tingling, and burning sensation along the entire left limb. Since last 2 years, this pain aggravated so much so that he was unable to walk properly. On careful elicitation of history, we found that pain was more on sitting over the left buttock along with lower back area. On examining

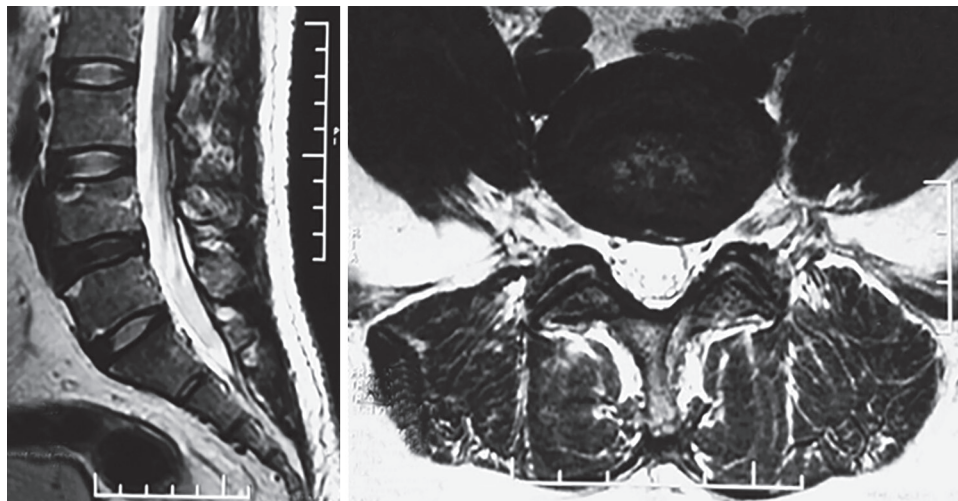


Fig. 1: The HIZ at L4-L5 disk level on T2-weighted MRI

this patient, we found mild tenderness over left buttock on deep palpation. The FAIR test was weakly positive on that side only. Most of T2-weighted MRI findings were normal except the presence of HIZ in area adjoining L4-L5 disk. So, we made our first differential diagnosis as piriformis syndrome. Another differential diagnosis kept as reserve was IDD, as HIZ was evident on MRI findings (Fig. 1). Hence, initially, we planned to go with diagnostic block of piriformis muscle to confirm our diagnosis. We injected 2% lignocaine in a fan-shaped manner along the direction of muscle fibers. But, the diagnostic block resulted in insignificant degree of pain relief. Therefore, we decided to perform ramus communicans block, as IDD was also kept as a differential diagnosis.

We performed ramus communicans block at the vertebrae level just above the affected disk. After identification of the L4 vertebrae under C-Arm. Thereafter true anteroposterior view followed by squaring the L4 vertebrae was achieved through craniocaudal tilt. Thereafter, ipsilateral oblique view was obtained to bury half of the transverse process within the vertebral body. It was followed by insertion of needle in such a way to hit the vertebral body. Thereafter, C-arm was taken to lateral view in order to see the adequate depth. The needle was advanced up to midpoint of the vertebral body. Thereafter, dye was injected to rule out intravascular spread. Once the position was confirmed, we injected 2 mL of 1% lignocaine. Following the injection, we observed for results and for the uttermost surprise, the patient was feeling better. He was able to perform all those activities in which previously he felt difficulties. Weakness also improved along with radiating pain. On the same day in the evening, the patient was discharged.

Case 2

A 67-year-old male presented with history of right-sided paramedian LBP radiating up to the right ankle since

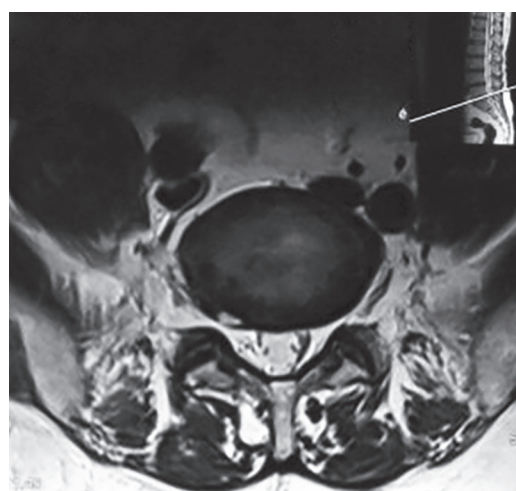


Fig. 2: HIZ at L5-S1 disk level on T2-weighted MRI

6 months. Initially, there was mild pain over the right buttock, and this pain was aggravated on sitting. The area of distribution of pain was similar to L4 dermatome. There was associated weakness and tingling sensation along the right limb. On examination, patient reported 20% sensory loss over right calf as compared with left side. Tenderness over right buttock was evident, and FAIR test was positive. So, we performed diagnostic piriformis injection, which resulted in insignificant degree of pain relief. Thereafter, we ordered MRI, which revealed presence of HIZ at L5-S1 area over the right side. Hence, we performed ramus communicans block at L5 vertebrae level following the above-mentioned technique (Fig. 2). Following block, patient reported more than 80% pain relief along with other symptoms including weakness. On the same day in the evening, the patient was discharged.

Case 3

A 58-year-old female presented with history of LBP and weakness along left lower limb. Pain was of moderate

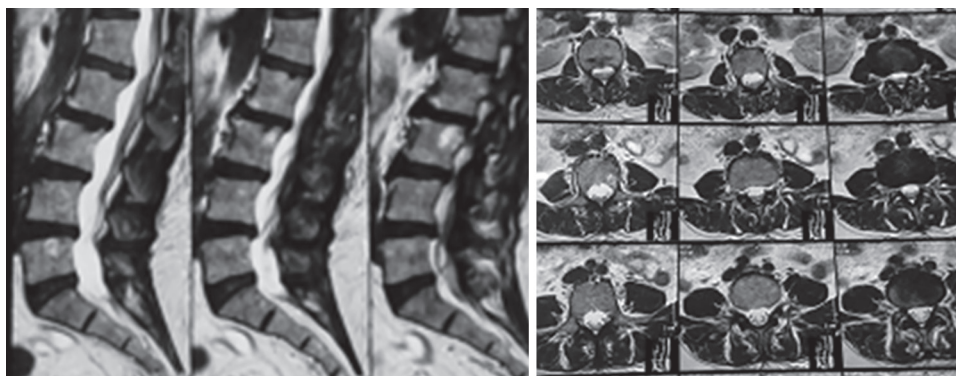


Fig. 3: Degenerative changes at multiple levels on T2-weighted MRI

intensity (NRS 6) radiating up to the left ankle since 3 months. Pain was mainly over left buttock, and this pain was aggravated on sitting. The area of distribution of pain was similar to L4 dermatome. There was associated weakness, heaviness, and tingling sensation along the right limb. For this complaint, she visited a neurosurgeon, where MRI was asked. Most of the MRI findings including canal diameter was normal, except for the presence of degenerative changes at multiple lumbar level. On examining this patient, we found mild sensory loss along with mild weakness over left limb as compared with right limb. Mild tenderness over left buttock was evident. So, we performed diagnostic piriformis injection, which resulted in insignificant degree of pain relief. As MRI showed degenerative changes at multiple levels, we planned to perform ramus communicans block as all the fibers converged at the level of L2 (Fig. 3). Following the block using above-mentioned technique, the patient had near-complete relief of symptoms. Later, patient was discharged on the same day.

Case 4

A 67-year-old female came to our clinic with history of LBP along with radiation to both legs (left > right), resembling dermatomal distributed pain. Pain was aggravated on sitting and climbing stairs. On examination, straight leg raise was weakly positive on both sides, along with tenderness over left piriformis and left sacroiliac (SI) joint. The MRI picture revealed presence of HIZ at the level of L4-L5. So, we made three differential diagnoses as IDD, piriformis syndrome, and SI joint arthropathy. After explaining every possibility, we went for ramus communicans block at the level of L4 bilaterally, which resulted in more than 90% pain relief (Fig. 4). Later, patient was discharged on the same day.

DISCUSSION

Researchers from Johns Hopkins Hospital have reported that 40 to 80% of chronic pain patients are misdiagnosed.⁶

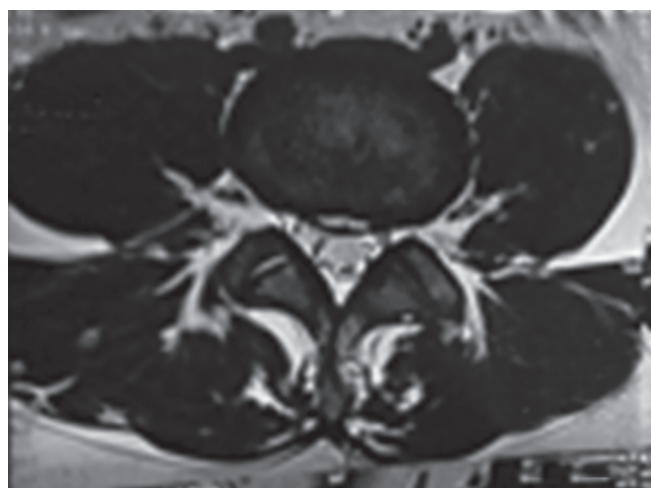


Fig. 4: HIZ at L4-L5 disk level on T2-weighted MRI

The IDD, first proposed by Crock,¹ has been defined as lumbar spinal pain, with or without referred pain, stemming from an intervertebral disk, caused by internal disruption of the normal structural and biochemical integrity of the symptomatic disk. Degenerative changes first appear in men in the second decade and in women a decade later. By the time an individual reaches the age of 50, 97% of his/her lumbar disks are degenerated; most commonly involved disks are L3-4, L4-5, and L5-S1 segments.^{7,8} Crock¹ postulated that traumatic damage to the vertebral end plate could cause an irritant substance to drain into the spinal canal and/or vertebral body. This could initiate an autoimmune response, causing an internal process of disk degradation, which would lead to annular tearing and irritation of the free nerve endings in the outer third of the annulus fibrosis. Crock's⁹ description of IDD included features like intractable back pain with aggravation of pain and loss of spinal motion with any physical exercises along with leg pain. Magnetic resonance imaging of the lumbosacral spine can identify areas where there are changes to signal intensity, with a loss of signal intensity correlating with abnormal disk morphology on diskography,¹⁰ but the gold standard in making the diagnosis of IDD remains an invasive test

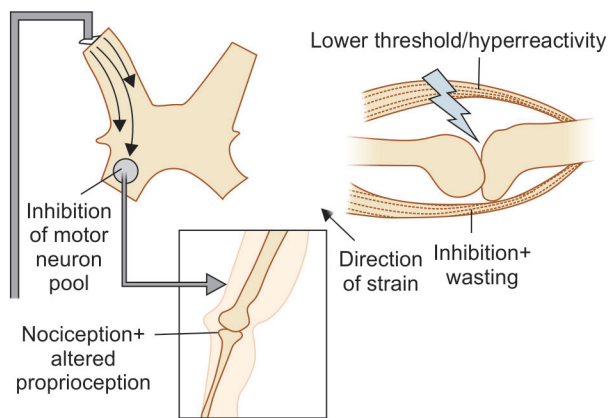


Fig. 5: Mechanism of arthrogenic inhibition

called provocation diskography with follow-up computed tomography diskogram. Quite often, patients with lower lumbar disk lesions experience inguinal pain corresponding to L1–2 dermatomes. Usually, radiculopathy is one of the commonest complaints seen in the pain clinics and herniated intervertebral disk is the cause in most of the cases.¹¹ In our case series, patients had pain along the lower extremity mimicking the pattern of radicular pain. Our case findings were similar to a study carried out by Mooney et al¹² and Ohnmeiss et al.¹³ Referred lower limb pain can be possible from any of the following: The facet joint, the spinal ligaments, a piriformis syndrome,¹⁴ or the spinal muscles. The physiological mechanism of this referred leg pain is thought to be from convergence of primary sensory afferents on the dorsal horn neurons of the spinal cord. There are studies that support the hypothesis that a biochemical or neurochemical reaction occurs (within the outer one-third of the posterior annulus) that, in turn, stimulates the nerve roots via an inflammation reaction, especially if the outer layers of the annulus are leaking nuclear material.¹⁵ But this chemical radiculitis cannot explain weakness, which was evident in our patients, and which was relieved after ramus communicans block (Fig. 5). The cause of weakness may be explained by arthrogenic muscle inhibition, i.e., an impairment caused by an ongoing reflex inhibition of the musculature surrounding a joint also evident by results of ramus communicans block resulting in near-complete relief of pain and weakness in our patients. There are other studies supporting the concept of arthrogenic muscle weakness.^{16,17}

The preferred treatments for diskogenic axial or radiating LBP are controversial. In recent years, ramus communicans block had been seen quite effective in managing diskogenic back pain. We managed our patients successfully via ramus communicans block. This form of treatment modality for managing disk pain has been supported by various other studies.^{18–20}

CONCLUSION

The IDD may present with unusual features like pain, tingling, and numbness along a particular dermatome along with LBP. The diagnosis can be confirmed by careful history, detailed examination, and imaging studies followed by diagnostic interventions. It can be successfully managed with ramus communicans block.

REFERENCES

1. Crock HV. A reappraisal of intervertebral disc lesions. *Med J Aust* 1970 May;1(20):983-989.
2. IASP Taxonomy Working Group. Classification of chronic pain: descriptions of chronic pain syndromes and definitions of pain terms. 2nd ed. Seattle: IASP Press; 2011.
3. Schwarzer AC, Aprill CN, Derby R, Fortin J, Kine G, Bogduk N. The prevalence and clinical features of internal disc disruption in patients with chronic low back pain. *Spine (Phila Pa 1976)* 1995 Sep;20(17):1878-1883.
4. DePalma MJ, Ketchum JM, Saullo T. What is the source of chronic low back pain and does age play a role? *Pain Med* 2011 Feb;12(2):224-233.
5. Sehgal N, Fortin JD. Internal disc disruption and low back pain. *Pain Physician* 2000 Apr;3(2):143-157.
6. Hendler N. Why chronic pain patients are misdiagnosed 40 to 80% of the time? *J Recent Adv Pain* 2016 Sep-Dec;2(3):94-98.
7. Adams MA, McNally DS, Dolan P. Stress distribution inside intervertebral discs. The effects of age and degeneration. *J Bone Joint Surg Br* 1996 Nov;78(6):965-972.
8. Adams MA, Dolan P, Hutton WC. The stages of disc degeneration as revealed by discograms. *J Bone Joint Surg Br* 1986 Jan;68(1):36-41.
9. Crock HV. Internal disc disruption: a challenge to disc prolapse fifty years on. *Spine (Phila Pa 1976)* 1986 Jul-Aug;11(6):650-653.
10. Milette P, Fontaine S, Lepanto L, Cardinal E, Breton G. Differentiating lumbar disc protrusions, disc bulges, and disc with normal contour but abnormal signal intensity. Magnetic resonance imaging with discographic correlations. *Spine (Phila Pa 1976)* 1999 Jan;24(1):44-53.
11. Kulkarni R. A case of symptomatic lumbar perineural cyst. *J Recent Adv Pain* 2015 Sep-Dec;1(2):95-96.
12. Mooney V. Where is the pain coming from? *Spine (Phila Pa 1976)* 1987 Oct;12(8):754-759.
13. Ohnmeiss DD, Vanharanta H, Ekholm J. Degree of disc disruption and lower extremity pain. *Spine (Phila Pa 1976)* 1997 Jul;22(14):1600-1665.
14. Villano EQ, Das G, Sharma K, Rijhwani K. A case of piriformis syndrome mimicking radiculopathy. *J Recent Adv Pain* 2015 May-Aug;1(1):24-25.
15. Marshall LL, Trethewie ER, Curtain CC. Chemical radiculitis: a clinical, physiological and immunological study. *Clin Orthop Relat Res* 1977 Nov-Dec;129:61-67.
16. Rice DA, McNair PJ, Lewis GN, Dalbeth N. Quadriceps arthrogenic muscle inhibition: the effects of experimental knee joint effusion on motor cortex excitability. *Arthritis Res Ther* 2014 Dec;16(6):502.
17. Verbunt JA, Seelen HA, Vlaeyen JW, Bousema EJ, van der Heijden GJ, Heuts PH, Knottnerus JA. Pain-related factors contributing to muscle inhibition in patients with chronic low back pain: an experimental investigation based on

- superimposed electrical stimulation. *Clin J Pain* 2005 May-Jun;21(3):232-240.
18. Jang JS, Kwon HK, Lee JJ, Hwang SM, Lim SY. Rami communicans nerve block for the treatment of symptomatic Schmorl's nodes—a case report. *Korean J Pain* 2010 Dec;23(4):262-265.
19. Tae HS, Kim SD, Park JY, Kim SH, Lim DJ, Suh JK. Gray ramus communicans nerve block: a useful therapeutic adjuvant for painful osteoporotic vertebral compression fracture. *J Korean Neurosurg Soc* 2003 Dec;34(6):505-508.
20. Das G, Dey S, Sharma RS, Sharma K, Dutta D, Roy C. Rami communicans block prior to transforaminal endoscopic discectomy relieves procedure pain significantly and adds safety: a case-control study. *J Recent Adv Pain* 2017 May-Aug;3(2):90-95.