

A Study comparing the Analgesic Efficacy of Ultrasound-guided TAP Block vs Laparoscopy-guided TAP Block in Patients undergoing Laparoscopy-assisted Ventral Hernia Repair

¹V Shankar, ²A Raj, ³C Chatterjee, ⁴A Prasad, ⁵A Tiwary

ABSTRACT

Aim: To assess and compare the postoperative analgesic effect of laparoscopy-guided transversus abdominis plane (TAP) block vs ultrasound-guided TAP block in patients undergoing Laparoscopy-assisted ventral hernia repair.

Materials and methods: A prospective randomized control trial was undertaken with 50 patients undergoing elective laparoscopic ventral hernia repair. The patients belonging to group I (n = 25) received 15 mL of 0.25% bupivacaine on both sides by ultrasound guidance at the end of the procedure, whereas those in group II (n = 25) received the same under laparoscopic guidance at the end of the procedure. Postoperative pain scores were measured using visual analog scale (VAS) both at rest and during motion at 0, 2, 4, 6, 12, and 24 hours postoperatively. Other parameters like the administration of first dose of rescue analgesic and time required for postoperative ambulation were also recorded.

Results: Demographic data, duration of surgery, and size of the hernial defect were comparable in both the groups. The total intraoperative opioid consumption was also similar in both the groups (p = 0.740). The pain scores at rest as well as during motion were comparable at all points between the two groups. The time required for the administration of first dose of rescue analgesic as well for postoperative ambulation was also similar in both the groups.

Conclusion and clinical significance: Our study establishes that laparoscopy-guided TAP block is an effective modality to provide analgesia for patients undergoing laparoscopy-assisted ventral hernia repair. Ultrasound-guided TAP block has been long established as an effective modality in providing postoperative analgesia. However, the nonavailability of ultrasound machines in operating rooms especially in developing countries like ours limits its use in a perioperative setting. Laparoscopy-guided TAP block might be as effective, easier, and probably less time consuming than ultrasound-guided TAP block.

Keywords: Laparoscopy, Laparoscopy-guided transversus abdominis plane block, Postoperative analgesia, Prospective study, Ultrasound-guided transversus abdominis plane block, Ventral hernia.

How to cite this article: Shankar V, Raj A, Chatterjee C, Prasad A, Tiwary A. A Study comparing the Analgesic Efficacy of Ultrasound-guided TAP Block vs Laparoscopy-guided TAP Block in Patients undergoing Laparoscopy-assisted Ventral Hernia Repair. *J Recent Adv Pain* 2018;4(1):10-14.

Source of support: Nil

Conflict of interest: None

INTRODUCTION

The growing prevalence of obesity and the increasing number of patients undergoing abdominal surgeries have lead to an increase in the rates of ventral hernia repairs performed all over the world. Laparoscopic ventral hernia repair compared with open repair has decreased recurrence rates, shortened hospital stay, and reduced morbidity.¹⁻⁴ Contrary to popular belief there is significant postoperative pain associated with laparoscopic approach thought to be due to transabdominal sutures and laparoscopic tacks used during the procedure. Postoperative analgesia is of paramount importance in this procedure given the fact that most of the patients are elderly and obese with multiple comorbidities.⁴ Port infiltrations and percutaneous pain pump devices along with routine non-steroidal anti-inflammatory drugs (NSAIDs) and opioids have been used in attempts to reduce postoperative pain with limited success.

Abdominal field blocks have been around for a long time and have been extensively used as they are mostly technically unchallenging. Transverse abdominal blocks either ultrasound guided or blind have been used to improve analgesia and postoperative opioid consumption in several laparoscopic surgical procedures.⁵⁻⁸ Use of an ultrasound for performing transverse abdominal blocks has been associated with improved analgesia as well as lower rate of complications.^{9,10} Recently, Magee et al¹¹ performed TAP block under direct laparoscopic visualization and proposed laparoscopy-guided TAP block as an alternative to avoid iatrogenic injuries.

^{1,5}Attending Consultant, ²Consultant, ^{3,4}Senior Consultant

¹⁻³Department of Anesthesia, Indraprastha Apollo Hospital New Delhi, India

^{4,5}Department of Surgery, Indraprastha Apollo Hospital, New Delhi, India

Corresponding Author: A Raj, Consultant, Department of Anesthesia, Indraprastha Apollo Hospital, New Delhi, India
e-mail: anupamraj21@gmail.com

With the use of direct visualization with a laparoscope, a blunt needle is inserted through the skin at the level of the midaxillary line, midway between the iliac crest and costal margin. The needle is inserted further until two distinct “pops” are felt, indicating correct needle position between internal oblique and transversus abdominis muscle. The laparoscope confirms a bulge, which signifies the injectate covered by the transversus abdominis muscle.

The investigators hypothesized that the laparoscopy-assisted TAP block being a “semi-blind technique” would be inferior in analgesic efficiency when compared with ultrasound-guided TAP in which the spread of local anesthetic in the right plane can be confirmed by direct visualization through ultrasound guidance.

MATERIALS AND METHODS

Trial Design and Participation

This prospective, patient-blinded, randomized control trial was undertaken at Indraprastha Apollo Hospital, New Delhi, after the approval of ethics committee. The trial included 50 patients belonging to American Association of Anesthesia (ASA) class 1/2 undergoing elective laparoscopic ventral hernia repair between December 2015 and December 2016. The patients who belonged to the age group of 18 to 80 years belonging to either sex and ASA physical status of 1 and 2 were included in the study provided they signed an informed consent. Patients belonging to ASA grade III or higher, who refused to sign the informed consent, who have a documented history of allergy toward amide local anesthetics and those on whom the procedure was converted to open hernia repair were excluded from the study.

Protocol

All the procedures were performed by the same surgeon. All patients received general anesthesia for the surgery. Preoperative evaluation was done according to the departmental protocol. All patients were oriented about the use of VAS score and were randomly allotted into two groups based on lots.

1. Group I: Patients received TAP block at the end of procedure using 15 mL of 0.25% bupivacaine on each side by ultrasound guidance.
2. Group II: Patients received TAP block at the end of procedure using 15 mL of 0.25% bupivacaine on each side by laparoscopic guidance.

A standardized general anesthetic regimen was employed, consisting of propofol 2.5 mg/kg, fentanyl 2 µg/kg, and atracurium 0.5 mg/kg. Sevoflurane was used to maintain 1.0 to 1.2 minimum alveolar concentration, along with oxygen and nitrous oxide. Fentanyl boluses

were given in response to change in hemodynamics (more than 15% increase in heart rate or mean arterial pressure from baseline). The total dose of fentanyl required was documented. All patients received intravenous paracetamol at 20 mg/kg during the procedure. At the end of procedure patients in group I were administered bilateral TAP block using 15 mL of 0.25% bupivacaine under ultrasound guidance, whereas those in group II received bilateral TAP block using 15 mL of 0.25% bupivacaine under laparoscopic guidance. Extubation was done once the patients satisfied the criteria for on-table extubation.

Perioperative Care

Postoperatively, the patients were transferred to the post-anesthesia care unit (PACU) for 1 hour. In the PACU, pain was assessed by VAS scores and fentanyl 0.5 µg/kg was administered if pain score was more than 3. The criteria for discharge from PACU would be 1—pain score <3, 2—absence of nausea or vomiting, 3—hemodynamic stability, and 4—alert or appropriately responsive to voice.

In the surgical ward, all patients received tramadol at a dose of 1.5 mg/kg along with ondansetron 0.1 mg/kg. Pain scores will be measured using VAS. Pain scores >3 will be treated with fentanyl 0.5 µg/kg boluses. The time points of pain assessments will be at 0, 2, 4, 6, 12, and 24 hours postoperatively. Pain scores will be measured at rest and movement (patient will be asked to flex their knees).

Outcomes

The primary outcome was the postoperative pain scores at the time of shifting to PACU, and every 2nd hourly for 24 hours. The secondary outcomes were the time required for the administration of the first dose of rescue analgesic, time required for postoperative ambulation, and complications of TAP block like LA toxicity, vascular injury, local hematoma, and visceral injury.

RESULTS

Continuous variables are presented as mean ± standard deviation (SD), and categorical variables are presented as absolute numbers and percentage. The comparison of normally distributed continuous variables between the groups was performed using Student's t-test. Nominal categorical data between the groups were compared using Chi-squared test or Fisher's exact test as appropriate; $p < 0.05$ was considered statistically significant.

Age, sex, body mass index (BMI), and the duration of surgery were comparable among the three groups (Table 1). Demographic data (age, sex, and BMI) as well

Table 1: Demographic data and duration of surgery

	Group I	Group II	p-value
	Mean ± SD	Mean ± SD	
Age	47.64 ± 8.94	48.88 ± 9.21	0.631
BMI	28.12 ± 2.86	28.12 ± 2.86	0.248
Duration of surgery	83.24 ± 6.71	80.56 ± 9.24	0.246
Sex (male/female)	9/16	10/15	0.771

as the duration of surgery were comparable in both the groups. The percentage of patients who had undergone previous abdominal surgeries were comparable in both the groups (72 vs 76%) (Graph 1). There was no significant difference in the size of the hernia in both the groups as well (41.88 ± 10.74 vs 40.72 ± 8.65) (Graph 2).

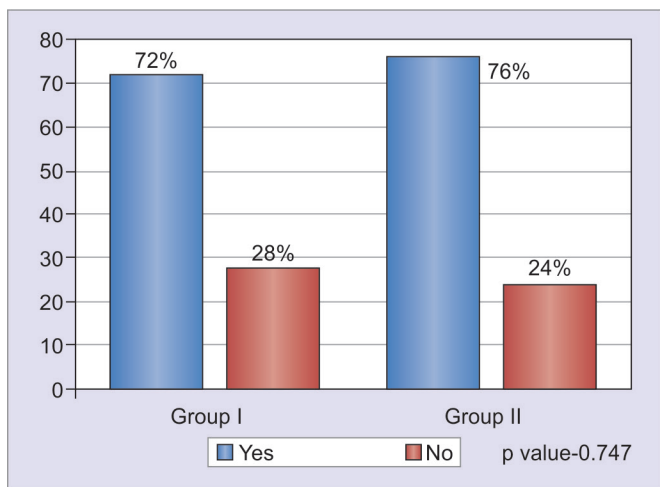
Intraoperative opioid consumption was similar in both the groups (Graph 3).

Pain scores measured at rest and motion at 0, 2, 6, 12, and 24 hours were similar in both the groups (Graphs 4 and 5). There was no significant difference in the time elapsed for administering the first dose of rescue

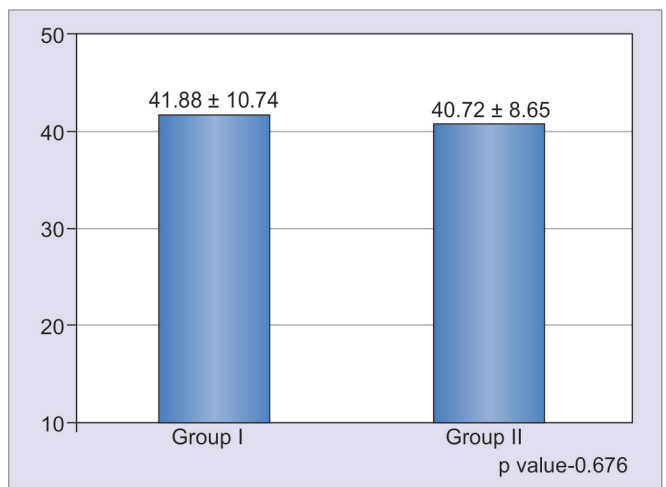
analgesic as well as the time required for ambulation (Graphs 6 and 7).

DISCUSSION

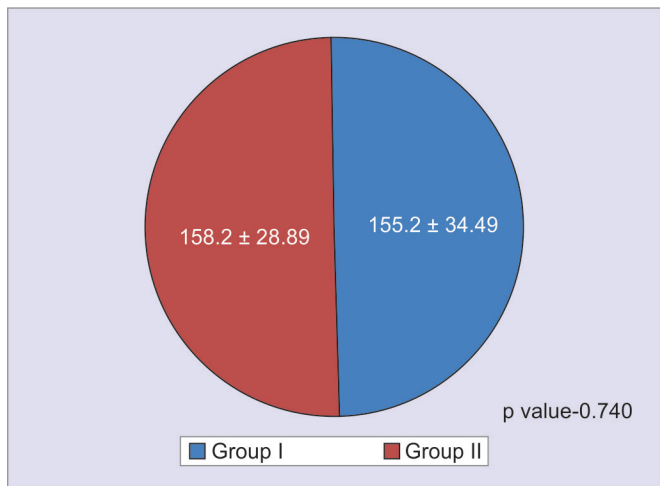
Improved surgical outcome and reduction in postoperative stress response, morbidity, and length of hospital stay are the benefits of providing good postoperative analgesia. While laparoscopic ventral hernia repair is considered to be a minimally invasive technique, acute postoperative pain is common, resulting in the need of parenteral opiates and NSAIDs especially in the first 24 hours postoperatively. Reducing the postoperative use of opiates has shown to limit complications like nausea, vomiting, respiratory depression, urinary retention, and constipation.^{12,13} The TAP blocks in laparoscopic surgeries have shown to be effective in reducing pain scores and opioid consumption.¹⁴ A recent randomized control trial demonstrated that laparoscopic-assisted TAP blocks provided effective analgesia after laparoscopic ventral hernia repair.¹⁵ Recently, laparoscopic-assisted TAP block



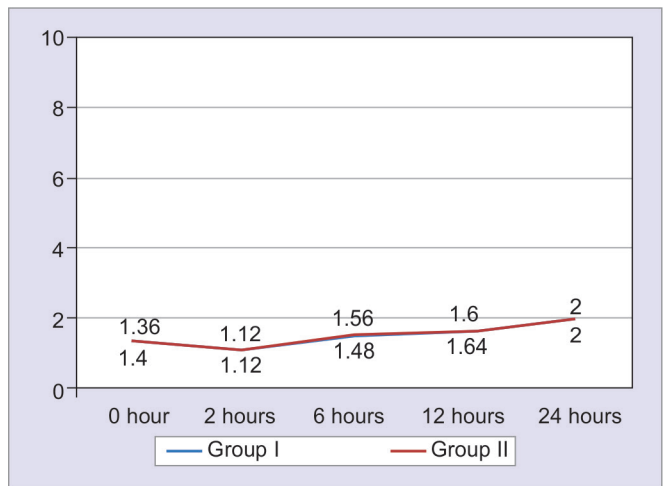
Graph 1: Previous abdominal surgeries



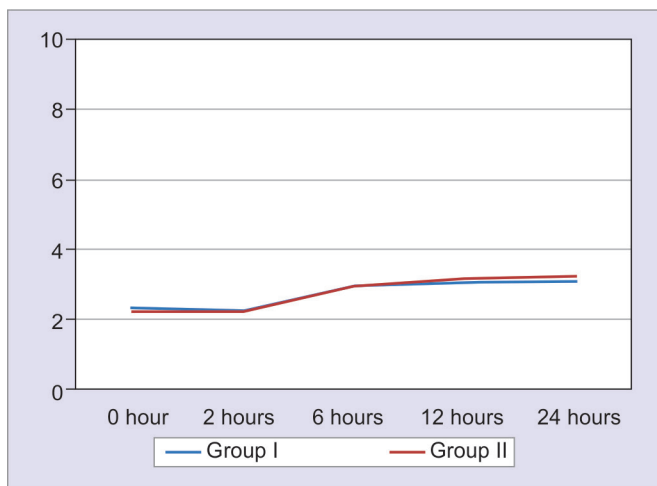
Graph 2: Size of the hernia



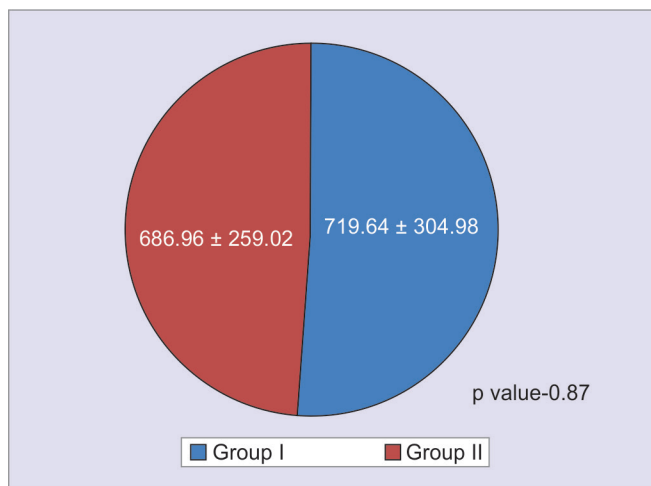
Graph 3: Intraoperative opioid consumption



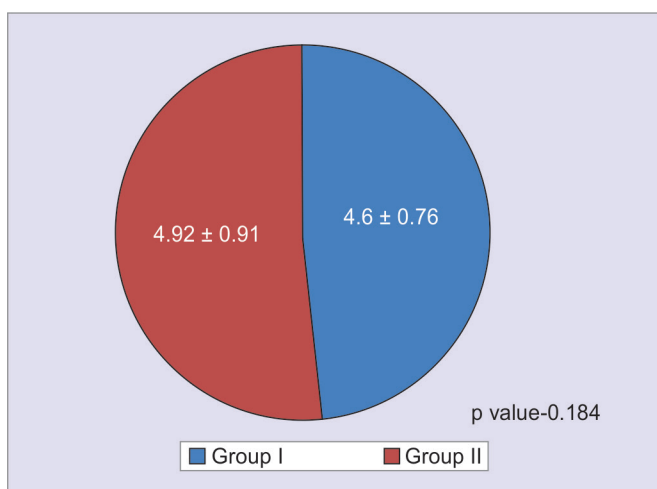
Graph 4: Pain score at rest



Graph 5: Pain score in motion



Graph 6: First dose of rescue analgesia in minutes



Graph 7: Time required for ambulation in hours

The results of our study suggest that the postoperative pain scores were similar in both the groups. The time of administration of the first dose of rescue analgesic as well as the time required for ambulation in the postoperative period was also comparable in both the groups.

Some complications like puncture of intraperitoneal organs have been documented after a blind TAP block.¹⁸ Fortunately, none of the patients in our study group encountered any of the above complications. The laparoscopic TAP block is efficacious and safe. Because the block is done under laparoscopic guidance, we avoid the peritoneal puncture or organ damage reported with other techniques. Finding the transverses abdominis neurovascular plane might be difficult, but the facial pops during needle insertion, visualization of needle tip pressure on the muscle wall with the laparoscope, and the presence of a wheal covered by transversus abdominis after injection helps in localization of the correct plane.

Our study does have its own limitations. The mean cumulative dose of opioids required during the postoperative period was not analyzed. In addition to that we did not collect data on clinical differences like postoperative nausea-vomiting, return of gastrointestinal function, postoperative sedation scores, and spirometry. Further studies should assess the efficacy of laparoscopy-guided TAP block on these clinical endpoints.

CONCLUSION

This study proves that laparoscopy-assisted TAP block provides adequate analgesia in patients undergoing laparoscopic ventral hernia repair. Ultrasound-guided TAP block has been long established as an effective modality of providing postoperative analgesia in patients undergoing abdominal surgeries. However, in developing nations like India, most of the centers still lack the availability of ultrasound machines especially in the operating rooms.

has been advised as an alternative to ultrasound-guided TAP block as it is less time consuming and does not need extra equipments. This study was done to compare the efficacy of both the techniques.

Despite ultrasound guidance, the identification of muscle planes can be challenging in some cases. Owen et al¹⁶ described a new approach: TAP block under direct vision in open surgery concluding that the risks of visceral trauma which were more with conventional approaches could be prevented with this technique. Following this report Chetwood et al¹⁷ described a laparoscopic-guided TAP block approach during laparoscopic nephrectomy and suggested that safety, time, and profit were the main advantages of this approach. They also demonstrated efficient pain relief, reduced narcotic use, and shorter hospital stays in these patients. According to our knowledge in English literature, limited studies have been published comparing the analgesic efficacy of ultrasound-guided approach versus laparoscopic approach.

In addition, correct deposition of local anesthetics in the TAP through ultrasound guidance is a skill associated with a learning curve. We recommend the use of laparoscopy-assisted TAP blocks in providing postoperative analgesia especially in centers lacking availability of an ultrasound machine in the operating room.

REFERENCES

1. McGreevy JM, Goodney PP, Birkmeyer CM, Finlayson SR, Laycock WS, Birkmeyer JD. A prospective study comparing the complication rates of laparoscopic and open ventral hernia repairs. *Surg Endosc* 2003 Nov;17(11):1778-1780.
2. DeMaria EJ, Moss JM, Sugerma HJ. Laparoscopic intraperitoneal polytetrafluoroethylene (PTFE) prosthetic patch repair of ventral hernia. *Surg Endosc* 2000 Apr;14(4):326-329.
3. Carbajo MA, Martin delOlmo JC, Blanco JI, de la Cuesta C, Toledano M, Martin F, Vaquero C, Inglada L. Laparoscopic treatment vs open surgery in the solution of major incisional and abdominal wall hernias with mesh. *Surg Endosc* 1999 Mar;13(3):250-252.
4. Olmi S, Magnone S, Erba L, Bertolini A, Croce E. Results of laparoscopic versus open abdominal and incisional hernia repair. *JLS* 2005 Apr-Jun;9(2):189-195.
5. Gray H. *Anatomy of the human body*. 12th ed. New York: Bartleby.com; 2000. pp. 211-213.
6. Walter CJ, Maxwell-Armstrong C, Pinkney TD, Conaghan PJ, Bedford N, Gornall CB, Acheson AG. A randomised controlled trial of the efficacy of ultrasound guided transversus abdominis plane (TAP) block in laparoscopic colorectal surgery. *Surg Endosc* 2013 Jul;27(7):2366-2372.
7. Sinha A, Jayaraman L, Punhani D. Efficacy of ultrasound guided transversus abdominis plane block after laparoscopic bariatric surgery: a double blind, randomized, controlled study. *Obes Surg* 2013 Apr;23(4):548-553.
8. De Oliveira GS Jr, Castro-Alves LJ, Nader A, Kendall MC, McCarthy RJ. Transversus abdominis plane block to ameliorate postoperative pain outcomes after laparoscopic surgery: a meta-analysis of randomized controlled trials. *Anesth Analg* 2014 Feb;118(2):454-463.
9. Ekmekçi P, Kazak Bengisun Z, Kazbek BK, Han S, Tüzüner F. Ultrasound guided TAP block for the treatment of postoperative prolonged pain—an alternative approach. *Agri* 2012;24(4):191-193.
10. Abdallah FW, Chan VW, Brull R. Transversus abdominis plane block: a systematic review. *Reg Anesth Pain Med* 2012 Mar-Apr;37(2):193-209.
11. Magee C, Clarke C, Lewis A. Laparoscopic TAP block for laparoscopic cholecystectomy: description of a novel technique. *Surgeon* 2011 Dec;9(6):352-353.
12. Johns N, O'Neill S, Ventham NT, Barron F, Brady RR, Daniel T. Clinical effectiveness of transversus abdominis plane (TAP) block in abdominal surgery: a systematic review and meta-analysis. *Colorectal Dis* 2012 Oct;14(10):e635-e642.
13. White PF. The changing role of non-opioid analgesic techniques in the management of postoperative pain. *Anesth Analg* 2005 Nov;101(5 Suppl):S5-S22.
14. Charlton S, Cyna AM, Middleton P, Griffiths JD. Perioperative transversus abdominis plane (TAP) blocks for analgesia after abdominal surgery. *Cochrane Database Syst Rev* 2010 Dec;12:CD007705.
15. Fields AC, Gonzalez DO, Chin EH, Nguyen SQ, Zhang LP, Divino CM. Laparoscopic-assisted transversus abdominis plane block for post operative pain control in laparoscopic ventral hernia repair: a randomized controlled trial. *J Am Coll Surg* 2015 Aug;221(2):462-469.
16. Owen DJ, Harrod I, Ford J, Luckas M, Gudimetla V. The surgical transversus abdominis plane block—a novel approach for performing an established technique. *BJOG* 2011 Jan;118(1):24-27.
17. Chetwood A, Agrawal S, Hrouda D, Doyle P. Laparoscopic assisted transversus abdominis plane block: a novel insertion technique during laparoscopic nephrectomy. *Anaesthesia* 2011 Apr;66(4):317-318.
18. Jankovic Z, Ahmad N, Ravishankar N, Archer F. Transversus abdominis plane block: how safe is it? *Anesth Analg* 2008 Nov;107(5):1758-1759.