

Electrophysiological Improvement Pattern in Patients with Carpal Tunnel Syndrome by Ultrasonic Therapy

¹Mohit Kataruka, ²Rajesh Pramanik, ³Pallab Das, ⁴Rathindranath Haldar

ABSTRACT

Introduction: Carpal tunnel syndrome (CTS) was effectively treated by lots of conservative management that includes splints, exercise, different types of heat modality like ultrasonic therapy (UST), etc. This is our humble attempt to explore and find out electrophysiological improvement pattern after treatment with UST in CTS. This analytical study was conducted at the Department of Physical Medicine and Rehabilitation (PMR), Institute of Post Graduate Medical Education and Research (IPGMER), SSKM Hospital, Kolkata, West Bengal, India, from January 15, 2012 to July 15, 2013.

Materials and methods: After getting Institutional Ethical Committee clearance, patients with symptoms of nerve compression at wrist were included in the study group according to inclusion and exclusion criteria. Ultrasound treatment was administered 15 minutes per session for 15 days to the palmar carpal tunnel area at a frequency of 1 MHz and intensity of 1.0 W/cm², pulsed mode, with a transducer of 5 cm². The patients were examined after intervals of 2, 4, and 8 weeks postintervention.

Results: The results of our study suggest that there was marked improvement in all the clinical parameters. The same significant improvement was also found in electrophysiological parameter.

Conclusion: Ultrasonic therapy is one of the effective modalities of treatment for CTS.

Keywords: Carpal tunnel syndrome, Ultrasonic therapy, NCS.

How to cite this article: Kataruka M, Pramanik R, Das P, Haldar R. Electrophysiological Improvement Pattern in Patients with Carpal Tunnel Syndrome by Ultrasonic Therapy. *Indian J Phy Med Rehab* 2017;28(3):106-109.

Source of support: Nil

Conflict of interest: None

INTRODUCTION

Carpal tunnel syndrome is the most common compressive neuropathy in the upper extremity that usually

presents with numbness, paresthesias, weakness, and atrophy of intrinsic hand muscles. Over the years, CTS was effectively treated by lots of conservative management that includes splints, exercise, different types of heat modality like UST, etc.¹ Ultrasonic therapy is an important treatment modality in the treatment of CTS. Ultrasound treatment within the range of 0.5 to 2.0 W/cm² may have the potential to induce various biophysical effects within the tissue. It may accelerate the healing process in the damaged tissue.² Ultrasound treatment facilitates the recovery from nerve compression due to its anti-inflammatory effect. Effects of UST on electrophysiological values are not clear, as ultrasound produces its greatest heating effect on deeper tissue and that nerve is heated. Increased local blood flow induced by ultrasound treatment may contribute to nerve regeneration or recovery nerve conduction in compression neuropathy.^{1,3}

With the invention of newer instruments like electrophysiological studies, an early diagnosis of CTS is relatively easy with more sensitivity and specificity. Lots of criteria are also freely available in the standard textbook and literature to diagnose CTS electrophysiologically.⁴ But there is paucity of literature regarding electrophysiological improvement pattern due to treatment of deep heat like UST. Last but not the least, there are little evidences available comparing the clinical symptomatology and functional improvement pattern in this clinical entity. This is our humble attempt to explore and find out electrophysiological improvement pattern after treatment with UST in CTS.

Objective

The objective of this study was to observe the electrophysiological changes due to UST in CTS.

MATERIALS AND METHODS

This analytical study was conducted at the Department of PMR, IPGMER, SSKM Hospital, Kolkata, India, from January 15, 2012 to July 15, 2013. After getting Institutional Ethical Committee clearance, patients with symptoms of nerve compression at wrist were included in the study group according to the following inclusion and exclusion criteria.

¹Major, ^{2,3}Associate Professor, ⁴Professor and Head

¹Department of Sports Medicine, Military Hospital, Khadakwasla NDA, Pune, Maharashtra, India

^{2,4}Department of Physical Medicine and Rehabilitation, Institute of Post Graduate Medical Education & Research, Kolkata, West Bengal, India

Corresponding Author: Rajesh Pramanik, Flat 3A, "Digantika" 453 Dumdum Park, Kolkata 700055, India, e-mail: rpramanik2000@yahoo.com

Inclusion Criteria

- Unilateral CTS for more than 3 months
- Age between 18 and 65 years

Exclusion Criteria

- Bilateral CTS
- Age less than 18 years and more than 65 years
- Diabetes, hypothyroidism, acromegaly, rheumatoid arthritis, pregnancy
- History of trauma
- Constant numbness, loss of sensation, or thenar atrophy lasting longer than 1 year
- Patients with bleeding disorder

Methods

After getting Ethical Committee clearance, patients who fulfilled the above criteria for selection were selected. After taking the consent from the patients, prefixed pro forma was filled up by taking detail history, clinical examination, and electrophysiological examination.


Patients were educated regarding management protocol, proper positioning of hand, advice to do nerve gliding exercise, and advice to use orthosis, vitamin B12 (1500 µg) for 3 weeks, and tablet paracetamol 500 mg twice daily for 7 days. Apart from the above, patients received UST. The patients were examined after intervals of 2, 4, and 8 weeks postintervention.

Study Tools

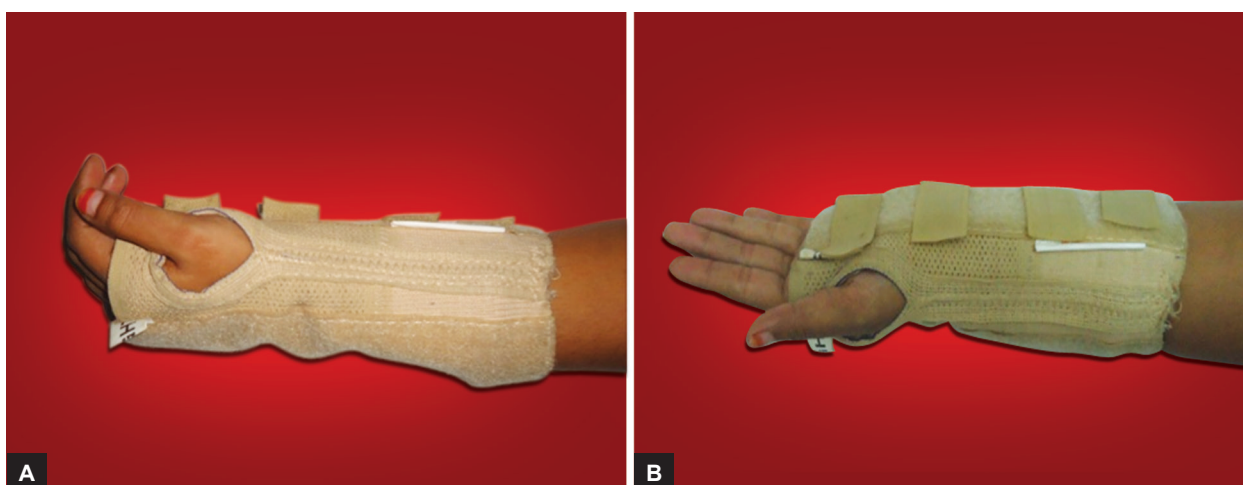
- Nerve conduction study machine (RMS EMG EP MARK II)
- UST machine

Ultrasonic Therapy

Ultrasound treatment was administered 15 minutes per session to the palmar carpal tunnel area at a frequency of 1 MHz and intensity of 1.0 W/cm², pulsed mode, with a transducer of 5 cm² and with aquasonic gel as the couplant. A total of 15 ultrasound treatments were performed once a day, five times a week, for 3 weeks (Figs 1 to 3).⁵



Figs 1A and B: Procedure of UST in CTS patient



Figs 2A and B: Diagram of static wrist hand orthosis used in our patients

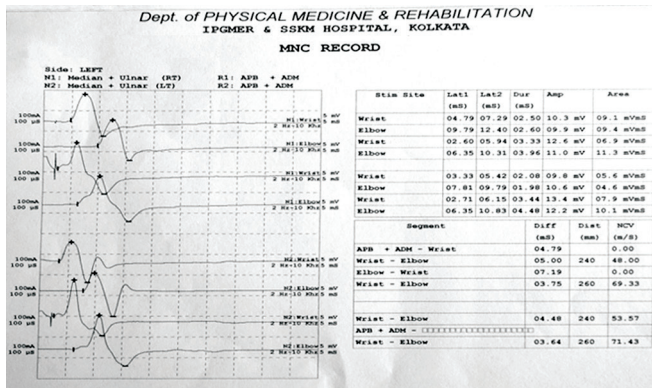


Fig. 3: Nerve conduction study of one of the patients

RESULTS AND ANALYSIS

After collecting all data, we analyzed all numerical data by statistical tools.

For statistical analysis we used the following software:

- Statistica version 6 (Tulsa, Oklahoma: StatSoft Inc., 2001)
- GraphPad Prism version 5 (San Diego, California: GraphPad Software Inc., 2007)

All numerical data were compared between groups by Student's independent sample t-test when they were normally distributed and Mann-Whitney test if otherwise. The chi-square test/Officer' exact test was employed for intergroup comparison of categorical variability. All analysis was two-tailed and $p < 0.05$ was considered statistically significant.

In our study, age and latency parameters were normally distributed, but others were not normally distributed.

Sex Distribution

Table 1 depicts the sex distribution of the study population.

Table 1: Sex distribution of the study population

	Female	Male	Total
UST	32	3	35
Row %	91.43	8.57	

Hand Involvement

Table 2 depicts the hand distribution of the study population.

Clinical and Electrophysiological Parameters

Table 3 depicts the changes in different clinical and electrophysiological parameters over time.

DISCUSSION

Carpal tunnel syndrome, the most common entrapment neuropathy of upper limb, is one of the most commonly treated clinical entity in the Department of PMR. In our study conducted at IPGMER over a period of 18 months from January 15, 2012 to July 15, 2013, we looked for the efficacy of UST in patients with CTS affecting unilateral hand. After getting Ethical Committee clearance, we included a total of 35 patients (previously we included 50 patients in UST group, unfortunately 15 dropped out in subsequent visit).

At the beginning of this study, we see that, mostly, females in their middle age with mean age of fifth decade were affected. In our study, dominant hand (mostly right hand) was more commonly affected with ratio of right to left being 74.29 and 25.71% respectively.

The results of our study suggest that there was marked improvement in all the clinical parameters. The same significant improvement was also found in electrophysiological parameter. The clinical and electrophysiological improvement was seen not only at the end of the treatment but also they were maintained at the end of 8 weeks. In our study, improvement of phalen and visual analog scale (VAS) were seen throughout the study, and it was

Table 2: Hand distribution of the study population

	Right hand	Left hand	Total
UST	26	9	35
Row %	74.29	25.71	

Table 3: Changes in different clinical and electrophysiological parameters over time

Parameters	0 wk	2 wk	4 wk	8 wk	p^{0-2}	p^{0-4}	p^{0-8}	p^{2-4}	p^{2-8}	p^{4-8}
Phalen	24.86	48.71	66.71	85.43	**	***	***	*	***	NS
VAS	7.34	4.71	3.34	2.34	**	***	***	*	***	NS
SSS	3.14	3.02	2.80	2.35	**	***	***	***	***	***
FSS	2.90	2.72	2.44	2.10	**	***	***	***	**	***
M_LAT	7.62	7.50	7.36	7.18	NS	NS	*	NS	NS	NS
LatMotM-U	2.96	2.82	2.70	2.50	NS	NS	*	NS	NS	NS
LatSenM-U	1.27	1.17	1.02	1.04	NS	***	***	*	NS	NS

* $p < 0.05$; ** $p < 0.01$; *** $p < 0.001$; NS: Nonsignificant; FSS: Functional severity score; SSS: Symptom severity score; M_LAT: Mean of median motor latency; LatMotM-U: Mean of difference of median and ulnar motor latency; LatSenM-U: Mean of difference of median and ulnar sensory latency

persistent at the end of this study, though the improvement was mainly up to 4 weeks and there was not much improvement of phalen and VAS between 4 and 8 weeks. Bakhtiary and Rashidy-Pour⁶ by using UST of frequency of 1 MHz and an intensity of 1.0 W/cm², with pulsed mode duty cycle of 1:4 for 15 days, also got significant improvement in pain ($p < 0.001$) at the end of treatment and at 4 weeks time.

Baysal et al⁵ got significant improvement in pain at the end of the treatment and also at 8 weeks follow-up ($p < 0.05$) by using UST for 15 minutes per session for 15 days to the palmar carpal tunnel area at a frequency of 1 MHz and intensity of 1.0 W/cm², pulsed mode 1:4, which was very well corroborating with our finding.

For functional and symptom severity score, both the parameters show significant improvement with time. Baysal et al⁵ in their study also got $p < 0.05$ at 8 weeks by using UST, nerve gliding exercise, and splinting. They found significant improvement in functional status score and symptom severity score at the end of the treatment immediately and at 8 weeks follow-up. Ebenbichler et al⁷ also got satisfactory improvement of symptoms in 68% (23/34) of the wrists receiving UST at the end of the treatment series. We also got similar type of result by using UST for 3 weeks.

In our study, there was improvement in electrophysiological values over time by UST. The change of median motor latency and difference of median and ulnar motor latency from 0 to 8 weeks were significant and others were not in case of patients treated with UST. Bakhtiary et al⁶ got similar result using 1 MHz and an intensity of 1.0 W/cm², with pulsed mode duty cycle of 1:4. Oztas et al⁸ had shown that UST has definitively better role compared with placebo using UST in CTS showing clinical improvement in all parameters and decreased motor nerve conduction velocity and increased motor distal latency (MDL). Ebenbichler et al⁷ also found significant decrease in median motor latency ($p < 0.001$) at the end of treatment and after 6 months by using UST for 15 minutes for 20 days, 1 MHz with intensity of 1.0 W/cm², pulsed mode 1:4.

In our study, improvement in difference of median and ulnar sensory latency was significant between 2 to 4 and 8 weeks in patients with CTS using UST, but significant changes in median motor latency and difference in median and ulnar motor latency occurred only between 0 and 8 weeks. Baysal et al⁵ and Ebenbichler et al⁷ in their study using UST for CTS found median

sensory distal latency was significantly decreased at the end of the treatment and also at 8 weeks follow-up ($p < 0.05$). A significant improvement was not recorded in median MDL at the end of the treatment and at 8 weeks follow-up ($p > 0.05$). We have got similar results in our study.

Limitations

- *Lack of control group:* In our study there was no control group.
- *Short study period:* More information regarding duration of action of UST can be achieved if the study could be conducted for a longer period.

CONCLUSION

Ultrasonic therapy is one of the effective modalities of treatment for CTS. It has definite role not only in improving symptoms but also in causing electrophysiological improvement in patients of CTS.

REFERENCES

1. Bilgici A, Ulosoy H, Kuru O, Cantruck F. The comparison of ultrasound and local steroid injection plus splinting in the treatment of carpal tunnel syndrome: a randomized controlled trial. *Bratisl Lek Listy* 2010 Jan;11(12):659-665.
2. Amirlak, B.; Upadhyaya, K.; Ahmed, O.; Wolff, T.; Tsai, T.; Scheker, L. Median nerve entrapment. *Internet Communication*. 2010. [cited 2011 Oct 24].
3. Binder A, Hodge G, Greenwood AM, Hazelman BL, Page Thomas DP. Is therapeutic ultrasound effective in treating soft tissue lesions? *BMJ (Clin Res Ed)* 1985 Feb;290(6467):512-514.
4. Bengtson, KA.; Brault, JS.; Gerber, LH. Hand disorders. In: Frontera WR, DeLisa J, Gans B, et al, editors. *DeLisa's physical medicine and rehabilitation principles and practice*. 5th ed. Philadelphia (PA): Lippincott Williams & Wilkins; 2010. pp. 937-939.
5. Baysal O, Altay Z, Ozcan C, Ertem K, Yologlu S, Kayhan A. Comparison of three conservative treatment protocols in carpal tunnel syndrome. *Int J Clin Pract* 2006 Jul;60(7):820-828.
6. Bakhtiary AH, Rashidy-Pour A. Ultrasound and laser therapy in the treatment of carpal tunnel syndrome. *Aust J Physiother* 2004;50(3):147-151.
7. Ebenbichler GR, Resch KL, Nicolakis P, Wiesinger GF, Uhl F, Ghanem AH, Fialka V. Ultrasound treatment for treating the carpal tunnel syndrome: randomised "sham" controlled trial. *BMJ* 1998 Mar;316(7133):731-735.
8. Oztas O, Turan B, Bora I, Karakaya MK. Ultrasound therapy effect in carpal tunnel syndrome. *Arch Phys Med Rehabil* 1998 Dec;79(12):1540-1544.