

## CASE REPORT

# Left Atrial Myxoma with an Unusual Origin near Right Pulmonary Vein

<sup>1</sup>Vandana Bhardwaj, <sup>2</sup>Neeti Makhija, <sup>3</sup>Amolkumar Bhoje, <sup>4</sup>Kamal K Chitara

## ABSTRACT

Atrial myxoma is the most frequent intracardiac tumor, accounting for nearly 50% of benign cardiac tumours in adults. We present here a rare case report of a solitary left atrial myxoma attached to the left atrial wall near the origin of the right pulmonary vein. The stalk of tumor was not attached to the interatrial septum, which is the most common site of attachment. Instead, it was attached on the wall of left atrium adjacent to the interatrial septum. Surgical exploration confirmed its attachment in the left atrium near the origin of right upper pulmonary vein.

**Keywords:** Intracardiac tumor, Left atrial myxoma, Transesophageal echocardiography.

**How to cite this article:** Bhardwaj V, Makhija N, Bhoje A, Chitara KK. Left Atrial Myxoma with an Unusual Origin near Right Pulmonary Vein. *J Perioper Echocardiogr* 2017;5(1):31-33.

**Source of support:** Nil

**Conflict of interest:** None

## INTRODUCTION

Myxoma is the most common intracardiac neoplasm accounting for 25% of all cardiac tumors. The pedunculated mass is usually attached to the interatrial septum in fossa ovalis region with a stalk.<sup>1,2</sup> We present here a rare case report of a solitary left atrial myxoma attached to the left atrial wall near the origin of the right upper pulmonary vein.

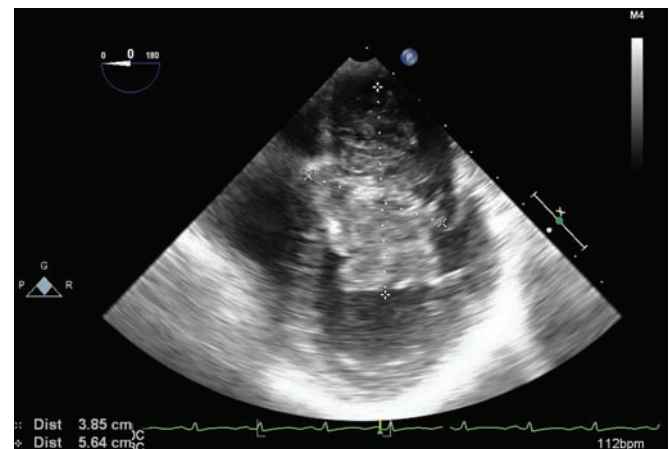
## CASE REPORT

A 40-year-old female was admitted in the hospital with dyspnea on exertion and palpitations for the past 5 months. The chest X-ray posteroanterior view revealed mild enlargement of cardiac silhouette with normal pulmonary vascular markings. Transthoracic echocardiography (TTE) revealed a large (63 × 20 mm) pedunculated mass in left atrium with a ball valve effect across mitral

valve. A severe mitral regurgitation and moderate mitral stenosis (mean gradient 6 mm Hg) was noted on TTE. Patient was taken for emergency left atrial mass excision because of the risk of systemic embolization and mitral flow obstruction.

Patient was stable hemodynamically with baseline heart rate 90 to 95 beats per minute, arterial blood pressure 100/56 mm Hg, respiratory rate 24/min, and oxygen saturation 99% on room air. After induction of anesthesia, transesophageal echocardiography (TEE) was performed using X7-2t Philips ultrasound probe and ultrasound machine (Philips iE33 Model, Bothell, WA, USA). The midesophageal four-chamber view revealed a single large (56 × 38 mm), nonhomogeneous, pedunculated mass in left atrium (Fig. 1, Video 1). The mass was causing obstruction to mitral valve inflow with a peak gradient 18 mm Hg (Fig. 2). However, the mitral valve was normal in morphology. The interatrial septum was found to be intact with no attachment to the left atrial mass in midesophageal four-chamber view and modified bicaval view (Fig. 3, Video 2). After tilting the probe to right side from the midesophageal four-chamber view, we were able to visualize the stalk of tumor mass in the wall of left atrium adjacent to the interatrial septum (Fig. 4, Video 3).

After systemic heparinization, patient was put on cardiopulmonary bypass (CPB) under mild hypothermia



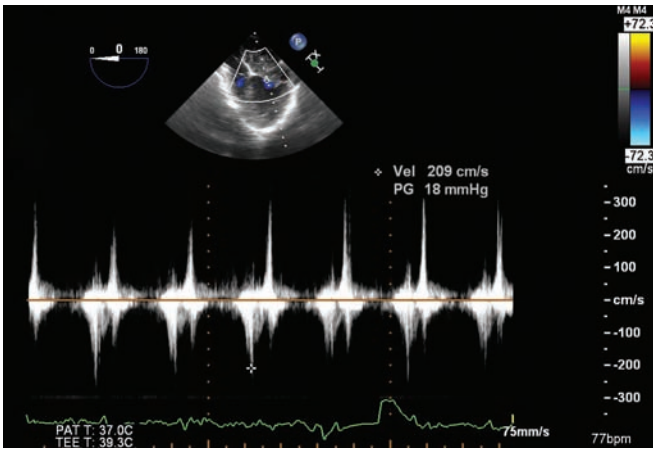
**Fig. 1:** Two-dimensional midesophageal four-chamber view at 0° angle showing a large, solitary (38 × 56 mm), irregular mass arising from left atrium and extending into left ventricle through mitral valve. LA: Left atrium; LV: Left ventricle; RA: Right atrium; RV: Right ventricle

<sup>1,4</sup>Senior Resident, <sup>2</sup>Professor, <sup>3</sup>Assistant Professor

<sup>1,2,4</sup>Department of Cardiac Anesthesia, All India Institute of Medical Sciences, New Delhi, India

<sup>3</sup>Department of Cardiothoracic and Vascular Surgery, All India Institute of Medical Sciences, New Delhi, India

**Corresponding Author:** Neeti Makhija, Professor, Department of Cardiac Anesthesia, All India Institute of Medical Sciences New Delhi, India, Phone: +919810452292, e-mail: neetimakhija@hotmail.com



**Fig. 2:** Continuous wave Doppler interrogation showing obstruction across mitral valve inflow (peak gradient 18 mmHg) in two-dimensional midesophageal four-chamber view at 0° angle

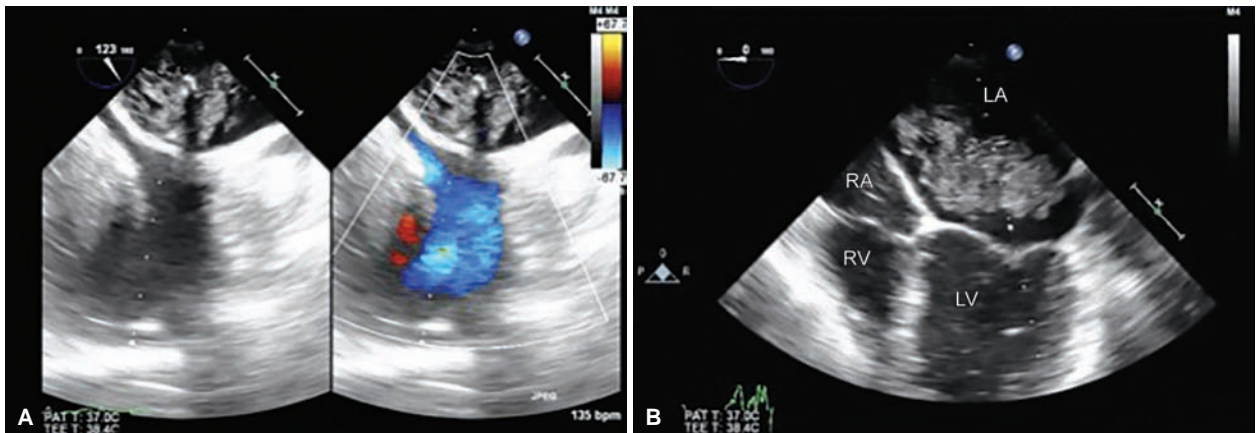
and diastolic arrest. The opening of right atrium and excision of interatrial septum at fossa ovalis revealed attachment of tumor mass adjacent to the origin of right upper pulmonary vein. However, the mass was not obstructing

the pulmonary venous flow. The pulmonary artery was soft on palpation. The left atrial mass was thus excised, leaving the adjacent left atrial wall and pulmonary vein unexcised. However, the attachment site of myxoma to the left atrial wall was cauterized to prevent recurrence. After excision of left atrial mass, saline test demonstrated mild to moderate mitral regurgitation. However, the mitral leaflet coaptation was good.

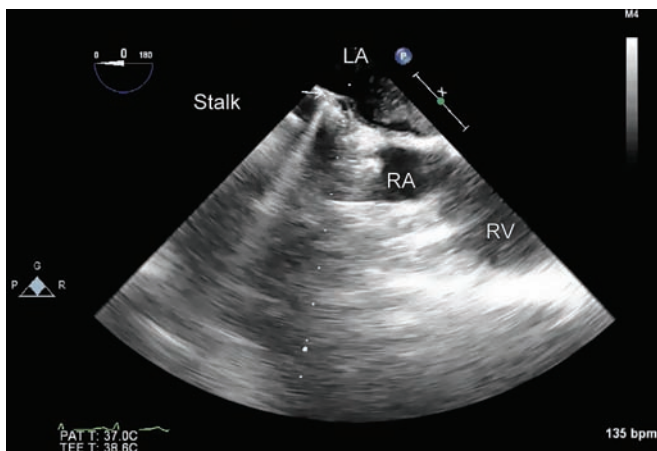
After coming off bypass, moderate mitral regurgitation (vena contracta width 3.9 mm) was noticed on TEE examination (Fig. 5). However, leaflet coaptation and valve morphology were normal. The pulmonary venous flow was also found to be normal. Post-CPB period was uneventful. Patient was shifted to intensive care unit for elective ventilation and extubated after 4 hours.

### DISCUSSION

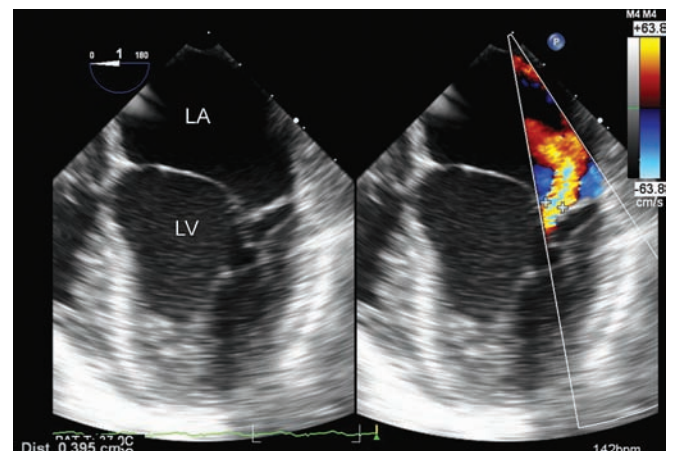
Atrial myxoma is the most frequent intracardiac tumor, accounting for nearly 50% of benign cardiac tumours in adults. The pedunculated mass most commonly arises



**Figs 3A and B:** (A) Two-dimensional midesophageal modified bicaval view at 120° angle. (B) Two-dimensional midesophageal four-chamber view at 0° angle. Note the left atrial myxoma is not attached to interatrial septum. LA: Left atrium; LV: Left ventricle; RA: Right atrium; RV: Right ventricle



**Fig. 4:** Two-dimensional midesophageal four-chamber view at 0° angle modified (probe tilted to the right). Left atrial myxoma stalk is not attached to the interatrial septum but is seen arising from adjacent wall of LA. LA: Left atrium; RA: Right atrium; RV: Right ventricle



**Fig. 5:** Two-dimensional midesophageal four-chamber view at 0° angle, showing moderate mitral regurgitation after excision of left atrial myxoma. LA: Left atrium; LV: Left ventricle; RV: Right ventricle

from undifferentiated cells in the fossa ovalis and adjoining endocardium. Most of the myxomas are located in the left atrium (75%) or right atrium (20%). Sometimes, these myxomas can be found in the ventricles, aorta, pulmonary artery, vena cava, or other organs.<sup>1-4</sup> They are heterogeneous in composition, consisting of areas with hemorrhage, necrosis, fibrosis, calcification, and cyst formation. Typically, these myxomas are pedunculated with a stalk attached to the interatrial septum at fossa ovalis region. However, in various case reports, their attachment to mitral leaflet, left atrial appendage, and left atrial area adjacent to anterior mitral leaflet has been reported.<sup>5-7</sup>

Earlier, coronary angiography was used to diagnose all cardiac myxomas, but now its role is limited to coronary evaluation in elderly patients. Computerized tomography and magnetic resonance imaging can locate the tumor and identify their relation to adjacent cardiac and thoracic structures. However, echocardiography is the modality of choice as it can visualize all cardiac structures and assess valve functions. Intraoperative TEE permits detailed evaluation of cardiac mass. The location of tumor, number, dimensions, echogenic pattern, point of tumor attachment, and any embolus or mitral valve obstruction can be assessed prior to CPB. This can aid in finalizing surgical plan. After surgical excision, TEE can identify any residual mass, damage to adjacent cardiac structures, or mitral regurgitation.<sup>8,9</sup>

In our case, pre-CPB TEE evaluation revealed a large, solitary, pedunculated, nonhomogeneous mass in the left atrium. The stalk of tumor was not attached to the interatrial septum, which is the most common site of attachment. Instead, it appeared to be attached on the surface wall of left atrial cavity. Evaluation of pulmonary vein was missed because of lack of time and urgency for surgical excision. Surgical exploration confirmed its attachment in the left atrium near the origin of right upper pulmonary vein. The surgeon excised LA mass through conventional right atrial septostomy. However, in this case LA mass could have been approached through left atrium itself, as the stalk was not attached to the interatrial septum. Since the exact site of attachment of stalk on TEE could not be pinpointed, and also the left

atrium was small and unsuitable for left atrial approach, the surgeon proceeded with usual right atrial approach. After surgical excision, there was no residual mass and right pulmonary venous flow was normal. Mild to moderate mitral regurgitation was present, but coaptation of leaflets was normal.

## CONCLUSION

Although cardiac myxoma is usually attached to the interatrial septum, unusual sites of attachments like left atrial wall adjacent to right pulmonary vein should also be kept in mind during TEE examination. This can aid in finalizing surgical plan for complete tumor excision without postoperative complications.

## REFERENCES

1. Anandan PK, Baligar B, Bhatt P, Manjunath CN, Dhanalakshmi C. Multiple cardiac myxomas—unusual locations—flowers in the cardia. *BJMMR* 2015 Apr;8(3):253-258.
2. Magdaleno O, Marjan B. Left atrial myxoma—a case report. *J Cardiol Curr Res* 2016;5(2):00153.
3. Diaz A, Di Salvo C, Lawrence D, Hayward M. Left atrial and right ventricular myxoma: an uncommon presentation of a rare tumour. *Interact Cardiovasc Thorac Surg* 2011 Apr;12(4):622-623.
4. Croti UA, Braile DM, Souza AS, Cury PM. Right ventricle and tricuspid valve myxoma. *Rev Bras Cir Cardiovasc* 2008 Jan-Mar;23(1):142-144.
5. Makhija N, Irpachi K, Chowdhury UK, Kiran U. Unusual attachment of left atrial myxoma: role of transesophageal echocardiography. *JOPE* 2016;4(1):30-33.
6. Chen MY, Wang JH, Chao SF, Hsu YH, Wu DC, Lai CP. Cardiac myxoma originating from the anterior mitral leaflet. *Jpn Heart J* 2003 May;44(3):429-434.
7. Turhan S, Kilikap M, Candemir B, Berkalp B, Eren NT, Akgun G. Three unusual myxomas originating from the left atrial appendage: a case report. *J Am Soc Echocardiogr* 2005 Jun;18(6):694.
8. Oliver, WC.; Mauermann, WJ.; Nuttall, GA. Uncommon cardiac diseases. In: Kaplan JA, Reich DL, Savino JS, editors. *Kaplan cardiac anesthesia—the echo era*. 6th ed. St. Louis (MO): Elsevier; 2011. p. 675-678.
9. Oliveira R, Branco L, Galrinho A, Abreu A, Abreu J, Fiarresga A, Mamede A, Ramos R, Leal A, Pinto E, et al. Cardiac myxoma: a 13-year experience in echocardiographic diagnosis. *Rev Port Cardiol* 2010 Jul-Aug;29(7):1087-1100.