

Fetal Intrauterine Transfusion

Amitha Indersen

ABSTRACT

Fetal anemia is a recognizable and treatable condition. It requires identification of the etiology to plan a comprehensive treatment strategy. Fetal blood transfusions help tide over crisis and avert fetal cardiovascular decompensation or deterioration due to the anemia. Based on the cause and the fetal condition, the timing and requirement for transfusion are determined. At present, noninvasive monitoring with fetal middle cerebral arterial Doppler peak systolic velocity is the standard for monitoring and diagnosis of fetal anemia.

Keywords: Anemia, Fetal, Intrauterine, Middle cerebral arterial peak systolic velocity, Transfusion.

How to cite this article: Indersen A. Fetal Intrauterine Transfusion. *World J Anemia* 2017;1(1):27-29.

Source of support: Nil

Conflict of interest: None

INDICATIONS

The primary indication for an intrauterine blood transfusion is fetal anemia, and the etiology for the same is most commonly maternal autoimmune sensitization to fetal Rh antigens. With the widely prevalent availability and used of Rh antibody, the incidence of such maternal sensitizations has reduced, but, nevertheless, they do happen due to delayed administration, insufficient dosage, or unrecognized early pregnancy bleeds and maternofetal hemorrhages.¹

The other cause, though much rarer, would be maternal sensitization to other fetal blood antigens like the Kell, Duffy, or Lewis antibodies.

Fetal infections causing suppression of the fetal erythropoiesis are known to occur with parvo B19 virus infection. The suppression can sometimes be severe, but often transient; if the crisis is tided over with timely transfusions, most fetuses do well.

Rarely does one come across a fetus that is anemic due to a fetomaternal hemorrhage *per se*. Again, this is a situation where if there is no ongoing hemorrhage, a timely transfusion helps save the fetus.

- Twin to twin transfusion syndrome, twin anemia polycythemia sequence
- Fetal or placental tumors or arteriovenous malformations
- Monochorionic twins – cotwin demise, twin anemia polycythemia sequence
- Chromosomal abnormalities – Trisomy 21 with transient abnormal myelopoiesis
- Metabolic abnormalities – e.g., glucose-6-phosphate dehydrogenase deficiency, Gaucher disease, Fanconi anemia.

RISKS OF INTRAUTERINE TRANSFUSION

- Preterm labor, preterm premature rupture of the membranes
- Fetal distress
- Cord accidents
- Chorioamnionitis
- Formation of new red cell antibodies
- Graft *vs* host reaction.

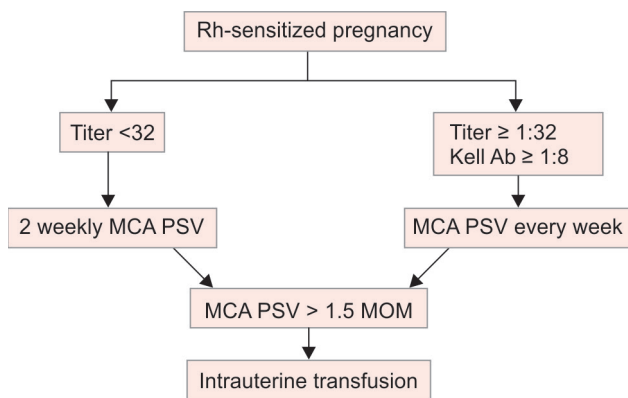
WHEN DO WE TRANSFUSE?

The Rh-sensitized mother or the anemic fetus is followed up with serial evaluation of the middle cerebral artery (MCA) peak systolic velocity (PSV) from around 16 weeks onward.^{2,3} At present, non-invasive monitoring with fetal MCA doppler peak systolic velocity is the standard for monitoring and diagnosis of fetal anaemia.⁴ The potential for fetal anemia is from when the antibody levels exceed 15 IU/mL (titer 1:128). It is better to refer the patient for follow-up with a fetal medicine specialist from when the antibody titer is 10 IU/mL (titer 1:64).⁵⁻⁷ In a nonsensitized mother, the assessments are done at the time of her usual antenatal scans or 4-weekly. However, in a sensitized mother, the follow-up must be more intensive, and it is recommended to monitor them with 2-weekly measurements of the MCA PSV. The PSV measured should be converted to the multiples of the median (MOM) for the gestational age. A value of 1.25 should caution us about the possibility of evolving fetal anemia, and a value to 1.5 MOM is the red alert sign or the action line where an intrauterine transfusion (IUT) is to be considered.^{8,9} Besides the MCA PSV, the fetus is also examined for the development of signs of fetal hydrops and the cardiac function.^{10,11} It is preferable to transfuse the fetus before it becomes hydropic with signs of vascular decompensation (Flow Chart 1).

Consultant

Department of Fetal Medicine, Apollo Cradle Hospitals Hyderabad, Telangana, India

Corresponding Author: Amitha Indersen, Consultant Department of Fetal Medicine, Apollo Cradle Hospitals Hyderabad, Telangana, India, e-mail: amitha.indersen@yahoo.com

Flow chart 1: Antenatal monitoring of fetal anemia⁵⁻⁷

PROCEDURE

The procedure of fetal IUT is usually a daycare procedure, though an overnight observation can be recommended to err on the side of caution. If the patient is on any anti-coagulant, that is to be stopped 2 days prior. No specific preparation of the patient is required and can be done in the office setting.

The blood to be transfused must be O negative, irradiated, leukocyte-depleted double-packed blood. It is preferable that the hematocrit of the donor blood is as close to 80 as possible so that the volume of blood that has to be transfused is kept to a minimum, to prevent cardiac overload of the fetus.

The procedure is done under local anesthesia for the mother. It is preferable that the fetus is paralyzed with injection pancuronium/vecuronium/atracurium intramuscularly or into the umbilical vessels. Fetal analgesia can be added with injection fentanyl.

The choice of site for transfusion is chosen most often depending on the fetal position and technical accessibility with the needle. It can be intraumbilical (umbilical vein), into the intrahepatic part of the portal vein, or intraperitoneal.

Intraumbilical: The transfusion can be done into the free loop, but preferably near the placental or fetal insertion where it is likely to be more stable. The risk in intraumbilical transfusion is that, as it not well supported, the cord or the fetus can move and the needle can slip out, counterpuncture, or tear the vessel. It can cause bradycardia in case of intra-arterial puncture.

Intrahepatic portal vein transfusion: This is the preferred site as the portal vein is well supported by the liver, and the chances of needle displacement and vessel damage are minimal.

Intraperitoneal: This is the preferred site in very early pregnancies, where the fetal vessels are very thin. Intraperitoneal transfusion can also be given as a topup to intravascular transfusion because the intraperitoneal blood is slowly absorbed into the circulation and helps

prolong the interval to the next transfusion. The risk here is that if excess volume is transfused, it can cause tamponade on the heart and bradycardia.

A 20 G spinal needle can be used. At the start of the procedure, a sample of the fetal blood is taken for assessment of the hematocrit, complete blood count, blood group, and Rh typing. Depending on the fetal and donor hematocrits, the volume of blood to be transfused is calculated using the formulae as below:

Volume of blood to be transfused = (donor hematocrit – desired hematocrit)/(desired hematocrit – fetal hematocrit) × fetal blood volume

$$\text{Fetal blood volume} = 1.046 \times \text{fetal weight in gm} \times 0.14$$

In case of intraperitoneal transfusion, the volume is calculated as period of gestation in weeks – 20 × 10 mL.

The transfusion is done at a rate of 3 to 5 mL per minute until the calculated volume of blood is transfused. The aim is to achieve a hematocrit of 40 to 45% at the end of the transfusion. A final sample of fetal blood is taken to check the final hematocrit. This will help time the next transfusion.

FOLLOW-UP

Following the first transfusion, the expected average daily decline in the fetal hematocrit will be 0.4 gm/dL/day, 0.3 gm/dL/day after the second, and 0.2 gm/dL/day after the third transfusion. In case a combined intravascular and intraperitoneal transfusion has been done, the rate of decline in hematocrit is slower, around 0.01 vs 1.14% per day in case of intravascular transfusion alone.

It is desirable to keep the fetal hematocrit >25%. The subsequent transfusions can be planned based on the MCA PSV increase. The action line here would be at 1.32 MOM rather than 1.5 MOM.

At around 36 to 37 weeks, the mother can be started on Tab. phenobarbital 30 mg TDS, and delivery can be planned a week later. Beyond 34 weeks, the risk of the procedure may outweigh delivery, and a critical judgment for repeat transfusion at this point maybe required.¹²

Postnatal hyperbilirubinemia and suppressed erythropoiesis need special care in the early neonatal life.¹³ The hyperbilirubinemia is expected to be more severe due to higher level of hemolysis of the transfused red blood cells and the conjugating capacity of the neonatal liver. Many of these babies require phototherapy and exchange transfusions.

REFERENCES

1. ACOG practise bulletin. Prevention of Rh D alloimmunisation. Number 4, May 1999, Clinical management guidelines for obstetrician-gynaecologists. Int J Gynaecol Obstet 1999 Jul;66(1):63-70.

2. Abel DE, Grambow SC, Brancazio LR, Hertzberg BS. Ultrasound assessment of the fetal middle cerebral artery peak systolic velocity: a comparison of the near-field versus far-field vessel. *Am J Obstet Gynecol* 2003 Oct;189(4):986-989.
3. Sallout BI, Fung KF, Wen Sw, Medd LM, Walker MC. The effect of fetal behavioural states on middle cerebral artery peak systolic velocity. *Am J Obstet Gynecol* 2004 Oct;191(4):1283-1287.
4. Thilaganathan.B et al, *Am J OG* 1988.
5. Non-invasive diagnosis by doppler ultrasonography of fetal anaemia due to maternal red cell alloimmunization by Giancario Mari et al. *N England Journal of Medicine* 2000; 342:9-14.
6. Divakaran TG, Waugh J, Clark TJ, Khan KS, Whittle MJ, Kilby MD. Noninvasive technique to detect fetal anaemia due to red blood cell alloimmunisation: a systematic review. *Obstet Gynecol* 2001 Sep;98(3):509-517.
7. Oepkes D, Seaward PG, Vandenbussche FP, Windrim R, Kingdom J, Beyene J, Kanhai HH, Ohlsson A, Ryan G. Doppler ultrasound versus amniocentesis to predict fetal anaemia. *N Engl J Med* 2006 Jul;335:156-164.
8. Klumper FJ, van Kamp IL, Vandenbussche FP, Meerman RH, Oepkes D, Scherjon SA, Eilers PH, Kanhai HH. Benefits and risks of fetal red cell transfusion after 32 weeks gestation. *Eur J Obstet Gynecol Reproduct Biol* 2000 Oct;92(1):91-96.
9. van Kamp IL, Klumper FJ, Oepkes D, Meerman RH, Scherjon SA, Vandenbussche FP, Kanhai HH. Complications of intrauterine intravascular transfusion for fetal anaemia due to maternal red-cell alloimmunisation. *Am J Obstet Gynecol* 2005 Jan;192(1):171-177.
10. Zimmerman R, Carpenter RJ Jr, Durig P, Mari G. Longitudinal measurement of peak systolic velocity in the fetal middle cerebral artery for monitoring pregnancies complicated by red cell alloimmunisation: a prospective multicentre trial with intention to treat. *BJOG* 2002 Jul;109(7):746-752.
11. Mari G. Middle cerebral artery peak systolic velocity: is the standard of care for the diagnosis of fetal anaemia? *J Ultrasound Med* 2005 May;24(5):697-702.
12. Schumacher B, Moise KJ. Fetal transfusion for red blood cell alloimmunisation in pregnancy. *Obstet Gynecol* 1996 Jul;88(1):137-150.
13. De Boer IP, Zeestraten EC, Lopriore E, van Kamp IL, Kanhai HH, Walther FJ. Paediatric outcome in rhesus haemolytic disease treated with and without intrauterine transfusion. *Am J Obstet Gynecol* 2008 Jan;198(1):54.e1-54.e4.