

CASE REPORT

Rehabilitation of a Patient with Completely Edentulous Maxillary Arch using “All on 4” Concept of Implantation

¹K Harshakumar, ²Nimisha B Abraham, ³S Lylajam, ⁴V Prasanth

ABSTRACT

Treatment options for insufficient ridge morphology includes the use of short implants, vertical ridge augmentation procedures, or cantilever prostheses in completely edentulous patients. Due to the less predictable long-term prognosis associated with the above-mentioned procedures, the “All on 4” technique was proposed for the rehabilitation in edentulous jaws. The All on 4 treatment concept meets the patient requirements with an immediately loaded fixed prosthesis supported by four implants. This article depicts a clinical report in which an “All on 4” implant treatment is done with delayed loading protocol due to inadequate primary stability obtained.

Keywords: All on 4, Delayed loaded implants, Nobel Biocare.

How to cite this article: Harshakumar K, Abraham NB, Lylajam S, Prasanth V. Rehabilitation of a Patient with Completely Edentulous Maxillary Arch using “All on 4” Concept of Implantation. *Int J Prosthodont Restor Dent* 2017;7(2):66-70.

Source of support: Nil

Conflict of interest: None

INTRODUCTION

Clinicians are faced with the growing need to offer solutions to the edentulous population due to an increase in their life expectancy^{1,2} and to fabricate prostheses that provide a replacement for the loss of natural teeth, allowing optimum satisfaction and improved quality of life. The routine treatment has been conventional dentures. Dissatisfaction in patients using dentures may be due to pain, areas of discomfort, poor denture stability, and difficulties in eating as well as lack of or compromised retention capability.³ Clinical studies have reported that patients with dentures have shown only a marginal improvement in the quality of life when compared with implant therapy.⁴ However, in cases with inadequate ridge height, short implants, vertical augmentation

procedure, or cantilever prostheses are the various treatment options. Due to the less predictable long-term prognosis associated with the above-mentioned procedures, the “All on 4” technique was proposed for the rehabilitation in edentulous jaws.

The “All on 4” concept is based on the placement of four implants (two axial and two tilted implants) in the anterior part of fully edentulous jaws to support a provisional, fixed, and immediately loaded full-arch prosthesis. Combining tilted and straight implants for supporting fixed prostheses can be considered a viable treatment modality resulting in a more simple and less time-consuming procedure, with significantly less morbidity, in decreased financial costs and a more comfortable postsurgical period for the patients.^{5,6}

This article narrates a case report in which a patient with completely edentulous maxillary arch was rehabilitated with a screw-retained hybrid prosthesis using an “All on 4” concept. However, the compromised bone quality in the maxillary arch precluded the immediate loading of implants due to its exiguous primary stability.

CASE REPORT

A healthy 70-year-old male patient reported to the Department of Prosthodontics, Government Dental College, Thiruvananthapuram, India, requiring a fixed prosthetic treatment in the maxillary arch and was edentulous for a period of 1 year (Fig. 1). The clinical examination revealed a completely edentulous maxillary arch and a Kennedy’s Class I edentulous mandibular arch. He was

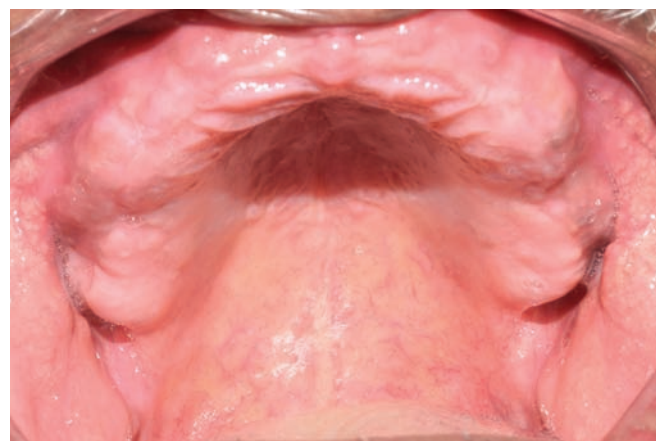


Fig. 1: Completely edentulous maxillary arch

¹Professor and Head, ²Postgraduate Student, ³Professor
⁴Associate Professor

¹⁻⁴Department of Prosthodontics, Government Dental College
Thiruvananthapuram, Kerala, India

Corresponding Author: Nimisha B Abraham, Postgraduate
Student, Department of Prosthodontics, Government
Dental College, Thiruvananthapuram, Kerala, India, Phone:
+917293683574, e-mail: newnimi@gmail.com

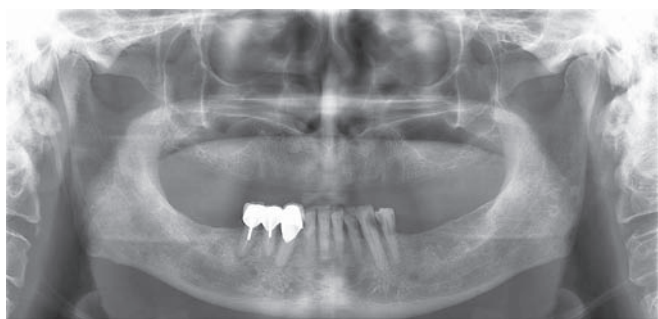


Fig. 2: Preoperative panoramic view

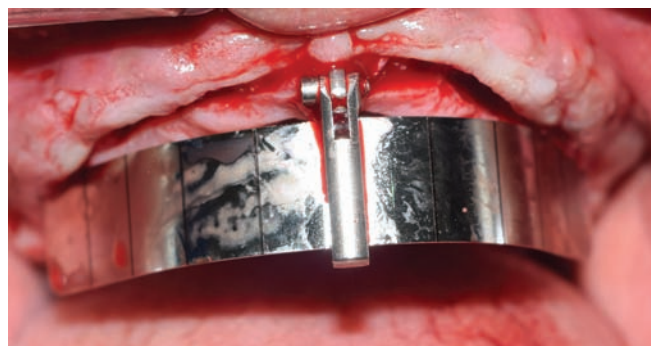


Fig. 3: "All on 4" guide in position

wearing a maxillary complete denture and a mandibular removable partial denture. Despite all the effort to make him comfortable with the existing denture, he desired a long-term definitive restorative option that would not interfere with his social life, improve his self-image, and provide overall comfort and practical function, which left us with the option of using implants. He was adamant about not wanting removable prosthetic appliances and also any prostheses on the mandibular arch.

Radiographic examination (both panoramic and cone-beam computed tomography) (Fig. 2) evinced normal trabecular pattern of both maxillary and mandibular arch with retained root remnant of maxillary left first premolar. In addition, a compromised alveolar bone height in the maxillary posterior region bilaterally was depicted. Upon complete examination, the maxilla was classified American College of Prosthodontists classification of Prosthodontic Diagnostic Index for Complete Edentulism Class I. Different treatment options were discussed including implant-supported overdenture and fixed detachable prosthesis. After consultation with the patient and the family, an implant-retained fixed detachable (hybrid) denture was opted for maxillary rehabilitation. An "All on 4" technique using conventional flap procedure with a standardized All on 4 guide for predictable and optimal positioning of the implant was planned. An informed consent was taken from the patient and ethical clearance was obtained prior to the beginning of surgical phase.

All the standard surgical protocols were strictly followed. The patient was started on an antibiotic course (Amoxicillin 500 mg three times daily for 5 days) 2 days prior to surgery. A supracrestal incision was made from the first molar area extending to the contralateral side. The anterior wall of the maxillary sinus was located bilaterally to serve as landmark for the placement of most distal implants. Implant placement was assisted by the "All on 4" surgical guide (Nobel Biocare). The guide was placed into a 2-mm osteotomy made at the midline of the maxilla, and the titanium band was contoured to follow the maxillary arch shape (Fig. 3). The guide allowed for optimal positioning, alignment, parallelism, and incli-

nation of the implants for subsequent anchorage and prosthetic support. Anterior implants were of dimension 4.3×15 mm and posterior implants of dimensions 4.3×13 mm (Nobel Active™). The platforms of the most distal implants were angled about 30° distally with the use of the "All on 4" guide and was planned to be placed 4 mm anterior to the anterior wall of the sinus. The root remnant of maxillary left first premolar was extracted 2 months prior to the surgery and this prevented the successful placement of the tilted distal implant on the left side in the prospective site due to the insufficient bone density. This accounted for the placement of implant in a further anterior position, i.e., the maxillary left canine region.

A manual surgical torque wrench (Nobel Biocare) was used to check the final torque of the implants following their placement. In order to allow for immediate functional loading, implants should withstand a minimum tightening torque of 35 Ncm. However, among the four implants, only the maxillary right-tilted implant could attain a torque of 35 Ncm and hence a 17° angled Multi-Unit Abutment™ (4-mm height) was connected and a multiunit healing cap was placed over it. Cover screws were placed on three implants with exiguous primary stability and a delayed loading protocol was followed. The surgical site was then sutured back (Fig. 4). The

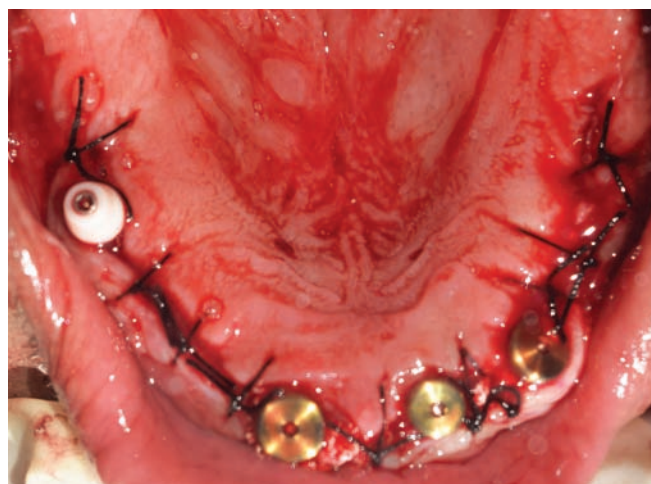


Fig. 4: Cover screw placed and suturing done

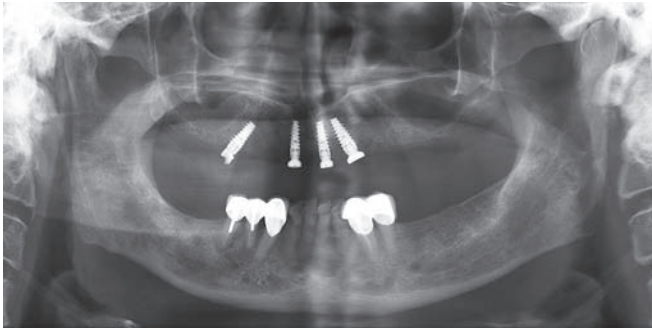


Fig. 5: Postoperative panoramic view following implant placement

patient was given oral hygiene instructions and a recall appointment was given after 2 weeks. 2 weeks later, the sutures were removed and a postoperative panoramic view was taken (Fig. 5). A conventional healing phase was recommended for these implants as the primary stability was inadequate.

Following a 6 months healing period, all the four implants were loaded with multiunit abutments (Fig. 6), subsequently prosthetic phase was initiated. Open tray multiunit impression copings were connected to the implants to commence the impression-making procedures. A custom self-cure acrylic resin open tray was fabricated and proper relief from the impression copings was confirmed. An autopolymerizing pattern resin (GC Pattern Resin, GC America, Inc.) was used to splint these impression copings to create a rigid frame to ensure accuracy (Fig. 7). An open tray impression was made using regular body polyvinyl siloxane impression material (3M ESPE Express™) (Fig. 8). Impression was removed from the mouth and temporary abutments (Nobel Biocare) were connected to the impression copings extraorally. This was then sent to the laboratory to fabricate a milled titanium framework. Once received, the framework was tried intraorally and checked for passivity. Tentative jaw relation and facebow transfer was performed using a temporary acrylic base made over the framework. Subsequent to the denture tooth setup, esthetics, phonetics, and occlusion were evaluated intraorally. A final hybrid denture was fabricated using heat cure acrylic

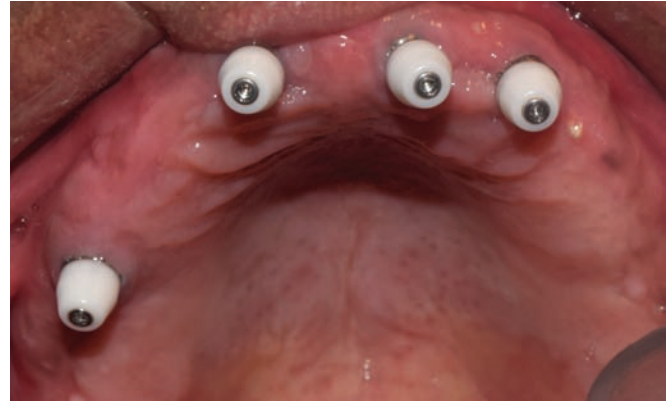

Fig. 6: Multiunit abutments *in situ* after the healing

resin (Ivoclar Vivadent SR Triplex Hot) (Fig. 9) and the finished prosthesis was inserted by torque tightening of the prosthesis retaining screws to 10 Ncm. Patient was reluctant to receive any treatment of the mandibular arch and hence remained partially edentulous. The patient was given oral hygiene instructions and scheduled for follow-up every month. A follow-up of 6 months was performed and there are no discernible clinical or radiographic changes around the implants. The patient was quite satisfied with the esthetics and functional outcome of the denture (Fig. 10).

DISCUSSION

In certain completely edentulous patients, implant-supported prosthetic treatment is unmanageable without complex techniques, such as nerve transposition and grafting in the posterior mandible. Moreover, vertical placement of implants in the anterior edentulous mandible entails cantilever lengths from 10 to 20 mm to provide the patient with esthetics and function. When cantilever spans exceeding 7 mm are planned, regardless of the number of implants, an optimal biomechanical environment should exist.^{7,8} In a biomechanically compromised

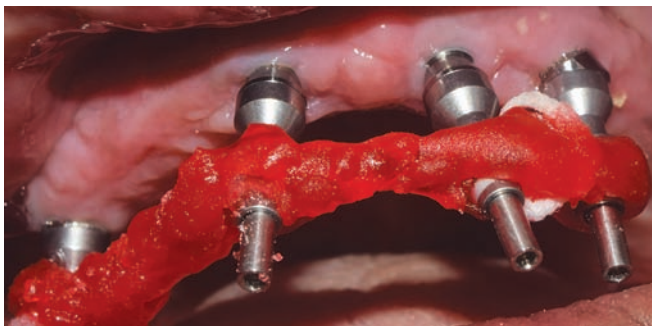


Fig. 7: Autopolymerizing pattern resin stabilizing the impression copings

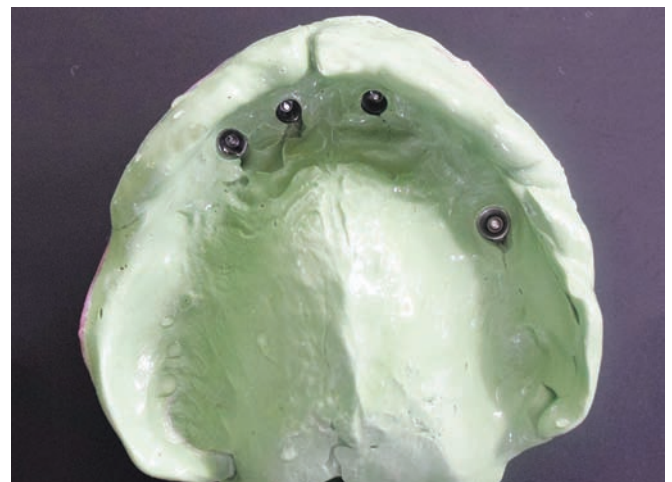

Fig. 8: Definitive impression

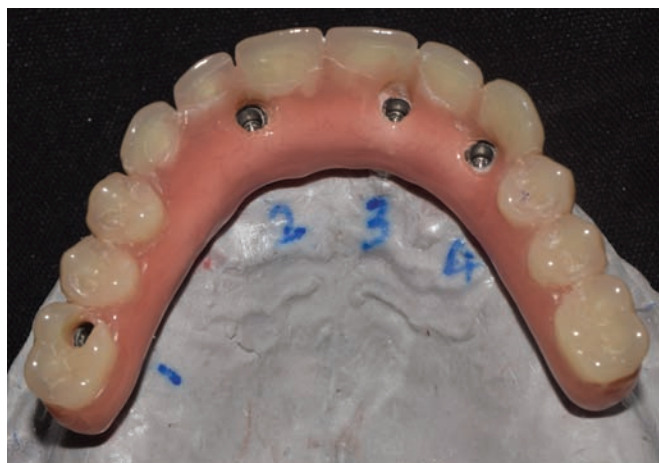

Fig. 9: Finished hybrid denture

environment, such as poor quality bone, the strain transmitted to the crestal bone can be reduced by increasing the anterior–posterior spread of the implants, placement of longer implants, and maximizing the number of implants.⁹⁻¹¹ Tilting of implants may also be advantageous in these conditions as it increases the interimplant space and reduces the cantilever length, thereby reducing the need for bone augmentation procedures.

The All on 4 treatment concept thus proved to be an excellent option, with its use of straight and angled multiunit abutments, which was developed to provide edentulous patients with an immediately loaded full arch restoration on only four implants – two placed vertically in the anterior, two placed at an angle of up to 45° in the posterior region. By tilting the two posterior implants, the bone-to-implant contact is enhanced, providing optimal bone support even with barely available bone volume. Additionally, tilting of implants in the maxilla permits improved anchorage in better quality anterior bone and bicortical anchorage in the cortical bone of the sinus wall and the nasal fossa. Tilting of the posterior implants also aids in avoiding vital structures, such as the mandibular nerve or the maxillary sinus, and results in a better distribution of implants along the alveolar crest, which optimizes load distribution and allows for a final prosthesis with up to 12 teeth.^{12,13} All on 4 treatment has been developed to maximize the use of available bone and allows immediate function. Overall, published data on the All on 4 concept reported cumulative survival rates between 92.2 and 100%.^{14,15}

CONCLUSION

The patient in this clinical report has been treated with four dental implants placed with the "All on 4" concept in the maxilla and a hybrid denture with a milled titanium framework. In spite of the exiguous primary stability obtained, a delayed loading protocol enhanced the bone

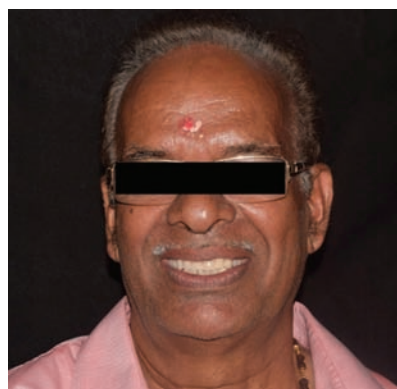


Fig. 10: Postoperative extraoral view

healing and success of the implants. He was followed up for 6 months and so far remains satisfied with the outcome of the treatment. There were no discernible clinical and radiographic changes around the dental implants. There have been no prosthetic complications, and the patient is scheduled for further follow-ups, mainly to determine the effectiveness of home oral care.

REFERENCES

1. World Medical Association Declaration of Helsinki. Ethical principles for medical research involving human subjects. *J Am Med Assoc* 2000;284:2043-3045.
2. Salvin, B. The business of implant dentistry. In: Babbush, C.; Hahn, J.; Krauser, J.; Rosenlicht, J., editors. *Dental implants: the art and science*. 2nd ed. St. Louis (MO): Saunders Elsevier; 2010. p. 7-13.
3. Heath MR. The effect of maximum biting force and bone loss upon masticatory function and dietary selection of the elderly. *Int Dent J* 1982 Dec;32(4):345-356.
4. Allen PF, McMillan AS. A review of the functional and psychosocial outcomes of edentulousness treated with complete replacement dentures. *J Can Dent Assoc* 2003 Nov;69(10):662.
5. Vega LG, Bilbao A. Alveolar distraction osteogenesis for dental implant preparation: an update. *Oral Maxillofac Surg Clin North Am* 2010 Aug;22(3):369-385.
6. Peñarrocha Diago M, Maestre Ferrín L, Peñarrocha Oltra D, Canullo L, Calvo Guirado JL, Peñarrocha Diago M. Tilted implants for the restoration of posterior mandibles with horizontal atrophy: an alternative treatment. *J Oral Maxillofac Surg* 2013 May;71(5):856-864.
7. Rodriguez AM, Aquilino SA, Lund PS, Ryther JS, Southard TE. Evaluation of strain at the terminal abutment site of a fixed mandibular implant prosthesis during cantilever loading. *J Prosthodont* 1993 Jun;2(2):93-102.
8. White SN, Caputo AA, Anderkvist T. Effect of cantilever length on stress transfer by implant-supported prostheses. *J Prosthet Dent* 1994 May;71(5):493-499.
9. Lekholm, U.; Zarb, GA. Patient selection and preparation. In: Branemark, PI.; Zarb, GA.; Albrektson, T., editors. *Tissue-integrated prosthesis: osseointegration in clinical dentistry*. Chicago: Quintessence; 1985. p. 199-209.
10. van Steenberghe D, Lekholm U, Bolender C, Folmer T, Henry P, Herrmann I, Higuchi K, Laney W, Linden U, Astrand P. Applicability of osseointegrated oral implants in the rehabilitation of partial edentulism: a prospective multicenter study on 558 fixtures. *Int J Oral Maxillofac Implants* 1990 Fall;5(3):272-281.

11. Tada S, Stegaroiu R, Kitamura E, Miyakawa O, Kusakari H. Influence of implant design and bone quality on stress/strain distribution in bone around implants: a 3-dimensional finite element analysis. *Int J Oral Maxillofac Implants* 2003 May-Jun;18(3):357-368.
12. Maló P, Rangert B, Nobre M. "All-on-Four" immediate-function concept with Brånemark system implants for completely edentulous mandibles: a retrospective clinical study. *Clin Implant Dent Relat Res* 2003 Mar;5 (Suppl 1):2-9.
13. Maló P, Rangert B, Nobre M. All-on-4 immediate-function concept with Brånemark system implants for completely edentulous maxillae: a 1-year retrospective clinical study. *Clin Implant Dent Relat Res* 2005;7 (Suppl 1):S88-S94.
14. Malo P, de Araujo Nobre M, Lopes A. The use of computer-guided flapless implant surgery and four implants placed in immediate function to support a fixed denture: preliminary results after a mean follow-up period of thirteen months. *J Prosthet Dent* 2007 Jun;97(6 Suppl):S26-S34.
15. Pomares C. A retrospective clinical study of edentulous patients rehabilitated according to the "all on four" or the "all on six" immediate function concept. *Eur J Oral Implantol* 2009 Spring;2(1):55-60.