

# Ectopic Adrenocortical Adenoma

<sup>1</sup>Alexander L Shifrin, <sup>2</sup>Min Zheng, <sup>1</sup>Jerome J Vernick

<sup>1</sup>Department of Surgery, Jersey Shore University Medical Center, Neptune, NJ, USA

<sup>2</sup>Department of Pathology, Jersey Shore University Medical Center, Neptune, NJ, USA

**Correspondence:** Alexander L Shifrin, Department of Surgery, Jersey Shore University Medical Center, 1945 State Route 33 Neptune, NJ-07754, USA, e-mail: ashifrin@meridianhealth.com

## ABSTRACT

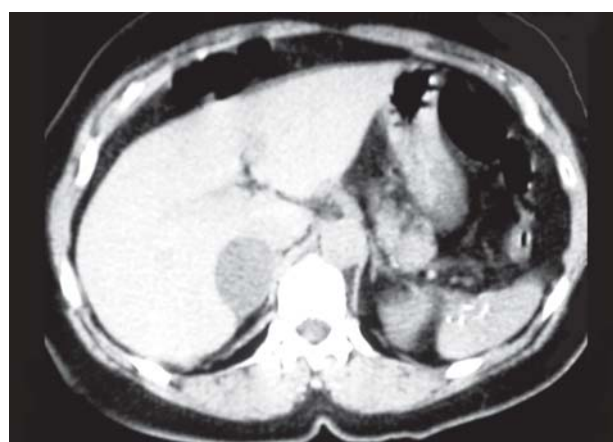
A 63-year-old female with an incidental right adrenal tumor identified on CT scan. MRI revealed a 5.4 × 3.9 × 2.9 cm “right adrenal mass” located under hepatic segment 5, displacing the gallbladder medially, negative on T2-weighted images. Her past medical history, physical examination and laboratory data were negative for functional adrenal tumor. Laparoscopic exploration revealed a large oval mass under the segment 5 of the liver, 4 cm superior, anterior and lateral in relation to the normally located right adrenal gland. Frozen section confirmed an adrenocortical neoplasm. Considering the unknown behavior of this mass, the normal appearing adrenal gland was removed. Pathology was consistent with benign adrenocortical adenoma and normal right adrenal gland. A finding of the right side retroperitoneal mass and a normally located adrenal gland is a part of the differential diagnosis of adrenocortical adenoma arising from the aberrant adrenal gland.

**Keywords:** Adrenal gland, Adrenocortical adenoma, Ectopic, Laparoscopic adrenalectomy.

## CASE REPORT

A 63-year-old female with a history of kidney stones was found, on routine follow-up CT scan, to have a partially obstructing calculus of the left distal ureter and an incidental right adrenal tumor. MRI revealed a “right adrenal mass” located under hepatic segment 5, displacing the gallbladder medially (Fig. 1). This was negative on T2-weighted images and measured 5.4 × 3.9 × 2.9 cm. She had no symptoms referable to adrenal hyperactivity. Her past medical history was significant for kidney stones and hypercholesterolemia. Past surgical history was significant for a thyroidectomy 25 years prior for multinodular goiter. On physical examination, she was not cushinoid. Vital signs were normal. There were no additional significant physical findings. Laboratory data was negative for pheochromocytoma, aldosteronoma and Cushing’s syndrome. Laparoscopic exploration was performed in the left lateral decubital position. Four ports were placed; the abdomen was explored, the liver was mobilized medially using a harmonic scalpel. At the location predicted by MRI, under segment 5 of the liver, 2 × 4 cm superior, anterior and lateral to the normally located right adrenal gland, the mass was identified. It was characterized by its oval shape, clearly defined capsule and almost no surrounding fatty tissue. Mobilization was accomplished using the harmonic scalpel. There was a communicating vein entering the vena cava directly that was thought to be the adrenal vein. The tumor was located anterior and lateral to the vena cava. After removal of the mass the cavity was re-evaluated, fatty tissue was gently dissected to confirm anatomy of the kidney and to complete hemostasis. About 2 cm inferior and deep in the retroperitoneal space, above the upper pole of the right kidney in the surrounding fat, we noticed yellow tissue consistent with a normal appearing adrenal gland

that was identified in its normal location. Frozen section confirmed an adrenocortical neoplasm of the removed “adrenal mass”. Considering the unknown behavior of this mass, and presence of the normal appearing adrenal gland in proximity to the ectopic adrenal tumor, the normal gland was removed as well. It was removed intact with surrounding fatty tissue. During dissection of the normal gland, we confirmed that there were no communications or vessels that were entering the ectopic adrenal tumor. Pathology was consistent with benign ectopic adrenocortical adenoma 6.3 × 4.0 × 2.2 cm in size. The right adrenal gland 4.5 × 2.0 × 0.8 cm in size with normal histology surrounded by fatty tissue was intact. The tumor cells of the ectopic adrenal tumor resembled zona fasciculate of the adrenal cortex, with no evidence of cellular atypia, significant mitotic activity, necrosis, invasive growth or lymphovascular invasion. The patient was discharged on the first postoperative day with no complications.



**Fig. 1:** MRI image of the right ectopic adrenal tumor, under the segment 5 of the liver

## DISCUSSION

Adrenocortical adenoma arising from aberrant adrenal gland is unusual. This case illustrates an adrenocortical adenoma initially presenting as a superiorly positioned adrenal tumor. The correct diagnosis is adenoma originating in ectopic adrenal tissue. Aberrant or ectopic adrenocortical tissue is found along the path of embryonic migration of adrenal cortical rests. As adrenal migration occurs, cortical tissue may separate leaving fragments of adrenal tissue in an ectopic location. Most, but not all, remain near the adrenal gland. Ectopic adrenal tissue has been reported in the testis, spermatic cord, broad ligament, kidney, retrocaval space, celiac region, lungs, central nervous system, colon, pancreas and gallbladder. The most common location of heterotopic adrenal tissue is in the area of the celiac axis (32%) and broad ligament (23%). It was reported that ectopic adrenal tissue may undergo malignant transformation or become hormonally functional.<sup>1,2</sup> There are few reported cases of ectopic adrenal tumors. Leibowitz et al presented delayed recurrence, four years after initial surgery of Cushing's syndrome due to development of new cortisol secreting adrenal tumor from ectopic adrenal. This was resected 14 years after the initial procedure.<sup>2</sup>

Accessory cortical masses are seen in approximately 50% of newborns. Most do not persist. Kirici et al reported a case of ectopically located adrenal gland in the right retrocaval space with compressive symptoms.<sup>3</sup>

An ectopic aldosterone secreting tumor was described in association with adrenocortical adenoma in the adrenal gland on the same side. The ectopic tumor was located in the retrocaval region, laterally to the body of the 12th thoracic vertebra.<sup>4</sup>

Ayala et al reported a case of a 63-year-old woman who presented with new-onset corticotropin-independent Cushing's syndrome and imaging studies showing normal adrenal glands and enlargement of a left pararenal nodule incidentally observed

4 years before the onset of symptoms. Surgical removal of the mass lead to resolution of the symptoms. Pathological exam confirmed adrenocortical adenoma in ectopic adrenal tissue.<sup>1</sup>

This case illustrates an adrenocortical adenoma initially presenting as a superiorly positioned adrenal tumor on the right side. Intraoperative findings were consistent with adrenocortical adenoma that was arising from the aberrant ectopic adrenal gland on the right side and above the normal right adrenal gland. Pathology was consistent with ectopic adrenal tumor that resembled zona fasciculata of the adrenal cortex, with no evidence of cellular atypia. Differential diagnosis between benign and malignant adrenal tumors by histology may be very difficult and surgical findings of the clearly defined margins without invasion is more important in predicting malignant potential of the tumor than just histological description. In our case, even that we did not see any extracapsular extension or invasion, regular follow-up with imaging studies is very important to confirm complete cure and absence of the recurrent or metastatic disease.

In conclusion, aberrantly located adrenal tumor could be part of the differential diagnosis of the upper abdominal mass.

## REFERENCES

1. Ayala AR, Basaria S, Udelsman R, Westra WH, Wand GS. Corticotropin-independent Cushing's syndrome caused by an ectopic adrenal adenoma. *J Clin Endocrinol Metab.* 2000 Aug;85(8):2903-06.
2. Leibowitz J, Pertsemliadis D, Gabrielove JL. Recurrent Cushing's syndrome due to recurrent adrenocortical tumor fragmentation or tumor in ectopic adrenal tissue? *J Clin Endocrinol Metab.* 1998 Nov;83(11):3786-89.
3. Kirici Y, Mas MR, Saglamkaya U, Oztas E, Ozan H. Accessory suprarenal gland: Report of a case. *Surg Radiol Anat Jun* 2001;23(3):201-03.
4. Mazza E, Papotti M, Durando R, Robecchi A, Camanni FJ. Ectopic aldosteronoma associated to another adrenocortical adenoma in the adrenal gland of the same side. *Endocrinol Invest.* 1995 Nov;18(10):809-12.