

Ludwig's Angina: Report of 40 Cases and Review of Current Concepts in Emergency Management in a Rural Tertiary Facility Teaching Hospital

¹M Ambikavathy, ²S Kumar

ABSTRACT

Objective: To review the current protocols and assess their efficacy in the emergency management of cases presenting with Ludwig's angina.

Materials and methods: A retrospective study of patients diagnosed with Ludwig's angina, admitted and treated in our institution between November 2007 and December 2012.

Results: There were 40 cases with 24 males (60%) and 16 females (40%), ages ranged between 16 and 80 years. Duration of symptoms was between 3 days and 2 weeks. The most common cause was dental infections seen in 23 cases (57.5%), one of them was a pregnant lady. Six were due to habitual tooth pricking with a broom stick (15%). In 3 patients it was due to submandibular duct stenosis secondary to calculi (7.5%). Five patients had diabetes as underlying disease (12.5%). Facial trauma contributed in 2 patients (5%) and in 1 patient it was due to carcinoma buccal mucosa (2.5%). All the patients were treated with systemic broad spectrum antibiotics, intravenous fluids, and analgesics. Twenty patients (50%) underwent tracheostomy with surgical decompression through small incisions under local/general anesthesia. Ten patients (25%) were subjected to incision and drainage with subsequent removal of the diseased teeth. Ten patients (25%) were managed conservatively with antibiotics, analgesics, and under close supervision for airway compromise. There were no complications recorded and no mortality.

Conclusion: Ludwig's angina is a life-threatening surgical emergency. Early diagnosis and immediate surgical intervention can save lives. The appropriate use of parenteral antibiotics complemented with airway protection and surgical decompression remains the standard treatment protocol in advanced cases of Ludwig's angina.

Keywords: Ludwig's angina, Management, Protocols, Tracheostomy.

How to cite this article: Ambikavathy M, Kumar S. Ludwig's Angina: Report of 40 Cases and Review of Current Concepts in Emergency Management in a Rural Tertiary Facility Teaching Hospital. *Int J Head Neck Surg* 2017;8(1):11-14.

^{1,2}Associate Professor

¹Department of General Surgery, Vydehi Institute of Medical Sciences & Research Centre, Bengaluru, Karnataka, India

²Department of General Medicine, Vydehi Institute of Medical Sciences & Research Centre, Bengaluru, Karnataka, India

Corresponding Author: M Ambikavathy, Associate Professor Department of Surgery, Vydehi Institute of Medical Sciences & Research Centre, Bengaluru, Karnataka, India, Phone: +919980337428, e-mail: ambikaashri67@gmail.com

Source of support: Nil

Conflict of interest: None

INTRODUCTION

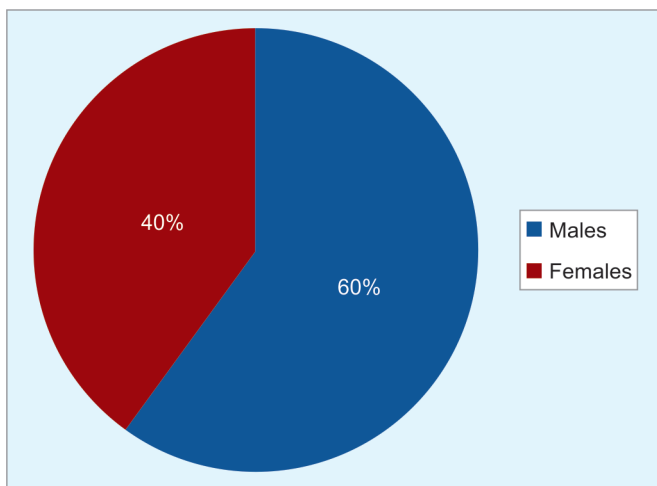
Ludwig's angina is named after the German physician Wilhelm Friedrich Von Ludwig who first described this condition in 1836.¹ It is a fatal surgical emergency and is typically a spreading cellulitis of the face, neck spaces, and floor of the mouth with brawny swelling of the submandibular region with elevation and posterior displacement of the tongue causing airway obstruction.^{2,3} The other symptoms are fever, malaise, chills, dysphagia, trismus, and difficulty in breathing.⁴ The microbiological analysis includes poly microbial pattern of Gram-positive and Gram-negative organisms.⁵

MATERIALS AND METHODS

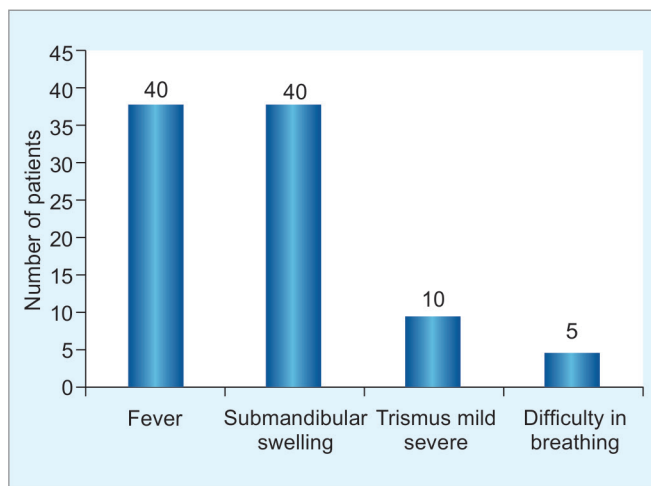
Forty patients diagnosed and admitted with Ludwig's angina from November 2007 to December 2012 were reviewed. Written informed consent was obtained from the patients and their attendants for surgical intervention. The data were collected from the institution's Medical Record Section with respect to demographics, etiology, duration of illness, clinical signs, symptoms and diagnosis, radiological/ultrasound reports, medical/operative details, blood investigations, pus culture sensitivity, outcome, morbidity and mortality/complications, and follow-up after discharge and were then tabulated and analyzed using simple frequencies and descriptive statistics. Tracheostomy was performed under local anesthesia in all 20 patients followed by incision and drainage under general anesthesia. All the patients were covered with systemic broad spectrum antibiotics and analgesics followed by change in drugs according to culture sensitivity report. Microbiology analysis of pus reported poly microbial infection and most common were *Staphylococcus* and *Streptococcus* species.

RESULTS

Forty patients presented with Ludwig's angina: 24 males (60%) and 16 females (40%), one of which was a primipara with 30 weeks gestation (Graph 1 and Table 1). Features of



Graph 1: Genderwise distribution of cases of Ludwig's angina



Graph 2: Symptoms at presentation

Table 1: Sex distribution

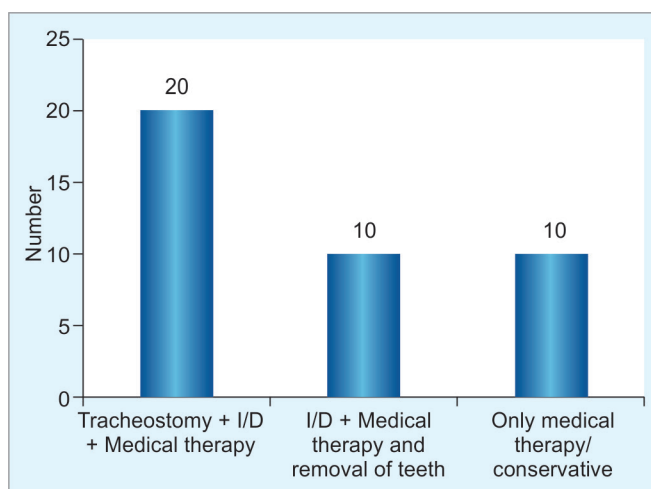
Male patients	Female patients
24 (60%)	16 (40%)

Table 2: Symptoms at presentation

Fever	40 (100%)
Submandibular swelling	40 (100%)
Trismus mild to severe	10 (25%)
Difficulty in breathing	5 (12.5%)

Table 3: Age wise distribution

Age	Patients (%)
1–10 years	1 (2.5%)
11–20 years	2 (5%)
21–30 years	8 (20%)
31–40 years	2 (5%)
41–50 years	9 (22.5%)
51–60 years	15 (37.5%)
61–70 years	2 (5%)
>71 years	1 (2.5%)



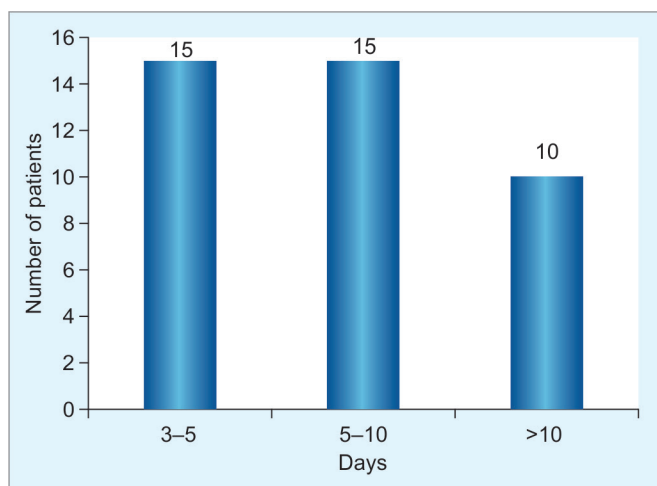
Graph 3: Various procedures performed

Table 4: Various procedures performed

Tracheostomy + Incision and drainage + medical therapy	20 (50%)
Incision and drainage + medical therapy and removal of teeth	10 (25%)
Only medical therapy/conservative	10 (25%)

fever, generalized weakness, swelling of submandibular region extending to the submental and neck region were commonly seen in all the patients (Table 2, and Graph 2). Patients ranged from < 10 years to >71 years, with 15 (37.5%) patients were in fifth to sixth decade of life while 9 (22.5%) in the 40-50 years of age (Table 3). Though trismus ranging from mild to severe degree was seen in 20 patients (50%) who were managed with tracheostomy, in 10 patients (25%) only incision and drainage covered with antibiotics and analgesics sufficed, while 10 patients (25%) recovered with medical management (Table 4, and Graph 3). Tracheostomy care was note worthy and it was removed as and when patients did well. The duration of patients from the time of symptoms to admission to hospital was from 3 days to 2 weeks. Dental infection was the common cause of Ludwig's angina, in the form of impacted third molar teeth, caries tooth, tooth pricking,

and periodontitis. The most common cause was dental infection seen in 23 cases (57.5%), one of them was a pregnant lady. Six were due to habitual tooth pricking with a broom stick (15%). In three patients it was due to submandibular duct stenosis secondary to calculi (7.5%). Five patients had diabetes as underlying disease (12.5%). Facial trauma contributed in two patients (5%) and in one patient it was due to carcinoma buccal mucosa (2.5%) (Table 5). There were no complications in any of the patients and all were discharged 8 to 10 days postoperatively (Table 6, and Graph 4). The underlying causes were addressed. Diabetics and hypertensives were managed appropriately by the experienced physician. The patients who were managed conservatively recovered well and were discharged on the



Graph 4: Duration of hospital stay

Table 5: Various causes of Ludwig's angina

Dental abscess	10 (25%)
Periodontitis	6 (15%)
Impacted molar	7 (17.5%)
Foreign body/tooth prick	6 (15%)
Duct stones	3 (7.5%)
Carcinoma cheek	1 (2.5%)
Facial trauma	2 (5%)
Diabetes	5 (12.5%)

3rd to 5th day. During the follow-up period, all the patients reported improvement and had no sequelae.

DISCUSSION

Ludwig's angina is usually seen due to odontogenic infections (80%), such as impacted second and third molars, and dental abscess. The word angina is derived from the Greek word "ankhon" meaning "strangling." The submandibular space is the primary site of infection in Ludwig's; this space is subdivided by the mylohyoid muscle into sublingual space superiorly and submaxillary space inferiorly. The

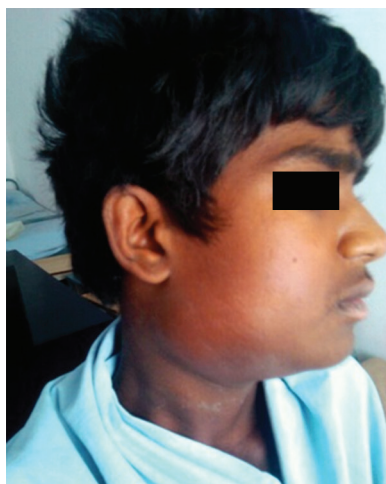

Fig. 1: Twelve-year-old boy with right submandibular swelling

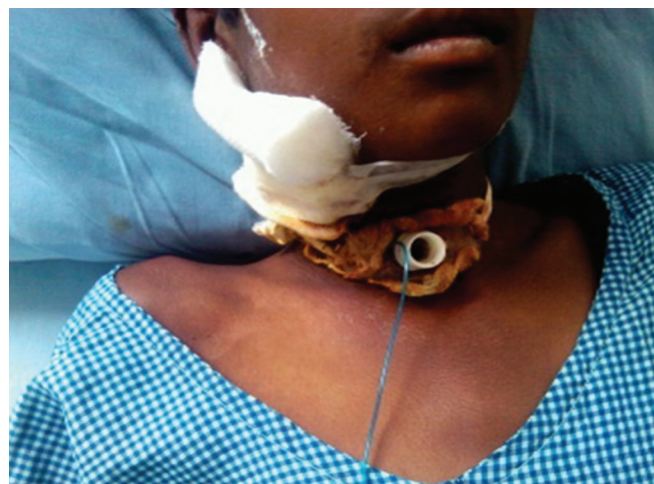

Fig. 2: Tracheostomy and incision and drainage performed

Table 6: Duration of hospital stay

Age	No. of patients
3-5 days	15
5-10 days	15
>10 days	10

infection from the root of the molars penetrates the mylohyoid ridge such that it spreads directly to the submandibular, sublingual, and submental spaces and contiguously to the pharyngo maxillary and retropharyngeal spaces leading to rapid and profound neck swelling encircling the airway. Since the infection and edema are limited by deep cervical fascia, mandible, and hyoid, the tongue and floor of the mouth is elevated and posteriorly displaced with compromise in airway leading to asphyxia and fatal outcome.¹⁻³ Therefore, standard protocols call for aggressive surgical intervention as mandatory with tracheostomy, surgical decompression, and broad spectrum antibiotics. Ludwig's angina has a male preponderance with sporadic incidents in children^{3,4} which similar in our study however we had three children one in 1-10 years of age and two in 11-20 years (Tables 1 and 3 and Figs 1 and 2).

Although reports have documented early presentation of patients, we have seen a delay from 3 to 15 days after onset and we presume that it could be due to the distance from rural referring centers, ignorance, self-medication/drug abuse, ignorance, and use of native medicine/quacks. Miller et al⁵ stressed on the airway management based on clinical, followed by early contrast-enhanced computerized tomography (CT) with an 89% accuracy, 95% sensitivity, and 80% specificity.^{6,7} Neff et al recommend awake fiberoptic intubation to secure airway if CT showed airway deviation and narrowing.⁵ In our study, clinical examination complemented by ultrasound and chest X-ray are the investigations done prior to interventions as most of the patients had already presented late and were in respiratory distress. Ludwig's angina has a

recorded mortality of 8 to 10% occurring due to hypoxia or asphyxia rather than sepsis.

Recent reports encourage conservative line of management in selected patients over conventional surgical management. Larawin et al⁸ retrospectively studied 103 patients with deep neck infections from 1993 to 2005. Ludwig's angina was the most common infection in 38 (37%), 13 (34%) were managed successfully with medical therapy, and 4 patients (10%) required tracheostomy.^{9,10} A review of 29 cases over 9 years by Greenberg et al¹⁰ showed 21 (72%) were managed conservatively, 1 required emergency intubation, 7 (24%) were intubated using fiberoptic nasoendoscopy, and 1 (3%) required tracheostomy under local anesthesia. In our study also, 10 patients (25%) were managed conservatively.^{10,11} The management depends on the clinical assessment of the patient airway patency; surgical decompression, broad spectrum antibiotics, and analgesics are the mainstay in treating Ludwig's angina and the mortality has now dropped to 10%.¹²

CONCLUSION

Ludwig's angina is a fatal condition and early diagnosis and proper management suited to each individual can limit morbidity and mortality. Both surgical and medical management along with airway management, appropriate antibiotics, and close observation play equal roles in treating this condition. Computed tomography scan can complement the management protocols, especially in deep-seated collections.

REFERENCES

1. Moreland LW, Correy J, McKenzie R. Ludwig's angina. Report of a case and review of the literature. *Arch Intern Med* 1988 Feb;148(2):461-466.
2. Bansal A, Miskoff J, Lis RJ. Otolaryngologic critical care. *Crit Care Clin* 2003 Jan;19(1):55-72.
3. Saifelddeen K, Evans R. Ludwig's angina. *Emerg Med* 2004 Mar;21(2):242-243.
4. Spitalnic SJ, Sucov A. Ludwig's angina: case report and review. *J Emerg Med* 1995 Jul-Aug;13(4):499-503.
5. Miller WD, Furst IM, Sandor GK, Keller MA. A prospective blinded comparison of clinical examination and computed tomography in deep neck infections. *Laryngoscope* 1999 Nov;109(11):1873-1879.
6. Offenbacher S, Boggess KA, Murtha AP, Jared HL, Lief S, McKaig RG, Mauriello SM, Moss KL, Beck JD. Progressive periodontal disease and risk of very preterm delivery. *Obstet Gynaecol* 2006 Jan;107(1):29-36.
7. Marple BF. Ludwig angina: a review of current airway management. *Arch Otolaryngol Head Neck Surg* 1999 May;125(5):596-600.
8. Larawin V, Naipao J, Dubey SP. Head and neck space infections. *Otolaryngol Head Neck Surg* 2006 Dec;135(6):889-893.
9. Neff SP, Merry AF, Anderson B. Airway management in Ludwig's angina. *Anaesth Intensive Care* 1999 Dec;27(6):659-661.
10. Greenberg SL, Huang J, Chang RS, Ananda SN. Surgical management of Ludwig's angina. *ANZ J Surg* 2007 Jul;77(7):540-543.
11. Turner M, Aziz SR. Management of the pregnant oral and maxillofacial surgery patient. *J Oral Maxillofac Surg* 2002 Dec;60(12):1479-1488.
12. Williams AM, Southern SJ. Body piercing: to what depths? An unusual case and review of associated problems. *Plast Reconstr Surg* 2005 Mar;115(3):50e-54e.