

## REVIEW ARTICLE

# Congenital Scoliosis

Vinay Jasani

**ABSTRACT**

Congenital scoliosis is a scoliosis that occurs as a result of bony abnormalities that arise between 4 to 16 weeks of gestation. There are genetic and environmental factors involved in etiology. The majority of congenital vertebral anomalies are in the thoracic spine (64%).

The patients often have associated skeletal anomalies and can also be part of a syndrome. Skeletal, cardiac, genitourinary intraspinal abnormalities are most commonly found in association with congenital scoliosis.

The natural history seems to be related to the morphology of the bony site in the spine, and the patient's age. Congenital scoliosis usually progresses and often requires intervention. The aim of intervention is to achieve a flexible and balanced spine with normal truncal height and space available for lung ratio. Early intervention for scoliosis seems to be instrumental in trying to achieve these goals.

**Keywords:** Congenital, Hemivertebra, Scoliosis, Segmentation.

**How to cite this article:** Jasani V. Congenital Scoliosis. *J Postgrad Med Edu Res* 2017;51(2):95-102.

**Source of support:** Nil

**Conflict of interest:** None

**INTRODUCTION**

Congenital scoliosis is defined as scoliosis due to bony abnormalities of the spine present at birth. The abnormalities can result in asymmetrical growth of the spine and a progressive deformity.

The worldwide prevalence is cited at 0.5 to 1 per 1000 live births.<sup>1</sup> However, this is based on an analysis of chest radiographs taken for tuberculosis screening in the United States and is probably an underestimate, as congenital abnormalities of the rest of the spine were excluded.

Congenital scoliosis is associated with abnormalities of the genitourinary, cardiovascular, gastrointestinal, and respiratory systems as well as intraspinal and craniocervical abnormalities.

Consultant Spine Surgeon

Department of Trauma and Orthopedics, University Hospitals of North Midlands, Newcastle Road, Stoke on Trent, ST4 6QG United Kingdom

**Corresponding Author:** Vinay Jasani, Consultant Spine Surgeon, Department of Trauma and Orthopedics, University Hospitals of North Midlands, Newcastle Road, Stoke on Trent ST4 6QG, United Kingdom, Phone: +441782 679868, e-mail: vinay.jasani@uhnms.nhs.uk

Although a single cause is not defined, it is accepted that congenital scoliosis is due to a mutation of the precursor of the vertebral body (somite) in embryogenesis.<sup>2</sup> Segmentation of the precursor spine tissue is known as somitogenesis which occurs between 20 to 30 days of gestation with somites segmenting at 6 to 8 weeks. Congenital anomalies are felt to occur around this time; even before chondrification or ossification. Several studies have identified vertebral defects as early as 4 to 5 weeks gestation but interestingly not beyond 16 weeks.<sup>3</sup> Normal segmentation and formation of the definitive vertebral body anlage is felt to be related to the development of intersegmental artery.<sup>4</sup>

The majority of congenital curves involve the thoracic spine (64%) followed by thoracolumbar (20%), lumbar (11%), and lumbosacral (5%).

**ETIOLOGY**

A single cause has not been identified for congenital scoliosis. Both environmental factors and genetics are important in normal embryogenesis.

Environmental factors that can cause congenital vertebral anomalies include hypoxia. Low oxygen tension has created congenital vertebral anomalies similar to humans in various experimental mouse models.<sup>2,5,6</sup> Hyperthermia has induced experimental congenital scoliosis.<sup>7</sup> Teratogens, such as valproic acid,<sup>8</sup> boric acid,<sup>9</sup> smoking, and alcohol<sup>10,11</sup> have also been implicated.

Genetic factors are probably related to Notch genes which regulate cell fate and embryonic patterning. Mutations in Notch genes are seen in disorders with associated vertebral abnormalities, such as spondylocostal dysostosis and Alagille syndrome. The homeobox genes also regulate differentiation and segmentation and have been implicated in congenital scoliosis because of this role.<sup>2</sup> Clustering of congenital scoliosis in families further supports a genetic role as does the presence of congenital scoliosis in other genetic syndromes, such as facio-auricular-vertebral syndrome, Jarcho-Levin syndrome and Klippel-Feil syndrome. Wynn-Davies stated a 1:100 risk of a congenital scoliosis in a first degree relative of a patient with a single vertebral anomaly and a 1:10 risk for multiple vertebral anomalies.<sup>12</sup>

**CLASSIFICATION**

The most widely known classification is that of Winter et al.<sup>13</sup> This classification was developed based on plain

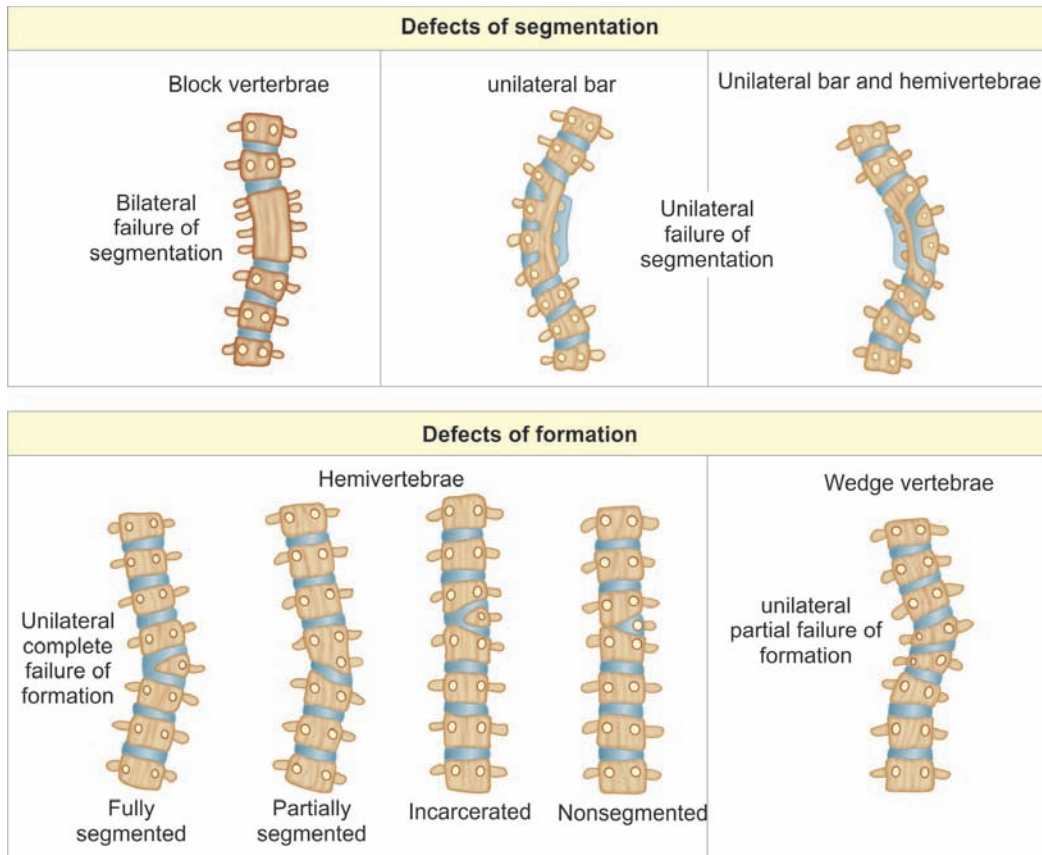


Fig. 1: Classification of failure of formation and failure of segmentation

radiographs and is by definition a two-dimensional (2D) classification. It categorizes abnormalities according to the perceived mode of developmental failure (Fig. 1).

Failure of formation refers to a deficiency of a vertebra to varying degrees. A minor deficiency could result in a vertebra with differential height but two normal pedicles. A more severe deficiency could result in a triangular shaped vertebra with a single pedicle known as a hemivertebra that results in a scoliosis due to asymmetrical growth. A hemivertebra that is incarcerated means it is contained within the lateral margins of the vertebra above and below. A nonincarcerated hemivertebra is free on its lateral margins. A fully segmented hemivertebra has a normal disk and growth plate above and below. A semisegmented hemivertebra has only one growth plate and an unsegmented hemivertebra is fused to the vertebra above and below. A fully segmented nonincarcerated hemivertebra has the greatest growth potential. Butterfly vertebrae are also a form of failure of formation. They have a central defect and as such little risk of scoliosis.

Failure of segmentation describes a bony bar that acts like a growth tether. Bilateral failure of segmentation results in a block vertebra, and so a symmetrical tether with no risk for scoliosis. A unilateral bar causes asymmetrical growth and possible scoliosis.

Winter recognized a third category as mixed failure of segmentation and formation. This can result in complex

curvatures which are not strictly classifiable into the other two categories.

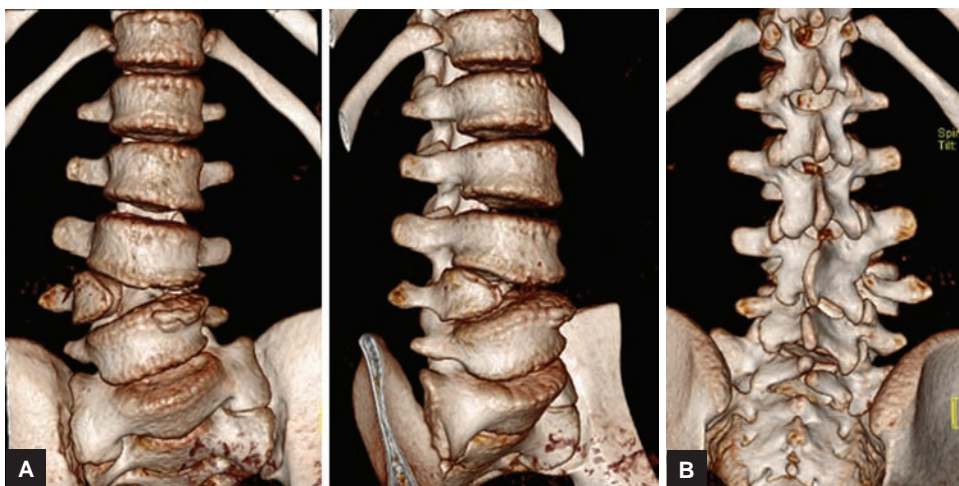
The position of the abnormal bone will dictate the type of deformity. A purely dorsal hemivertebra would cause a kyphosis. A laterally placed hemivertebra would cause a scoliosis. A dorsolateral hemivertebra would cause a kyphoscoliosis.

One of the criticisms of Winter’s classification is the use of a 2D imaging technique to describe and classify a three-dimensional (3D) abnormality. The advent of 3D computerized tomography (CT) has led to the development of other classification systems and a focus on the posterior element anomalies as well as the vertebral bodies (Figs 2A and B).

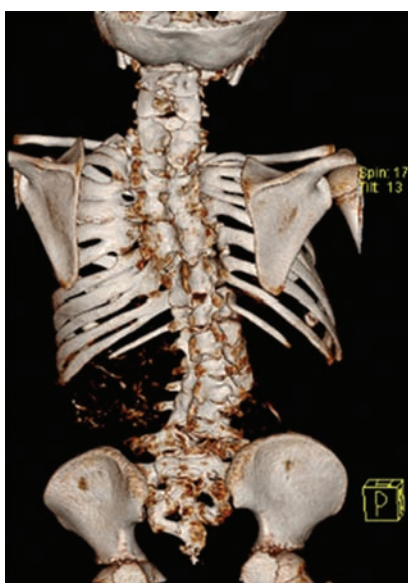Rib fusion is a common finding in congenital scoliosis. In some cases, a rib fusion can behave like a tether and reduce growth on the side of the rib fusion (Fig. 3).

### ASSOCIATED ANOMALIES

Congenital scoliosis has an association with other skeletal and nonskeletal congenital anomalies. The presence of another nonvertebral anomaly is present in 30 to 61% of patients with congenital scoliosis with an average of 1.3 to 1.6 nonvertebral abnormalities identified per patient.<sup>14-16</sup> Patients with mixed and segmentation defects tend to have a higher incidence of defects in other organs.<sup>16</sup>



**Figs 2A and B:** Three-dimensional CT of congenital scoliosis (fully segmented hemivertebra): (A) AP and oblique view; and (B) posterior view



**Fig. 3:** Complex congenital scoliosis with rib fusion

Congenital cardiac abnormalities are identifiable in 7 to 26%.<sup>14-16</sup> In one series, 50% of the cardiac anomalies needed medical or surgical treatment.<sup>16</sup> Genitourinary anomalies are found in 18 to 21%.<sup>15,16</sup> In most cases, the genitourinary abnormalities are benign, but up to 33% may need treatment.<sup>16</sup> Around 16 to 35% of patients have an associated musculoskeletal abnormality.<sup>15,16</sup> Cervical and upper thoracic defects had a strong association with upper limb hypoplasia and Sprengel's deformity.<sup>15</sup> Cranial nerve palsy has been reported in 11% of patients with a strong association with concurrent facial anomalies.<sup>15</sup> Gastrointestinal, tracheoesophageal, and pulmonary abnormalities are less common.

Intraspinal abnormalities are present in 24.5 to 47% of patients with variations according to ethnicity.<sup>16-18</sup> Most large series report tethered cord, syrinx, and diastematomyelia as the commonest intraspinal abnormalities.<sup>16-19</sup>

Other intraspinal abnormalities include Arnold-Chiari malformation, intradural cysts and intradural lipomas.<sup>16-19</sup> External stigmata of intraspinal anomalies are not invariably present.

Rib abnormalities are found in 19.2 to 57.4%.<sup>19,20</sup> The majority have structural rib changes as compared to a variation in number (absence of ribs).<sup>21</sup> Fused ribs are the commonest structural anomaly (60.4%) followed by bifid ribs combined with fused ribs (24.5%) and pure bifid ribs (9.4%).<sup>20</sup> Rib abnormalities are more often present with thoracic and thoracolumbar congenital scoliosis. Thoracic insufficiency syndrome can occur in the presence of significant rib abnormalities.<sup>22</sup>

Congenital scoliosis is associated with various syndromes including VACTERL syndrome (Vertebral Anorectal Cardiac Tracheo-Esophageal Renal Limb), facio-auricular-vertebral syndrome, Klippel-Feil syndrome, Alagille syndrome, Jarcho-Levin syndrome, and Joubert syndrome.

## NATURAL HISTORY

It was Winter who first reported the progressive nature of congenital scoliosis.<sup>14</sup> Previously congenital scoliosis was felt to be a benign disease. Both Winter and McMaster described the risk of progression to be related to the type of anomaly present.<sup>23,24</sup> Both reports identified that approximately 80% of untreated patients developed a curve over 40° at maturity. About 75% of cases needed treatment.

McMaster outlined in detail the risk of progression for different anomalies, the site of anomaly within the spine and age at presentation.<sup>23,24</sup> In general, clinical deformities present before the age of 10 years have a worse prognosis.

A block vertebra tends to be benign with a low-risk of progression of 1° per year. However, multiple block vertebrae can result in loss of truncal height.

Vertebrae with asymmetrical heights are variable in their progression, but are generally felt to be relatively benign with a progression of 1 to 2° per year.

The risk of progression of hemivertebrae is dependent on the growth potential around the abnormality. Unsegmented hemivertebrae have the least risk of progression and usually does not result in problematic curves at maturity.

When we consider segmented hemivertebra, the amount of growth plate, the site in the spine, and age, all influence progression. A fully segmented hemivertebrae has a higher risk of progression than a semisegmented one, but both can progress.

An upper thoracic hemivertebra before the age of 10 years has a progression rate of 1 to 2° per year. After 10 years (in the pubertal growth spurt), the rate of progression is 2 to 5° per year. Shoulder imbalance is the usual consequence of these curves which may be cosmetically significant.

A main thoracic hemivertebra has a higher rate of progression at 2° a year prepuberty and up to 3° postpuberty.

A thoracolumbar hemivertebra has the highest rate of progression of 2 to 5° per year prepuberty and 3.5° postpuberty.

Lumbar hemivertebrae have the slowest rate of progression at 1° per year at any age before skeletal maturity. Lumbosacral hemivertebra are similar in their rate of progression to lumbar vertebrae, but they can have a significant effect on the spine and truncal balance by causing an oblique take off. This can result in a pelvic obliquity and a compensatory curve that then become structural.

Failure of segmentation defects (unilateral bars) have a higher rate of progression but there is again variation according to site and age. Upper thoracic bars have a prepuberty rate of progression of 2° per year and 4° postpuberty. As well as causing significant shoulder imbalance, these can throw off a scoliosis below which also progresses and results in a significant deformity.

Main thoracic bars are reported to have a 5° per year progression rate before the age of 10 years and 6.5° per year after 10 years.

Thoracolumbar segmentation defects have a 6 to 9° per year rate of progression before and after puberty.

Lumbar spine bars have a reported rate of 5° per year irrespective of puberty. Again, they can cause an oblique take off and problems of driving a higher scoliosis and pelvic obliquity.

Mixed defects have variable rates of progression dependent on the anomalies present and the growth potential. For example, two contralateral hemivertebrae separated by a few normal segments (hemimetameric shift) may balance each other out and not cause any significant scoliosis overall.

Conversely, a unilateral bar with a contralateral hemivertebra has a significant risk of progression (reported to be up to 14° per year).

More complex and mixed defects (unclassifiable) may result in a variable progression rate dependent on the main drivers and counter balancing effects. In general, a thoracolumbar abnormality will tend to progress more than a thoracic or lumbar one.

All of these anomalies can result in a scoliosis at the site of the bony abnormality and a scoliosis in the adjacent section of the spine. These secondary curves can become structural and significant and progress in their own right leading to truncal imbalance, pelvic obliquity, and significant cosmetic deformities.

## ASSESSMENT

As this is a congenital condition, the assessment must take into account the pregnancy and birth history as well as the child's developmental history.

Clinical assessment needs to identify the age of onset of a visible deformity and any progression. A family history to identify relatives with the same condition is important as well as a systemic enquiry and comorbidity screen to look for associated anomalies and syndromes. The concerns must be considered to determine their priorities (e.g., cosmetic concerns, pain, or medical consequences). For cosmetic concerns, it is worth noting which external features are particularly problematic (the shoulder imbalance, rib hump, waist asymmetry, pelvic obliquity, truncal imbalance, or apparent leg length abnormality).

The maturity should be noted (age, secondary sexual characteristics, height compared to siblings, and parents) and their general health and exercise tolerance. Current functional level and future aspirations are worth documenting.

Essentially, a full pain, cosmetic, neurological, and functional history should be established for each patient along with age of onset, history of progression, and skeletal maturity as progression factors.

Examination should record the general appearance of the patient, sitting and standing weight. The standing truncal balance in both coronal and sagittal planes and pattern of gait in walking children is important. The shoulder symmetry in true stance as well as pelvic obliquity and any leg length discrepancy should be assessed for. The presence of a rib hump in standing and in Adam's position should be noted. Range of movement of the spine and flexibility of the curve can be determined in the standing position. External stigmata of intraspinal anomalies should be sought, such as skin defects, hairy patches, and previous scars. Deformities of the feet may also imply neurological anomalies (e.g., fixed pes cavus).

A full neurological examination should be completed (of upper and lower limbs) including abdominal reflexes. The curve flexibility can be assessed prone as can pain on palpation.

The chest should be auscultated for cardiac murmurs and normal breath sounds. The respiratory rate and effort (use of accessory muscles) and chest expansion may highlight features of thoracic insufficiency syndrome.<sup>22</sup> External genitalia and the anal orifice should be assessed for abnormalities. The rest of the musculoskeletal system should be briefly examined for abnormalities. Particular attention to the shoulder girdle and cervical spine will help identify Klippel-Feil syndrome.

Plain standing whole spine radiographs (PA and true lateral views) are valuable in identifying the spinal deformity and underlying congenital anomalies. Additional limited or coned views of congenital anomalies may help identify their exact nature. In very young patients, not all anomalies will be obvious due to lack of ossification.

Due to the 3D nature of abnormality, 3D CT is invaluable. In a growing child, the radiation dose may result in this being limited to a preoperative study rather than a diagnostic study. 3D CT of the thoracic cage is helpful when there are complex rib anomalies.

Magnetic resonance imaging of the whole spine (including the craniocervical and sacrococcygeal regions) is important to look for intraspinal anomalies, sacral defects, and craniocervical anomalies. Coronal and sagittal views will help to visualize the cord and the degree of segmentation of hemivertebrae.

A cardiac echocardiogram and renal ultrasound are also mandatory in the author's view to identify and intervene on associated genitourinary or cardiac abnormalities. Pulmonary function tests will help document the presence of a ventilatory defect.

In addition to the mandatory investigations outlined above, surface topography is a useful adjunct to document the external contours of the trunk. Clinical photography is similarly valuable.

CT angiography may be important when planning surgery, particularly for anterior procedures, as aberrant vessels are not uncommon.

Prenatal ultrasound does identify congenital spinal anomalies.<sup>25,26</sup> This can be a valuable way to identify both the skeletal abnormality and associated abnormalities. Parents can be informed of the diagnosis and the potential fate of the pregnancy. Live births can undergo early monitoring and management for their congenital scoliosis.

## TREATMENT OPTIONS

Treatment of congenital scoliosis is best undertaken in specialist centers. It is necessary to understand that this

is a condition associated with other system abnormalities that need identifying and treating. The spinal abnormalities need to be fully recognized in their 3D extent and the treating clinician should be able to formulate a risk of progression that will guide treatment options and timing of intervention.

Congenital scoliosis is unique in that it can be identified early and after determining the risk of progression, a small intervention could prevent a significant curve with minimal interference to the growth of the child.

As such early identification, risk stratification, and appropriate targeted intervention are the key factors in managing a congenital scoliosis.

The goals of treatment are to be left with a balanced, pain free spine with maximal growth and flexibility at maturity.

At times, a late presentation will be a challenge requiring complex reconstructive procedures including osteotomies.

Any centers managing these children surgically need to have the facilities to screen for other organ abnormalities and to fully evaluate the spine. Appropriate anesthetic and critical care support is required as well as spinal cord monitoring with motor and sensory evoked potentials.

Implants may need to be modified for younger children with smaller bones. It is not unusual to use cervical implants in the lumbar spine when intervening early. As implants have a higher risk of loosening due to their size and due to bone quality, postoperative casting or bracing is needed for the first 6 to 12 weeks.

## OBSERVATION

Observation for congenital scoliosis is a reasonable option. However, early management should be considered in those with a known poor prognosis, such as a unilateral bar with a contralateral hemivertebra.<sup>23</sup>

## BRACING

Bracing has a limited role in congenital scoliosis. Certainly, short sharp curves tend to be resistant to bracing. There is a potential role for bracing in longer and flexible curves as well as when trying to manage secondary curves.<sup>27</sup> Curves at high risk for progression or those that are progressing should not be left to prolonged bracing techniques.

## FUSION IN SITU

Converting an abnormal growing segment to a block vertebra is a relatively easy option. It is usually indicated when there is minimal deformity over a short segment and there is limited potential for growth in the segment concerned. A unilateral bar is a classic indication for

*in situ* fusion. The approach can be posterior alone or anterior and posterior depending on the exact nature of the bony abnormality, amount of growth potential at the site, and the risk of progression. For example, a unilateral bar with a lateral hemivertebra would be best treated with anterior and posterior instrumented fusion to allow complete control in a situation with a significant risk of progression. McMaster advocated the use of *in situ* fusion early in unsegmented bars with or without contralateral hemivertebrae as a prophylactic procedure.<sup>28,29</sup> There has been similar support for managing junctional anomalies early with *in situ* fusion. *In situ* fusion can be instrumented or uninstrumented.

### CONVEX HEMIEPIPHYSIODESIS

This is a procedure that aims to create a growth arrest on the side of the curve with excessive growth (convexity) to allow the opposite side (concavity) to catch up. By its nature, it depends on normal or near normal growth on the opposite side and it needs to be carried out early to allow the “catch-up” to occur. Winter recommended that the procedure is performed in patients before the age of 5 years with a pure scoliosis less than 70° involving fewer than five segments and not in the cervical spine.<sup>30</sup> A classic indication is a true lateral fully segmented hemivertebra. It is performed by exposing and removing the convex half of the disk and endplate anteriorly and decorticating the convex half posteriorly and grafting to achieve fusion. The opposite side of the spine should not be exposed. Posterior only approaches have also been described successfully.<sup>31</sup> This procedure is contraindicated when there is little chance of growth on the opposite side as with an unsegmented bar.

### HEMIVERTEBRA EXCISION AND FUSION

When there is a more significant deformity with a risk of the spine failing to catch up, a hemivertebra excision and fusion allows an immediate correction and longer term control by essentially providing a wedge resection technique. The hemivertebra is removed or decancellated and compression instrumentation used to achieve and maintain a correction. Anterior and posterior approaches were initially advocated for this technique to allow a full excision and avoid manipulation of the contents of the thecal sac.<sup>23,28,31,32</sup> Other authors have described success with posterior only procedures (including decancellation) with pedicle screw instrumentation.<sup>33,34</sup> They cite shorter operating times and less blood loss with equivalent success. Posterior only surgery probably achieves the best results in children under 6 years before long, rigid curves develop.<sup>34</sup>

### GROWING ROD TECHNIQUES

In more complex congenital scoliosis, such as those involving abnormalities at multiple levels or those associated with a longer curve, techniques controlling more of the spine may be required. In a growing child, using growing rod techniques with or without apical fusion of the congenital anomaly has become an established method of controlling curvatures. Many series reporting growing rod instrumentation include patients with congenital scoliosis and have been shown to have achieved curve control, space available for the lung, and thoracic height (the primary goals of growing rod instrumentation). There are now reports specifically looking at congenital scoliosis which again have demonstrated good outcomes using growing rods.<sup>35,36</sup> Wang et al reported on 30 patients with 2-year results with significant improvement of the Cobb's angle, an average improvement of T1-S1 height of 1.49 cm per year and an improvement of space available for lung ratio from 0.84 to 0.96 at latest follow-up.<sup>36</sup> Wang et al and others have also used dual growing rods in complex long congenital scoliosis after osteotomy and fusion of the rigid apical section of the deformity with success.

There are fewer reports using magnetically driven growing rods but most case series include congenital scoliosis patients within their cohorts with promising preliminary results.<sup>37</sup> Long-term evaluation of this technique is awaited.

The vertical expandable prosthetic titanium rib (VEPTR) was initially developed for thoracic insufficiency syndrome and so has been used in congenital scoliosis with rib fusion. The procedure involves excision of the rib fusion mass and application of the VEPTR implant as a rib to rib device or a rib to spine device to control the scoliosis and achieve an expansion thoracoplasty. This technique has had success in controlling the Cobb's angle and thoracic height in pure congenital scoliosis (nonsyndromic).<sup>38</sup> The VEPTR device has been used in the absence of rib fusion to control congenital scoliosis in a growing spine. The device does seem to control the Cobb's angle and thoracic spine height even if expansion thoracoplasty is not needed.<sup>39</sup> However, complication rates from VEPTR have been reported as being high in terms of implant dislodgement, prominent hardware, infection, and erosion. This seems to be more of an issue in hyperkyphotic scoliosis.<sup>39,40</sup>

### COMPLEX RECONSTRUCTION TECHNIQUES

Neglected or delayed presentation congenital scoliosis can often be a challenging problem emphasizing the need for early identification and management of these patients. Usually, the primary driving curve is associated with a

rigid structural secondary curve with truncal imbalance and/or pelvic obliquity. Once grown, these patients are best treated with osteotomies and long instrumented fusion to achieve balance and truncal length. They can be difficult cases to get right as postoperative coronal or sagittal imbalance is not unusual if all fixed abnormal curvatures are not considered.

## DISCUSSION

Congenital scoliosis can be both rewarding and challenging. By improving prenatal diagnosis and other early detection methods, close observation and early judicious intervention may allow curve control while maintaining a growing and generally flexible spine. Dual growing rod techniques are also helpful in controlling more diffuse and complex congenital scoliosis to achieve deformity control and maintain thoracic height and the space available for the lung. More complex assessments and classification systems will provide us with greater understanding of the natural history of subtypes and fine-tune our management strategies even further.<sup>41,42</sup>

## ACKNOWLEDGMENT

Author would like to acknowledge Shupa Rahman for the support given in writing this article.

## REFERENCES

- Shands AR Jr, Eisberg HB. The incidence of scoliosis in the state of Delaware; a study of 50,000 minifilms of the chest made during a survey for tuberculosis. *J Bone Joint Surg Am* 1955 Dec;37-A(6):1243-1249.
- Hensinger RN. Congenital scoliosis: etiology and associations. *Spine (Phila Pa 1976)* 2009 Aug;34(17):1745-1750.
- Tanaka T, Uthoff HK. The pathogenesis of congenital vertebral malformations. A study based on observations made in 11 human embryos and fetuses. *Acta Orthop Scand* 1981 Aug;52(4):413-425.
- Tanaka T, Uthoff HK. Significance of resegmentation in the pathogenesis of vertebral body malformation. *Acta Orthop Scand* 1981 Jun;52(3):331-338.
- Rivard CH. Effects of hypoxia on the embryogenesis of congenital vertebral malformations in the mouse. *Clin Orthop Relat Res* 1986 Jul;(208):126-130.
- Ingalls TH, Curley FJ. Principles governing the genesis of congenital malformations induced in mice by hypoxia. *N Engl J Med* 1957 Dec;257(23):1121-1127.
- Edwards MJ. Hyperthermia as a teratogen: a review of experimental studies and their clinical significance. *Teratog Carcinog Mutagen* 1986;6(6):563-582.
- Ardinger HH, Atkin JF, Blackston RD, Elsas LJ, Clarren SK, Livingstone S, Flannery DB, Pellock JM, Harrod MJ, Lammer EJ, et al. Verification of the fetal valproate syndrome phenotype. *Am J Med Genet* 1988 Jan;29(1):171-185.
- Wéry N, Narotsky MG, Pacico N, Kavlock RJ, Picard JJ, Gofflot F. Defects in cervical vertebrae in boric acid-exposed rat embryos are associated with anterior shifts of hox gene expression domains. *Birth Defects Res A Clin Mol Teratol* 2003 Jan;67(1):59-67.
- Erol B, Lou J, Dormans JP. Etiology of congenital scoliosis. *The University of Pennsylvania Orthop J* 2002;15:37-42.
- Schilgen M, Loeser H. Klippel-Feil anomaly combined with fetal alcohol syndrome. *Eur Spine J* 1994;3(5):289-290.
- Wynne-Davies R. Congenital vertebral anomalies: aetiology and relationship to spina bifida cystica. *J Med Genet* 1975 Sep;12(3):280-288.
- Winter RB. Congenital deformities of the spine. New York, NY: Thieme-Stratton;1983. p. 343
- Winter RB, Moe JH, Eilers VE. Congenital scoliosis: a study of 234 patients treated and untreated. *J Bone Joint Surg Am* 1968 Jan;50(1):1-15.
- Beals RK, Robbins JR, Rolfe B. Anomalies associated with vertebral malformations. *Spine* 1993 Aug;18(10):1329-1332.
- Basu PS, Elsebaie H, Noordeen MH. Congenital spinal deformity: a comprehensive assessment at presentation. *Spine* 2002 Oct;27(20):2255-2259.
- Liu YT, Guo LL, Tian Z, Zhu WL, Yu B, Zhang SY, Qiu GX. A retrospective study of congenital scoliosis and associated cardiac and intraspinal abnormalities in a Chinese population. *Eur Spine J* 2011 Dec;20(12):2111-2114.
- Gupta N, Rajasekaran S, Balamurali G, Shetty A. Vertebral and intraspinal anomalies in Indian population with congenital scoliosis: a study of 119 consecutive patients. *Asian Spine J* 2016 Apr;10(2):276-281.
- Ghandhari H, Tari HV, Ameri E, Safari MB, Fouladi DF. Vertebral, rib, and intraspinal anomalies in congenital scoliosis: a study on 202 Caucasians. *Eur Spine J* 2015 Jul;24(7):1510-1521.
- Tsirikos AI, McMaster MJ. Congenital anomalies of the ribs and chest wall associated with congenital deformities of the spine. *J Bone Joint Surg Am* 2005 Nov;87(11):2523-2536.
- Xue X, Shen J, Zhang J, Zhao H, Li S, Zhao Y, Liang J, Qiu G, Weng X. Rib deformities in congenital scoliosis. *Spine* 2013 Dec;38(26):E1656-E1661.
- Campbell RM Jr, Smith MD, Mayes TC, Mangos JA, Willey-Courand DB, Kose N, Pinero RF, Alder ME, Duong HL, Surber JL. The characteristics of thoracic insufficiency syndrome associated with fused ribs and congenital scoliosis. *J Bone Joint Surg Am* 2003 Mar;85-A(3):399-408.
- McMaster MJ, Ohtsuka K. The natural history of congenital scoliosis: a study of two hundred and fifty-one patients. *J Bone Joint Surg Am* 1982 Oct;64(8):1128-1147.
- Marks DS, Qaimkhani SA. The natural history of congenital scoliosis and kyphosis. *Spine* 2009 Aug;34(17):1751-1755.
- Goldstein I, Makhoul IR, Weissman A, Drugan A. Hemivertebra: prenatal diagnosis, incidence and characteristics. *Fetal Diagn Ther* 2005 Mar-Apr;20(2):121-126.
- Wax JR, Watson WJ, Miller RC, Ingardia CJ, Pinette MG, Cartin A, Grimes CK, Blackstone J. Prenatal sonographic diagnosis of hemivertebrae: associations and outcomes. *J Ultrasound Med* 2008 Jul;27(7):1023-1027.
- Winter RB, Moe JH, MacEwen GD, Peon-Vidales H. The Milwaukee brace in the nonoperative treatment of congenital scoliosis. *Spine* 1976 Jun;1(2):85-96.
- McMaster MJ, David CV. Hemivertebra as a cause of scoliosis. A study of 104 patients. *J Bone Joint Surg Br* 1986 Aug;68(4):588-595.
- McMaster MJ. Congenital scoliosis caused by a unilateral failure of vertebral segmentation with contralateral hemivertebrae. *Spine* 1998 May;23(9):998-1005.

30. Winter RB, Lonstein JE, Davis F, Sta-Ana de la Rosa H. Convex growth arrest for progressive congenital scoliosis due to hemivertebrae. *J Pediatr Orthop* 1988 Nov-Dec;633-638.
31. Hedequist DJ. Surgical treatment of congenital scoliosis. *Orthop Clin North Am* 2007 Oct;38(4):497-509.
32. Bollini G, Docquier PL, Viehweger E, Launay F, Jouve JL. Lumbosacral hemivertebrae resection by combined approach: medium- and long-term follow-up. *Spine* 2006 May;31(11):1232-1239.
33. Ruf M, Harms J. Posterior hemivertebra resection with transpedicular instrumentation: early correction in children aged 1 to 6 years. *Spine* 2003 Sep 15;28(18):2132-2138.
34. Chang DG, Kim JH, Ha KY, Lee JS, Jang JS, Suk SI. Posterior hemivertebra resection and short segment fusion with pedicle screw fixation for congenital scoliosis in children younger than 10 years: greater than 7-year follow-up. *Spine* 2015 Apr 15;40(8):E484-E491.
35. Elsebai HB, Yazici M, Thompson GH, Emans JB, Skaggs DL, Crawford AH, Karlin LI, McCarthy RE, Poe-Kochert C, Kostial P, et al. Safety and efficacy of growing rod technique for pediatric congenital spinal deformities. *J Pediatr Orthop* 2011 Jan-Feb;31(1):1-5.
36. Wang S, Zhang J, Qiu G, Wang Y, Li S, Zhao Y, Shen J, Weng X. Dual growing rods technique for congenital scoliosis: more than 2 years outcomes: preliminary results of a single center. *Spine* 2012 Dec 15;37(26):E1639-E1644.
37. Akbarnia BA, Cheung K, Noordeen H, Elsebaie H, Yazici M, Dannawi Z, Kabirian N. Next generation of growth-sparing techniques: preliminary clinical results of a magnetically controlled growing rod in 14 patients with early-onset scoliosis. *Spine* 2013 Apr 15;38(8):665-670.
38. Flynn JM, Emans JB, Smith JT, Betz RR, Deeney VF, Patel NM, Campbell RM. VEPTR to treat nonsyndromic congenital scoliosis: a multicenter, mid-term follow-up study. *J Pediatr Orthop* 2013 Oct-Nov;33(7):679-684.
39. Murphy RF, Moisan A, Kelly DM, Warner WC Jr, Jones TL, Sawyer JR. Use of vertical expandable prosthetic titanium rib (VEPTR) in the treatment of congenital scoliosis without fused ribs. *J Pediatr Orthop* 2016 Jun;36(4):329-335.
40. Waldhausen JH, Redding G, White K, Song K. Complications in using the vertical expandable prosthetic titanium rib (VEPTR) in children. *J Pediatr Surg* 2016 Nov;51(11):1747-1750.
41. Ghiță R, Georgescu I, Muntean M, Hamei Ș, Japie EM, Dughilă C, Țiripa I. Burnei-Gavriliu classification of congenital scoliosis. *J Med Life* 2015 Apr;8(2):239-244.
42. Kawakami N, Tsuji T, Imagama S, Lenke LG, Puno R, Kuklo TR, Spinal Deformity Study Group. Classification of congenital scoliosis and kyphosis: a new approach to the three-dimensional classification for progressive vertebral anomalies requiring operative treatment. *Spine* 2009 Aug;34(17):1756-1765.