



Clinical Evaluation of the Effectiveness of Glass Fiber-reinforced Composite Space Maintainer vs Band-and-loop Space Maintainer following Loss of Primary Teeth: An *in vivo* Study

¹Shruti Kataria, ²Yusuf Chunawala, ³Abdul Morawala, ⁴Kapil Jain, ⁵Arti Ambiyee

ABSTRACT

Introduction and aim: Premature exfoliation or extraction of primary tooth may lead to loss of space due to drifting of the adjacent teeth. This may also lead to undesirable effects, such as impaction of the succedaneous tooth, overeruption of the opposing tooth, and a shift of the midline, with consequent functional impairment. It is prudent to consider space maintenance when primary teeth are lost prematurely. The current study aims to clinically evaluate the effectiveness of space maintainers comparing conventional band and loop space maintainer with glass fiber-reinforced space maintainer following loss of primary teeth in mixed dentition.

Materials and methods: A total of 30 children aged 4 to 8 years were randomly assigned into two groups – band-and-loop space maintainer (group I) and glass fiber-reinforced composite (GFRC) space maintainer (group II). Distortion/dislodgment of the loop or the fiber frame, fracture of loop or fiber frame, gingival health, and space loss were evaluated clinically and radiographically at 1, 3, 6, and 12 months interval. Gingival health was assessed by gingival index given by Loe and Silness.

Results: Based on the statistical analysis, overall success rate of group I was found to be 69.2% and of group II was 95.7% ($p = 0.026$), which was statistically significant.

Conclusion: The GFRC space maintainers showed an overall success rate compared with band-and-loop space maintainers.

Keywords: Band-and-loop space, Caries, Everstick glass fiber-reinforced composite, Extraction, Primary molars, Space maintainers.

How to cite this article: Kataria S, Chunawala Y, Morawala A, Jain K, Ambiyee A. Clinical Evaluation of the Effectiveness of Glass Fiber-reinforced Composite Space Maintainer vs Band-and-loop Space Maintainer following Loss of Primary Teeth: An *in vivo* Study. *Int J Clin Dent Res* 2017;1(1):5-9.

Source of support: Nil

Conflict of interest: None

^{1,4,5}Postgraduate Student, ²Head and Professor, ³Reader

¹⁻⁵Department of Pediatric and Preventive Dentistry, M. A. Rangoonwala College of Dental Sciences & Research Centre Pune, Maharashtra, India

Corresponding Author: Yusuf Chunawala, Head and Professor Department of Pediatric and Preventive Dentistry, M. A. Rangoonwala College of Dental Sciences & Research Centre Pune, Maharashtra, India

INTRODUCTION

The three primary correlates of human dental occlusion – dentitional development, craniofacial growth, and neuromuscular maturation, while constantly interrelated in function, nevertheless develop at different schedules. As a result, the development of occlusion is one of the most fascinating and complicated problems in all of development biology. Every oral health care provider must take necessary measures to evaluate and monitor the development toward optimal results. There are many morphogenetic and environmental influences affecting the occlusal development, and a disorder in any of these elements may influence the occlusion.¹

Premature exfoliation or extraction of primary tooth may lead to loss of space due to drifting of the adjacent teeth. This may also lead to undesirable effects, such as impaction of the succedaneous tooth, overeruption of the opposing tooth, and a shift of the midline, with consequent functional impairment.² It is prudent to consider space maintenance when primary teeth are lost prematurely. Factors to consider include specific tooth lost, time elapsed since tooth loss, preexisting occlusion, favorable space analysis, presence and root development of permanent successor, amount of alveolar bone covering permanent successor, patient's health status, patient's cooperative ability, active oral habits, and oral hygiene.³

The function of a space maintainer is to preserve arch length following the premature loss of a primary tooth (or teeth). The space maintainer allows the permanent tooth to erupt unhindered into proper alignment and occlusion. A space maintainer is recommended after the extraction of a primary molar. Just "watching" often results in the creation of a more difficult arch length problem.⁴

Adverse effects associated with conventional space maintainers include dislodged, broken, and lost appliances; plaque accumulation; caries; interference with successor eruption; undesirable tooth movement; inhibition of alveolar growth; soft tissue impingement; and pain.

The present study compares glass fiber-reinforced composite (GFRC) vs conventional band-and-loop space maintainers.

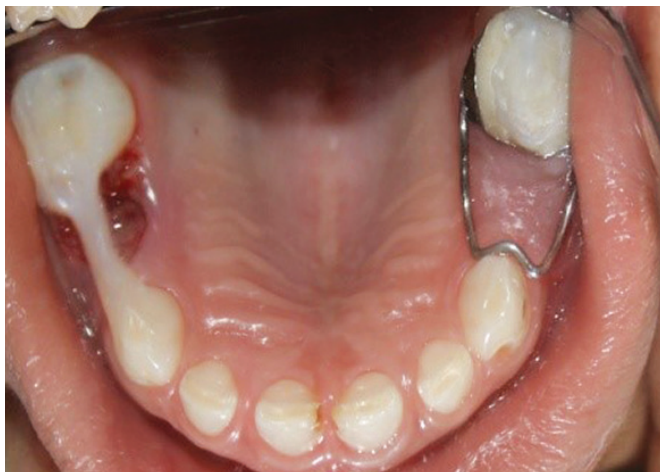

Fig. 1: Postoperative view showing band-and-loop space maintainer (right side) and GFRC space maintainer (left side)

MATERIALS AND METHODS

The study was carried out to compare and evaluate the distortion of loop/fiber frame, fracture of space maintainer, and gingival health and space loss after placement of conventional band-and-loop space maintainer and fiber space maintainer at 1, 3, 6, and 12 months. The study sample consisted of 30 pediatric patients indicated for bilateral first deciduous molar extraction, and the sample was divided into two groups, group I – Band-and-loop space maintainer, group II – GFRC space maintainer (Fig. 1).

Patient Inclusion Criteria

Clinical Criteria – Age Group: 4 to 8 Years

- Patient with premature loss of primary first molar in at least two quadrants;
- Presence of Angle’s class I molar relationship and/or presence of flush terminal/mesial step/primary molar occlusion;
- Criteria for abutment teeth of group II – the presence of proximal carious lesion on mesial surface of second primary molar and distal surface of primary canine not involving the pulp.

Radiographic Criteria

- Absence of any periapical and periarticular pathology with abutment tooth;
- Presence of succedaneous tooth bud;
- Presence of more than 1 mm of bone overlying the succedaneous tooth germ or less than one-third the root of permanent tooth formed.

Patient Exclusion Criteria

- Multisurface caries on abutment tooth
- Caries involving pulp on abutment tooth

- Permanent incisors completely erupted
- Medically and physically compromised patients

Procedure

Patients requiring bilateral extraction of primary first molars were selected for the study based on inclusion and exclusion criteria, and randomly assigned to any one group. Informed consent was obtained from the parent or the guardian. For every selected child, oral prophylaxis and other restorative treatments were carried out. Any carious lesion on abutment teeth selected for group I cases were restored with permanent restoration, whereas carious lesion on the mesial and distal surfaces of abutment teeth selected for group II cases were restored with temporary restoration (intermediate restorative material), so that they will serve as future sites for fiber placement. Upper and lower impressions were made, and study models were prepared. Measurement and recording of space present between primary canine and primary second molar preoperatively were done using preoperative cast and radiograph, which served as baseline data.

Space analysis was done using clinical assessment, preoperative cast, and radiographic assessment using Huckaba analysis. Following parameters were considered to compare the treatment modalities at 1, 3, 6, and 12 months postoperatively:

- Distortion/dislodgment; of the loop or the fiber frame
- Fracture; of loop or fiber frame
- Gingival health
- Space loss

Measurements

Distortion/dislodgment and the fracture of the loop or the fiber frame were assessed clinically. Gingival health was assessed using the gingival index.

Gingival Index

The gingival index assesses the quality, severity, and location of the gingival inflammation. The assessment was done with a mouth mirror and probe in presence of adequate natural light.

The scoring pattern was as follows:

Score	Criteria
0	No inflammation
1	Mild inflammation, slight color change, slight edema, no bleeding on probing
2	Moderate inflammation, redness, edema, glazing, bleeding on probing
3	Severe inflammation, marked redness, edema, ulceration, tendency to spontaneous bleeding

Scores 0 and 1 were considered as healthy gingiva, and scores 2 and 3 were considered as presence of inflamed gingiva.

SPACE LOSS

The baseline data for space available between mesial surface of primary canine and distal surface of second primary molar were obtained from the preoperative cast and radiograph, and were correlated with the space available on the radiograph between mesial surface of canine and distal surface of primary second molar at 12 months interval. Any discrepancy noted was calculated as space loss.

Groups		Treatment
I	Control site	Band-and-loop space maintainer
II	Test site	GFRC space maintainer

Procedure for Band-and-loop Space Maintainer Group I

Band pinching was done on second primary molar using band material (0.005 by 0.180 by 2 inches). Alginate impressions were made. The band was transferred from the tooth to the impression. Casts were poured after stabilizing the bands. Tooth to be extracted was scraped in the cast. A loop was fabricated for the space maintainer using 19-gauge wire. The band and loop were soldered together followed by polishing of the same. In the next appointment, extraction of the indicated tooth was carried out followed by cementation of space maintainer using type I glass ionomer cement.

Procedure for GFRC Resin Space Maintainer (GFRC-Everstick) Group II

Extraction of the indicated tooth was carried out under local anesthesia followed by removal of the temporary

restoration from the carious lesion. Bleeding control was achieved followed by placement of rubber dam to maintain strict isolation for the fabrication of space maintainer. This was followed by cleaning of the prepared cavities on the abutment teeth and etching of the prepared cavities on abutment teeth. Bonding agent was applied to the cavity surfaces on the abutment teeth. The fiber was cut to the required length followed by placement of the fiber segment across the edentulous space, with its ends within the prepared cavities. Bonding agent was applied to the fiber segment and cured. Restoration of the cavities on abutment teeth was done with composite with the ends of fiber segment within the restoration. The fiber segment along the edentulous span was covered with the composite. Occlusion was checked followed by polishing of the space maintainer. Postoperative instructions were given.

Data Evaluation

Data were collected by clinical and radiographic evaluations at 1, 3, 6, and 12 months (Figs 2 and 3). Subsequently, all the values of the data were subjected to suitable statistical analysis for comparative evaluation.

RESULTS

Based on statistical analysis, overall success rate of group I was found to be 69.2% and of group II was 95.7% ($p = 0.026$), which was statistically significant (Table 1 and Graph 1). The GFRC space maintainers showed an overall success rate compared with band-and-loop space maintainers. Based on statistical analysis of inter- and intragroup comparison at 1, 3, 6, and 12 months interval, distortion/dislodgment of the loop or the fiber frame, fracture of loop or fiber frame, and space loss were found statistically insignificant. Gingival health observed between groups I and II at 12 months follow-up was found statistically significant ($p = 0.026$).

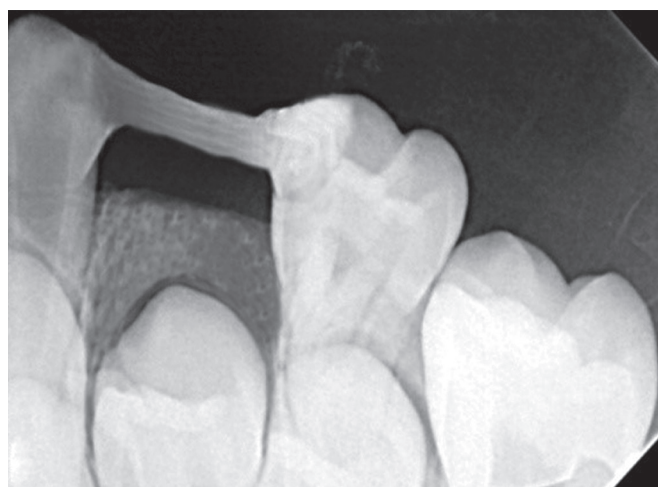

Fig. 2: Radiographic image of GFRC space maintainer at follow-up

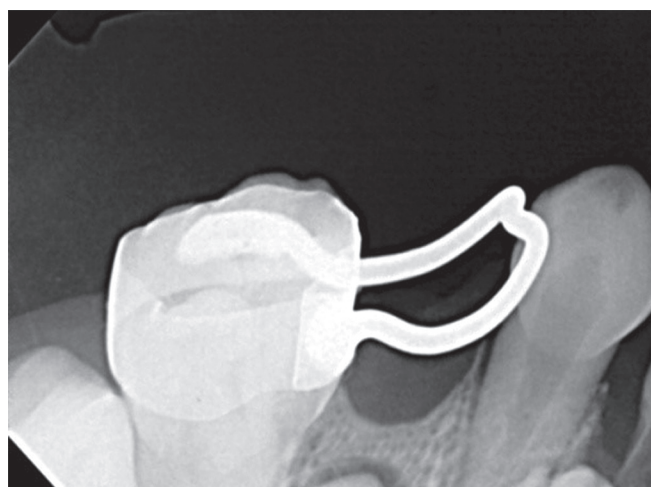


Fig. 3: Radiographic image of band-and-loop space maintainer at follow-up

Table 1: Overall success rate between two study groups

Overall status	Group I (n = 30)	Group II (n = 30)	p-values (between groups)
At 12 months			
No (success)	18 (69.2)	22 (95.7)	0.026 (significant)
Yes (failure)	8 (30.8)	1 (4.3)	

Values are n (%). p-value is obtained using chi-square test, if cell frequencies are greater than 5, else Fisher's exact probability test is applied. p-value < 0.05 is considered to be statistically significant

DISCUSSION

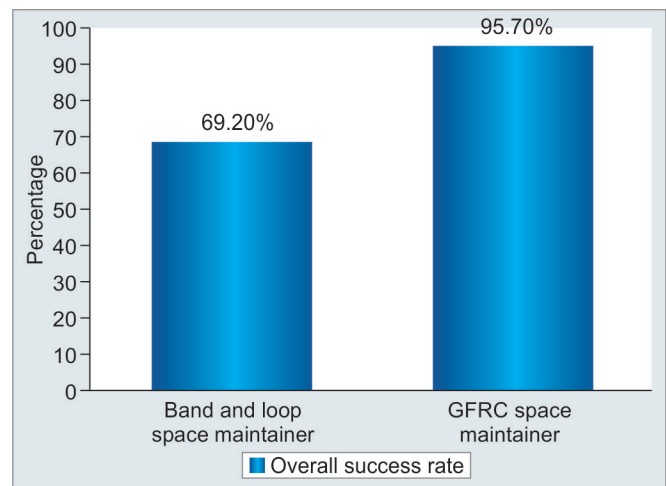
As defined by Moyers,¹ space supervision is "when the judgement of dentist determines that the individual patient's occlusion will have a better chance of obtaining optimum development, through supervised intervention of the transitional dentition than without clinician directed intervention." Space maintaining utilizes an appliance to preserve space without necessary awareness of the dynamics of the situation.⁵

Tooth drifting is dependent mainly on the following important factors: (1) The dental age at the time of extraction; (2) preexisting occlusion; (3) eruption path and time; and (4) intercuspation.⁶ Space loss in the maxilla is predominantly due to mesial drifting of the second primary molar, and in the mandible predominantly due to distal drifting of primary canine. Mesial drifting of the second mandibular primary molars and distal drifting of the maxillary primary canines take place, but to a much lesser degree.⁶

The band-loop appliance has been used after the premature loss of the primary molar. The major components of this appliance are a band on the abutment tooth and a loop that traverses the edentulous space and is wide enough to allow eruption of the succedaneous tooth. Although this appliance has been effective, it has its own limitations. Thus, long-term wear requires periodic recementations.^{7,8} Bands on abutment teeth may interfere with oral hygiene, leading to an increased caries activity.⁹ Rising laboratory costs and other inflationary factors also have made the appliance more expensive.

Glass fibers were used to reinforce polymethyl methacrylates. This group is a very heterogeneous one depending on the nature of the fiber, the geometrical arrangement of the fibers, and the overlying resin material. The main materials used are either glass or polyethylene fibers. Polyethylene Fiber (Ribbond) are esthetic, but their handling properties and flexural strength is inferior as compared with GFRC.¹⁰ EverStick GFRC post has been previously used to restore severely mutilated primary anterior teeth.¹¹ It has shown success in three-unit bridges and in stress bearing areas as well.¹²

Evaluation at the end of the study period (12th month follow-up) showed failure of GFRC space maintainer in



Graph 1: Comparison of overall success rate between band-and-loop space maintainer and GFRC space maintainer

7 cases (23.3%) and band-loop space maintainer in 4 cases (13.3%, $p = 0.506$). The supraerupted opposing tooth impinged on the fiber frame, which resulted in increased concentration of mechanic stresses that lead to debonding at the fiber interface. Further wearing away of the thin layer of composite on the fiber frame during mastication resulted in gradual failure. Subramaniam¹³ et al stated that overzealous finishing of the space maintainer results in excessive removal of the resin overlying the fiber, which leads to debonding.

However, in the present study, breakage was primarily due to chewing on hard foods, which could be further accentuated by any of the above-mentioned reasons. Fabrication of the GFRC space maintainer is not time consuming unlike conventional space maintainers. The fiber space maintainer reduces time consumed in general anesthesia procedures. Due to its high flexural strength, fiber space maintainers can be used in fabrication of functional space maintainer, where it prevents the supraeruption of the opposing tooth.¹⁴ The fiber space maintainer is esthetic, instant, economic, impeccable, and easy to use.

CONCLUSION

The GFRC space maintainers showed an overall success rate (95.7%) compared with band-and-loop space maintainers (69.2%), and this difference was statistically significant. Space management forms a critical component of successful pediatric dental treatment. Most of the conventional methods involving bands and wire primarily consume a lot of time, energy, and effort. Fabrication of a band-loop space maintainer requires three steps. On the contrary, fiber space maintainers can be placed instantly in a single sitting only.

The development of the fiber-reinforced composite technology has brought a new dimension into the realm

of metal-free adhesive esthetic dentistry. EverStick glass fiber is a highly versatile material with an array of desirable properties, which allow us to practice esthetic, instant, and multi-quadrant dentistry in a single visit, and keep our pediatric patients and their parents happy.

REFERENCES

1. Moyers, RE. Handbook of orthodontics. 4th ed. Chicago: CV Mosby; 1988.
2. Kargul B, Çağlar E, Kabalay U. Glass fiber-reinforced composite resin space maintainer: case reports. *J Dent Child* 2003 Sep-Dec;70(3):258-261.
3. Dean, JA.; Avery, DR.; Mc Donald, RE.; editors. *Mc Donald and Avery's dentistry for the child and adolescent*. 9th ed. Maryland Heights (MO): CV Mosby; 2010.
4. Mathewson, RJ.; Primosch, RE. *Fundamentals of pediatric dentistry*. 3rd ed. India: Quintessence Publishing Co; 2011.
5. Eastwood AW. The lingual arch in space control. *Dent Clin North Am* 1968 Jul;383-397.
6. Kisling E, Høffding J. Premature loss of primary teeth: part III, drifting patterns for different types of teeth after loss of adjoining teeth. *ASDC J Dent Child* 1979 Jan-Feb;46(1):34-38.
7. Geiger, A.; Hirschfeld, L. *Minor tooth movement in general practice*. 3rd ed. St. Louis: CV Mosby Co.; 1974. p. 544-548.
8. MacKenzie BM. Single appointment approach to the space maintenance problem. *J Can Dent Assoc (Tor)* 1966 Nov;32(11):661-667.
9. Sakamaki ST, Bahn AN. Effect of orthodontic banding on localized oral lactobacilli. *J Dent Res* 1968 Mar-Apr;47(2): 275-279.
10. Lassila LV, Tanner J, Le Bell AM, Narva K, Vallittu PK. Flexural properties of fiber reinforced root canal posts. *Dent Mater* 2004 Jan;20(1):29-36.
11. Usha M, Deepak V, Venkat S, Gargi M. Treatment of severely mutilated incisors: a challenge to the pedodontist. *J Indian Soc Pedod Prev Dent* 2007 May;25(5 Suppl):S34-S36.
12. Vallittu PK. Some aspects of the tensile strength of unidirectional glass fiber-polymethyl methacrylate composite used in dentures. *J Oral Rehabil* 1998 Feb;25(2):100-105.
13. Subramaniam P, Babu GKL, Sunny R. Glass fiber-reinforced composite resin as a space maintainer: a clinical study. *J Indian Soc Pedod Prev Dent* 2008 Dec;26(Suppl 3):S98-S103.
14. Vallittu PK, Sevelius C. Resin-bonded, glass fiber-reinforced composite fixed partial dentures: a clinical study. *J Prosthet Dent* 2000 Oct;84(4):413-418.