

Comparative Study of Efficacy between Platelet-rich Plasma vs Corticosteroid Injection in the Treatment of Lateral Epicondylitis

¹Madhuram Chowdry, ²KM Gopinath, ³BNR Kumar, ⁴TR Kanmani

ABSTRACT

Introduction: Tennis elbow is a common condition with unpromising several modalities of treatment. Many of these are not aimed at treating the disease process. Platelet-rich plasma (PRP) contains biological healing factors and shows promising results in tendinopathies.

In this study, our aim was to evaluate the efficacy of autologous PRP vs steroid injection in the treatment of chronic recalcitrant lateral epicondylitis.

Materials and methods: A prospective randomized control trial was conducted in our tertiary care hospital. Sixty patients with chronic lateral humeral epicondylitis, not responding to oral medications, tennis elbow belt, and physiotherapy, aged between 18 and 60 years were included in the study. Patients were randomized into PRP or steroid injection group based on a computer-generated block randomization chart. All patients had a baseline assessment including visual analog pain scores, Disability assessment of Shoulder and Hand score (DASH), and Nirschl (Injury, Prevention, Cure and Care – Nirschl Pain Phase Scale of Athletic Overuse Injuries) scores, and the same was repeated at 2 weeks, 6 weeks, 3 months, and 6 months postintervention.

Results: Steroid treatment shows better outcome in short-term ($p < 0.001$) and PRP shows better outcome in long-term ($p < 0.001$) follow-up. All three scores – visual analog score (VAS), DASH, Nirschl – showed significant linear improvement with PRP treatment, whereas with steroid injection initially there was significant improvement up to 3 months and later recurrence of symptoms. No complications were noted with PRP injection.

Conclusion: Use of autologous PRP injections for the management of lateral epicondylitis has better long-term outcomes compared with steroid injection in terms of VAS, DASH, and Nirschl scores. Also in our trial we had no recurrence of symptoms in the PRP group, whereas pain recurred in six patients in steroid group and was treated successfully with PRP.

Keywords: Disability, Lateral epicondylitis, Pain, Platelet-rich plasma, Steroid injection.

How to cite this article: Chowdry M, Gopinath KM, Kumar BNR, Kanmani TR. Comparative Study of Efficacy between Platelet-rich Plasma vs Corticosteroid Injection in the Treatment of Lateral Epicondylitis. *J Med Sci* 2017;3(1):1-5.

Source of support: Nil

Conflict of interest: None

INTRODUCTION

Lateral epicondylitis is the most commonly diagnosed condition of the elbow and affects approximately 1 to 3% of the population. The condition mostly occurs in patients whose activities require strong gripping or repetitive wrist movements. Individuals between the ages of 35 and 50 years are at high risk. The dominant arm is most frequently affected. Lateral epicondylar tendinosis, also known as tennis elbow, is a condition characterized by pain in the region of the origin of common extensor tendons of the forearm from the lateral epicondyle of humerus; most typically the extensor carpi radialis brevis tendon is involved.¹ Repetitive overuse of a tendon leads to internal microtear in the tendon when tolerable stretch of tendon fiber is exceeded. Histological specimens from chronic cases confirm that tendinosis is a failure of the normal tendon repair mechanism associated with angio-fibroblastic degeneration. Diagnosis is mainly based on clinical signs and symptoms. However, ultrasound or magnetic resonance imaging can be used to confirm the diagnosis. Treatment includes rest, nonsteroidal anti-inflammatory diseases, physical therapy, tennis elbow belt, corticosteroid (CS) injection, botulinum toxin injection. Recently, extracorporeal shock waves, pulsed ultrasound and platelet-rich plasma (PRP) are gaining more importance in the treatment.

The use of platelets as vehicles for the delivery of a balanced pool of healing factors has become a new therapeutic treatment since the late 1990s. Platelet described as the major sources of healing factors within blood clots, the idea of concentrating them around injured site could accelerate and optimize the healing mechanisms set the rationale for the development of PRP. Platelet-rich plasma is defined as the plasma fraction of autologous blood having a platelet concentration above baseline. Studies show clinical efficacy can be expected with minimum

¹Junior Resident, ^{2,3}Professor, ⁴Assistant Professor

¹⁻³Department of Orthopedics, RajaRajeswari Medical College & Hospital, Bengaluru, Karnataka, India

⁴Department of Psychiatric Social Work, National Institute of Mental Health and Neurosciences, Bengaluru, Karnataka, India

Corresponding Author: Madhuram Chowdry, Junior Resident Department of Orthopedics, RajaRajeswari Medical College and Hospital, Bengaluru, Karnataka, India, Phone: +91-9620307042 e-mail: madhuram.chowdry14@gmail.com

increase of platelet concentration by four times the baseline concentration.³ The healing properties of the PRP have been attributed to the presence of various growth factors like platelet-derived growth factor (PDGF), vascular endothelial growth factor (VEGF), transforming growth factor (TGF), fibroblast growth factor (FGF), epidermal growth factor, hepatocyte growth factor (HGF), and insulin-like growth factor-1.² Several investigators have found increased collagen gene expression and increased production of VEGF and HGF in human tenocytes treated with PRP.³ With this brief background, the present study was planned.

The aim of this study is to compare the efficacy of CS injection and autologous PRP for the treatment of lateral epicondyle tendinopathy.

MATERIALS AND METHODS

Following approval from the Institutional Ethical Committee, we conducted a prospective randomized control trial in our tertiary care hospital between June 2014 and July 2016. Sixty patients with signs and symptoms of chronic lateral epicondylitis not responding to conservative management like oral medication, tennis elbow belt, physiotherapy, aged between 18 and 60 years were randomized into PRP and steroid injection group based on a computer-generated block randomization chart. Patients with bony lesions at elbow (assessed by X-ray of elbow), systemic diseases (diabetes mellitus, hypertension, rheumatoid arthritis), carpal tunnel syndrome, or cervical radiculopathy were excluded from the study.

Written informed consent was taken from all the patients participating in the study. For preparation of the PRP, 18 mL of blood was drawn and was introduced into two acid citrate dextrose vacutainer tubes (BD Franklin Lakes, NJ, USA) of 8.5 mL each (with 0.5 mL of Acid

citrate dextrose solution A) and then centrifuged at 1500 rpm for 6 minutes. Plasma and Buffy coat was separated under aseptic precaution into two sterile glass tubes and centrifuged (Fig. 1) again for second spin at 4500 rpm for 15 minutes (double spin method). The supernatant platelet-poor plasma was discarded and about 1 mL of PRP obtained from each tube. The platelet counts for PRP and unprocessed blood were assessed. The PRP showed mean concentration of 4x platelet compared with whole blood if four times the concentration obtained; then the sample was discarded and prepared again freshly.

The patients in the PRP group were given 2 mL of PRP prepared from autologous blood at the most tender point (Fig 2) over the lateral epicondyle. The patients in the steroid group received 2 mL of methylprednisolone (40 mg/mL, injection tricot).

Patients were rested for 15 minutes after injection and advised not to massage. Patients were prescribed a combination of tramadol and paracetamol (37.5 mg + 325 mg) tablets for pain for 3 to 5 days following injection and discouraged later on.

Patients were assessed using a 10-point visual analog score (VAS) for pain, Nirschl score, and Disabilities of Arm, Shoulder and Hand scale (DASH) score before and after treatment at 2, 6 weeks and 3, 6 months (Figs 1 and 2).

RESULTS

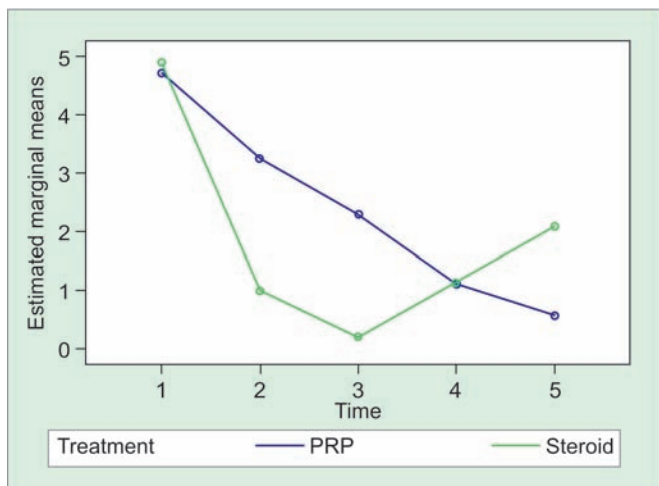
There was no statistically significant difference in the age distribution (Table 1) between the two groups. The VAS scores showed a normal distribution, hence, repeated measures analysis of variance was performed to compare the five means and two groups of steroid and PRP. Multivariate analysis of Pillai's Trace statistic showed a significant difference between the scores at the five different time points. There is also a significant difference between the steroid and PRP groups. The comparison



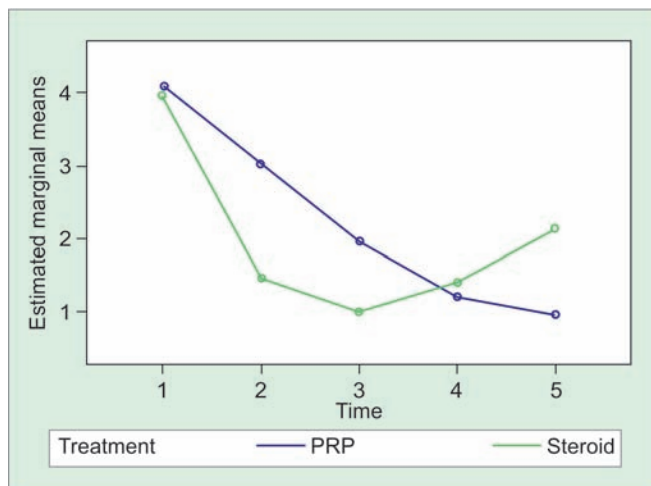
Fig. 1: Centrifugation machine REMI R-8C used for PRP preparation by double spin method

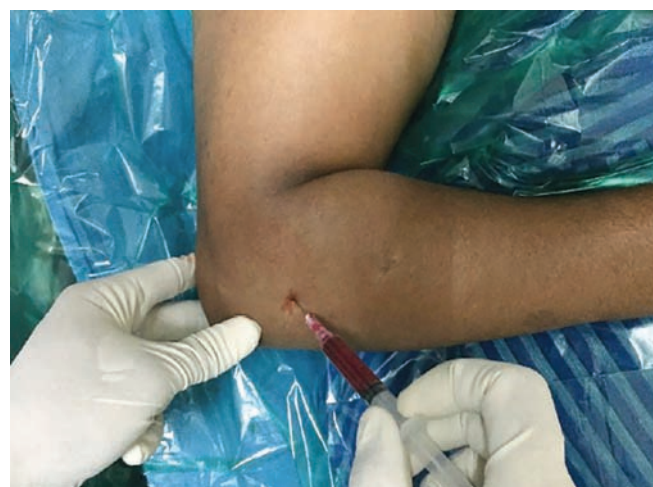

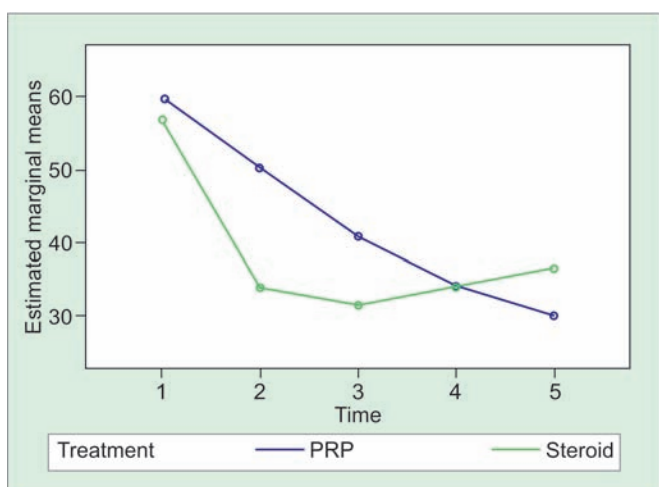
Fig. 2: Platelet-rich plasma mixture being injected into the point of maximal tenderness



Graph 1: Line graph depicting mean VAS scores for patients of PRP and CS according to follow-up time. The x-axis denotes the follow-up visit and the y-axis the VAS score range



Graph 2: Line graph depicting mean Nirschl scores for patients of PRP and CS according to follow-up time. The x-axis denotes the follow-up visit and the y-axis the Nirschl score range



Graph 3: Line graph depicting mean DASH scores for patients of PRP and CS according to follow-up time. The x-axis denotes the follow-up visit and the y-axis the DASH score

(with subject contrast) of each time point had significant difference with the previous time point and it also gives the evidence that between steroid and PRP group there is statistical significance between two groups, except for 2nd and 6th week ($p = 0.070$) (Graphs 1–3).

There was a statistically significant difference between the PRP and CS group at 2 weeks ($p < 0.00$), 6 weeks ($p < 0.00$), and 6 months ($p < 0.00$) (Table 2). At all other follow-up points, there was no statistically significant difference between the two subgroups with respect to the VAS, DASH, and Nirschl scores.

DISCUSSION

This randomized, prospective, single-blind study was designed to compare the use of concentrated autologous platelets to CS in patients with lateral epicondylitis; its application proved to be both safe and easy. The CS group

Table 1: Sociodemographic features of participants in both PRP and steroid groups (n = 60)

Characteristics		PRP (n = 30) median [interquartile range (IQR)]	Steroid (n = 30) median (IQR)	p-value
Age*		38.1 (9.3)	40.1 (8.15)	0.38
Duration of complaints (months)		6 (4–12)	6 (4–7)	0.37
Gender	Male	10	20	0.02
	Female	20	10	–

*Mean (standard deviation)

was actually better initially and then declined, returning to baseline level concerning functional impairment, while the PRP group progressively improved. There was a significant difference in decrease of pain and disability of function after the platelet application even after 1 year in initial cases of follow-up. Comparing the results presented here with the results of the 6 months follow-up, the effect in the CS group declined, whereas the result in the PRP group is maintained. A remarkable finding was that the PRP group had worse patient-rated VAS scores before treatment and better after 6 months of the initial treatment. This adds to the power of our conclusion that PRP was helpful.

Lateral epicondylitis is a common problem with many available treatment methods. The most commonly recommended treatment is physiotherapy and bracing. Approximately 87% of the patients benefit from this combination of treatment methods.⁴ Corticosteroid injection, nowadays seen as controversial, was considered the gold standard in the treatment of lateral epicondylitis. However, studies^{5,6} show it is merely the best treatment option for the short term, when compared with physiotherapy and a wait-and-see policy. Often, poor results are

Table 2: Outcome variables of participants in both PRP and steroid groups (n = 60)

Items	VAS (n = 60)				Nirschl (n = 60)				DASH (n = 60)			
	Steroid (n = 30)		PRP (n = 30)		Steroid (n = 30)		PRP (n = 30)		Steroid (n = 30)		PRP (n = 30)	
	Mean	SD	Mean	SD	Mean	SD	Mean	SD	Mean	SD	Mean	SD
At presentation	4.85	1.09	4.60	0.94	3.75	0.64	3.9	0.72	53.69	5.62	57.64	6.34
2 weeks	1.0	1.03	3.10	0.79	0.85	0.99	2.75	0.79	30.82	3.01	47.30	6.45
6 weeks	0.10	0.45	2.15	0.81	0.05	0.22	1.75	0.79	29.90	1.79	38.26	4.94
3 months	0.90	1.1	1.15	0.81	0.70	0.98	0.95	0.61	31.79	1.67	31.95	2.65
6 months	2.05	1.0	.55	0.69	1.85	0.86	0.50	0.51	34.06	1.55	28.26	1.48
n = 60	0.000				0.000				0.000			

SD: Standard deviation

seen after 3 months of follow-up.⁷ Treatment with CSs has a high frequency of relapse and recurrence, probably because intratendinous injection may lead to permanent adverse changes within the structure of the tendon and because patients tend to overuse the arm after injection as a result of direct pain relief.⁸ In our study, the recurrence rate and need for repeat injection was also larger in the CS group than in the PRP group. Actually, of the patients getting worse after the injection, the vast majority was found in the CS group.

We found no difference between the two groups with respect to age, gender, duration of symptoms, and duration of unsuccessful conservative treatment, which signifies that these factors were not confounding variables significant to create bias between the groups.

For those who do not recover, there are various types of surgical procedures for patients with chronic lateral epicondylitis. Nirschl and Pettrone⁹ noted an improvement in 60 to 70% of the patients after surgical treatment, although more recently higher success rates (80–90%) have been reported.¹³ Patients remain, however, interested in an alternative to surgical intervention.

Platelet-rich plasma is promoted as an ideal biologic autologous blood-derived product. It can be exogenously applied to various tissues, where after platelet activation, high concentrations of PDGF that enhance tissue healing are released. Utilizing the Recover system, the patient's own platelets can be collected into a highly concentrated formula. No activation agent was used during our procedure. The activation of the platelets will occur through the exposure of platelets to the thrombin. The thrombin is produced as a reaction to the injection of the platelets into the tendon tissue using a peppering technique.¹⁰ The exposed collagen may also serve as an activator. Several negative side effects are known when using bovine thrombin as an exogenous activator, limiting its clinical use: Undesirable immune responses in humans, and inhibition of cell proliferation and viability. This may be overcome when using an autologous-derived thrombin. Collagen is an attractive alternative to bovine thrombin as it is naturally involved in the

intrinsic clotting cascade. Roy et al¹¹ measured clinically relevant levels of TGF-beta (TGF- β 1), PDGF (PDGF-AB), and VEGF from both type I collagen-activated as well as bovine thrombin-activated PRP.

During the first 2 days of tendon healing, an inflammatory process is initiated by migration of neutrophils and subsequently macrophages to the degenerative tissue site. In turn, activated macrophages release multiple growth factors, including PDGF, TGF- α , and TGF- β , interleukin-1, and FGF. Angiogenesis and fibroplasia start shortly after day 3, followed by collagen synthesis on days 3 to 5. This process leads to an early increase in tendon breaking strength, which is the most important tendon healing parameter, followed by epithelialization and ultimately the remodeling process. This course of repair was confirmed in a previous animal study.¹²

The presence of an elevated concentration of leukocytes in the PRP is a topic of discussion nowadays. Companies that concentrate white blood cells argue that leukocytes are useful in creating an antibacterial response and have the ability to debride dead tendon tissue and jump-start healing (because they also contain growth factors). A basic study¹³ in horses showed no lengthening of the inflammation phase when PRP was used to treat an acute lesion of the tendon when compared with the control group. Companies that purposely eliminate white blood cells from PRP argue that leukocytes have detrimental effects on healing tissue, because of the enzymes from the matrix metalloproteinase family that are released by neutrophils. This is, however, not proven in prospective randomized controlled studies. The treatment of tendinosis with an injection of concentrated autologous platelets may be a nonoperative alternative. Injection of autologous platelets has been shown to improve repair in tendinosis in several animal and *in vitro* models.^{10,14,15} The effect of single injection PRP is shown to last longer than 1 year, while the percentage of success after a single CS injection drops from 51% at 1 year to 40% after 2 years of follow-up.¹⁶ A possible explanation for the longlasting effect of platelets could be that platelets improve the very early neotendon properties so that

the cells are able to perceive and respond to mechanical loading at an early time point.

With respect to pain, we found that both PRP and CS treatment significantly improves the VAS score in the short term (less than 6 weeks). Additionally, CS has better pain relief in the short term when compared with PRP; however, PRP has better pain relief in the long term (at 6 months) compared with the CS group. Based on this, pain relief for both PRP and CS for chronic lateral epicondylitis is better with CS offering better shorter term pain relief for the first month, whereas PRP offers better longer term pain relief at 6 months postinjection. These findings have been supported by previous studies.

With respect to function, both PRP and CS treatment significantly improved the Nirschl score and DASH score in the short term. Additionally, CS had a faster improvement in function *vs* PRP in the short term (first 6 weeks); however, in long-term follow-up, PRP patients had significantly better function *vs* the CS group. This is consistent with previous studies of function.¹⁷ Thus, both PRP and CS injections significantly improve function of patients with chronic lateral epicondylitis, with CS offering faster improvement in the short term, whereas PRP gives a slow but steady improvement in functional capacity over the natural course of the disease.

CONCLUSION

Platelet-rich plasma is the better treatment option to treat tennis elbow as there was no recurrence of symptoms or any associated complication till 6 months. The strength of this study lies in the fact that all the patients recruited had a chronic recalcitrant tennis elbow; they were prospectively assessed and randomized. The limitation of the study is the lack of blinding of the assessor to the treatment protocol, and a small sample size. Although the results show good efficacy of PRP compared with steroid, further validation by more subject recruitment is required. While no patients in the PRP group had recurrence, 6 patients who had recurrence in the steroid group were treated by PRP therapy and were found to have significant improvement in terms of pain and functional outcome as assessed by VAS score, Nirschl score, and DASH score.

REFERENCES

1. Cyriax JH. The pathology and treatment of tennis elbow. *J Bone and Joint Surg* 1936 Oct;18(4):921-940.
2. de Mos M, van Windt AE, Jahr H, van Schie HT, Weinans H, Verhaar JA, Van Osch GJ. Can platelet rich plasma enhance tendon repair: a cell culture study. *Am J Sports Med* 2008 Jun;36(6):1171-1178.
3. Anitua E, Andia I, Sanchez M, Azofra J, del Mar Zaldueño M, de la Fuente M, Nurden P, Nurden AT. Autologous preparations rich in growth factors promote proliferation and induce VEGF and HGF production by human tendon cells in culture. *J Orthop Res* 2005 Mar;23(2):281-286.
4. Lawson JH. The clinical use and immunologic impact of thrombin in surgery. *Semin Thromb Hemost* 2006 Feb;32(1):98-110.
5. Marx RE, Carlson ER, Eichstaedt RM, Schimmele SR, Strauss JE, Georgeff KR. Platelet-rich plasma: growth factor enhancement for bone grafts. *Oral Surg Oral Med Oral Pathol Oral Radiol Endod* 1998 Jun;85(6):638-646.
6. Molloy T, Wang Y, Murrell GA. The roles of growth factors in tendon and ligament healing. *Sports Med* 2003 Apr 1; 33(5):381-394.
7. Murray MM, Forsythe B, Chen F, Lee SJ, Yoo JJ, Atala A, Steinert A. The effect of thrombin on ACL fibroblast interactions with collagen hydrogels. *J Orthop Res* 2006 Mar;24(3):508-515.
8. Nirschl RP. Elbow tendinosis/tennis elbow. *Clin Sports Med* 1992 Oct;11(4):851-870.
9. Nirschl RP, Pettrone FA. Tennis elbow. The surgical treatment of lateral epicondylitis. *J Bone Joint Surg Am.* 1979 Sep 1; 61(6):832-839.
10. Peerbooms JC, Sluimer J, Bruijn DJ, Gosens T. Positive effect of an autologous platelet concentrate in lateral epicondylitis in a double-blind randomized controlled trial platelet-rich plasma versus corticosteroid injection with a 1-year follow-up. *Am J Sports Med* 2010 Feb;38(2):255-262.
11. Roy JS, MacDermid JC, Woodhouse LJ. Measuring shoulder function: a systematic review of four questionnaires. *Arthritis Rheum* 2009 May 15;61(5):623-632.
12. Sampson S, Gerhardt M, Mandelbaum B. Platelet rich plasma injection grafts for musculoskeletal injuries: a review. *Curr Rev Musculoskelet Med* 2008 Dec 1;1(3-4):165-174.
13. Sclafani AP, Romo T, Ukrainsky G, McCormick SA, Litner J, Kevy SV, Jacobson MS. Modulation of wound response and soft tissue ingrowth in synthetic and allogeneic implants with platelet concentrate. *Arch Facial Plast Surg* 2005 May-Jun 1;7(3):163-169.
14. Scott A, Khan KM, Roberts CR, Cook JL, Duronio V. What do we mean by the term "inflammation"? A contemporary basic science update for sports medicine. *Br J Sports Med* 2004 Jun 1; 38(3):372-380.
15. Wong SM, Hui AC, Tong PY, Poon DW, Yu E, Wong LK. Treatment of lateral epicondylitis with botulinum toxin: a randomized, double-blind, placebo-controlled trial. *Ann Intern Med* 2005 Dec 6;143(11):793-797.
16. Wrotniak M, Bielecki T, Ga dzik TS. Current opinion about using the platelet-rich gel in orthopaedics and trauma surgery. *Ortop Traumatol Rehabil* 2006 Dec;9(3):227-238.
17. Boushel R, Langberg H, Green S, Skovgaard D, Bülow J, Kjær M. Blood flow and oxygenation in peritendinous tissue and calf muscle during dynamic exercise in humans. *J Physiol* 2000 Apr 1;524(Pt 1):305-313.