

# Mandibular Canine Calcification as Skeletal Maturity Indicator

<sup>1</sup>K Vijayalakshmi, <sup>2</sup>G Suresh Sathiasekar

## ABSTRACT

**Objective:** The purpose of the study was to verify the relationship between mandibular canine calcification and skeletal maturity, and mandibular canine calcification could be used as a first-level diagnostic tool to estimate the timing of the pubertal growth spurt.

**Materials and methods:** Data were obtained from hand–wrist radiographs and intraoral periapical radiographs of left mandibular canine. Totally, 221 boys and 191 girls, the age ranging from 7 to 15 years, were selected to depict varying stages of growth. Kappa and t test statistics were applied. Skeletal age was determined as described by Greulich and Pyle, and the maturational patterns of the indicators were evaluated using the 11-grade system of Fishman. The stages from E to H as described by Demirjian’s stages of dental calcification were taken in this study instead of A to H.

**Results:** The epiphyseal widening for boys at 8.1 years and girls at 7.7 years, the ossification of the adductor sesamoid for boys at 12.2 years and for girls at 11.6 years, capping of epiphysis for boys at 11 years and for girls at 10 years, fusion of epiphysis in distal and middle phalanx in the third finger for boys at 13.8 years and for girls at 12.7 years, and fusion of epiphysis in the radius for boys at 14.4 years and for girls at 13 years were seen.

The relationship between the various stages of calcification of mandibular canine with skeletal age are as follows:

- *Boys:* Stage E at 6.4, stage F at 8.9 years, stage G at 10.9, and stage H at 14 years
- *Girls:* Stage E at 6.1, stage F at 8.2 years, stage G at 10.46, and stage H at 12.94 years.

The results showed stages E and F were coincident with the epiphyseal widening in the third finger proximal and middle phalanx and middle phalanx of the fifth finger. Stage G was coincident with the ossification of adductor sesamoid, capping of third finger middle phalanx, distal phalanx, and fifth finger middle phalanx, indicating its association with the accelerative phase of growth. Stage H was coincident with a fusion of proximal, middle, distal phalanx of the third finger, and fusion of radius, indicating its association with the decelerative phase of growth. Stage G was an ideal time for any orthodontic treatment, particularly functional appliances.

**Conclusion:** Based on the findings of this study, a close association existed between mandibular canine calcification stages and skeletal maturity indicators.

**Keywords:** Diagnostic tool, Mandibular canine calcification, Pubertal growth spurt, Skeletal maturity indicator.

**How to cite this article:** Vijayalakshmi K, Sathiasekar GS. Mandibular Canine Calcification as Skeletal Maturity Indicator. *World J Dent* 2017;8(2):119-128.

**Source of support:** Nil

**Conflict of interest:** None

## INTRODUCTION

The changes associated with maturation are evident in many parts of the body including the craniofacial skeleton and the dentition. Although the growth events occur in a reasonably constant sequence, the ages at which they are reached vary considerably among the children. The knowledge of the skeletal maturation and the craniofacial growth influence the treatment plan and eventual outcome of the dentofacial orthopedic and orthognathic surgical treatment.<sup>1</sup> During the pubertal spurt, the velocity of growth is greater than at any other time, which is favorable for orthodontic treatment to be undertaken.

Basically, three common approaches have been used in the past to assess the hand–wrist radiographs. First was the atlas system involved the matching of a hand–wrist radiograph with a standard series of chronologically oriented radiographic images.<sup>2</sup> A second assessment variation involved matching features of many individual bones and then assigning point scores in the stages revealed.<sup>3</sup> The third method emphasized alteration in bony shapes and established ratios between linear measurements of the long bones of the hand and wrist, the grading of the indicators, and ratios was then calculated to determine the skeletal age.<sup>4</sup>

A more accurate assessment of physical development may be made by the radiographic examination of the calcified structures of the hand and wrist from which the degree of maturity of individual bones may be assessed and the skeletal age determined by comparison with published radiographic standards.

The onset of ossification of the ulnar sesamoid of the first metacarpal phalangeal joint, Hook of Hamate, and capping of third and fifth phalanges are said to be

<sup>1</sup>Department of Orthodontics, Adhiparasakthi Dental College & Hospital, Kanchipuram, Tamil Nadu, India

<sup>2</sup>Department of Orthodontics and Dentofacial Orthopaedics Rajas Dental College & Hospital, Tirunelveli, Tamil Nadu India

**Corresponding Author:** K Vijayalakshmi, Department of Orthodontics, Adhiparasakthi Dental College & Hospital Kanchipuram, Tamil Nadu, India, Phone: +919842052014 e-mail: [viji\\_ortho@yahoo.com](mailto:viji_ortho@yahoo.com)

closely related to timing with the adolescent spurt in stature height.

Dental eruption is much more variable in its timing than dental maturation<sup>5,6</sup> and is influenced by local and environmental factors.<sup>7</sup> Therefore, the assessment of the maturation stages of teeth was the method of choice for this study. Thus, indicators of developmental age are more informative than chronological age, particularly for clinical application.<sup>8,9</sup> An interrelationship among skeletal, somatic, and sexual maturity has been shown to be consistently strong associations with dental maturation.<sup>8,10</sup> Interestingly, correlation between calcification stages of individual tooth and skeletal maturity have also been previously reported.<sup>1,8,9,11-13</sup>

The purpose of this study was to verify:

- The relationships between mandibular canine calcification and skeletal maturity.
- Whether the stages of calcification of the mandibular canine could be used as a first-level diagnostic tool to estimate the timing of the pubertal growth spurt.

## MATERIALS AND METHODS

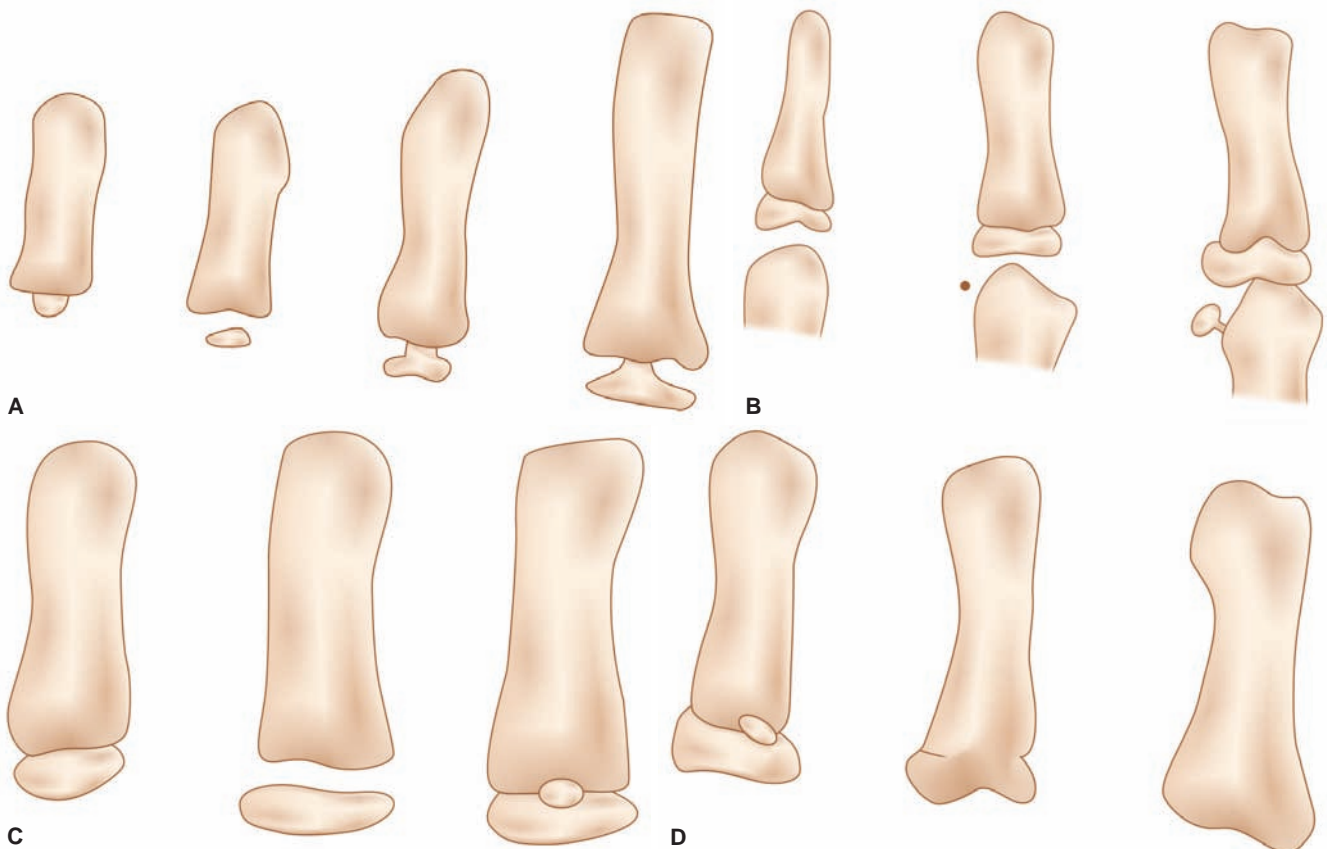
This cross-sectional study consisted of the sample of 221 boys and 191 girls studying between standard II and XI of a particular school. Hand-wrist radiographs

and intraoral periapical radiographs of mandibular canine were obtained on the left side of the subject. The skeletal age was determined from hand-wrist radiographs according to the methods described by Greulich and Pyle where the radiograph in question is compared with a series of standard reference plates.<sup>14</sup>

To evaluate the maturational patterns of the indicators in the hand and wrist, the 11-grade system of Fishman<sup>15</sup> was used. Currently, skeletal maturation system of Fishman is commonly used. This technique offers an organized and relatively simple approach to determine the level of maturation. This system used only four stages of bone maturation, all found at six anatomical sites located on the thumb, third finger, fifth finger, and radius. Eleven discrete adolescent developments are found on these six sites.

The sequence of the four ossifications stages progresses through the epiphyseal widening on selected phalanges, the ossification of the adductor sesamoid of the thumb, the “capping” of selected epiphysis over their diaphysis, and the fusion of the selected epiphysis and diaphysis (Figs 1A to D).

Widening of the epiphysis relative to its diaphysis is a progressive process. The epiphysis first appears as a small center of ossification centrally located in the diaphysis. When it has developed laterally to the width



**Figs 1A to D:** Radiographic identification of skeletal maturity indicators: (A) Epiphysis equal in width to diaphysis; (B) appearance of adductor sesamoid of the thumb; (C) capping of epiphysis; and (D) fusion of epiphysis

of the diaphysis, it is considered to be applicable as a skeletal maturational indicator (SMI) in this system.

Capping occurs in the transition between initial widening and fusion of the epiphysis and the diaphysis. It is the stage in which the rounded lateral margins of the epiphysis begin to flatten and point toward the diaphysis with an acute angle on the side facing the diaphysis. The time of the first appearance of the capping is applicable as an SMI.

Fusion between the epiphysis and diaphysis follows capping. It also begins centrally and progresses laterally until the two formerly separate bones become one. The time of completion of this fusion with a smooth continuity of the surface at the junction area is applicable as an SMI.

Ossification of the adductor sesamoid of the thumb first appears as a small relatively round center of ossification medial to the junction of epiphysis and diaphysis to the proximal phalanx. It then becomes progressively larger and denser. It is the first observation of the existence of this bone, i.e., applicable as an SMI.

The individual maturity indicators are listed below (Fig. 2):

- Skeletal maturational indicator
  - Third finger – Proximal phalanx
  - Third finger – Middle phalanx
  - Fifth finger – Middle phalanx
- Ossification
  - Adductor sesamoid of thumb
- Capping of epiphysis
  - Third finger – Distal phalanx

- Third finger – Middle phalanx
- Fifth finger – Middle phalanx
- Fusion of epiphysis and diaphysis
  - Third finger – Distal phalanx
  - Third finger – Proximal phalanx
  - Third finger – Middle phalanx
  - Radius

Intraoral periapical radiograph of the mandibular canine (left side) was obtained by the bisecting angle technique.

The teeth were rated according to the technique described by Demirjian's stages of dental calcification where the development of the tooth was divided into eight defined stages identified by the letters A to H. The stages described to teeth in this study ranged from E to H. Each of these stages was recognized by the following criteria (Figs 3A to H).

All assessments were done with utmost care to ensure accurate and reliable data. Further to rule out any error existing, a trained colleague was asked to assess a random sample of 6% of the study.

**Statistical Methods Utilized**

- Interexaminer relationship – Kappa statistics
- Relationship between chronological: t-test/Z-test and skeletal age
- Relationship between skeletal age and SMIs
- Interrelationship between SMIs
- Relationship between calcification stages and skeletal age – Chi-square statistic
- Relation between calcification stages and SMIs

**RESULTS**

In this study, to ensure the reliability of the various assessments, Kappa statistic was used. For all the skeletal maturity indicators, Kappa statistic was +1 and analyzing the tooth stages, Kappa statistics was 0.94. This indicates a high interexaminer relationship. For skeletal age, systematic errors between examiners were not significant; the random method error was approximately 0.06 years.

Table 1 shows that t test was applied to show the mean and standard deviation for chronological and skeletal age values for both boys and girls. The mean chronological age was for boys being 11.32 years with a standard deviation of 2.18 and the girls being 11.13 years with the

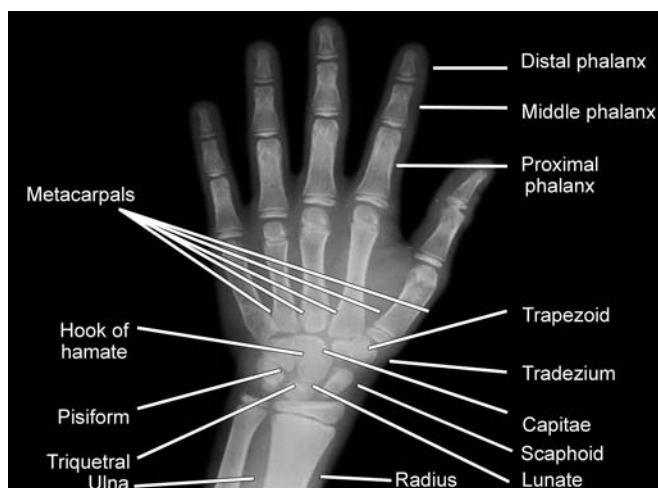


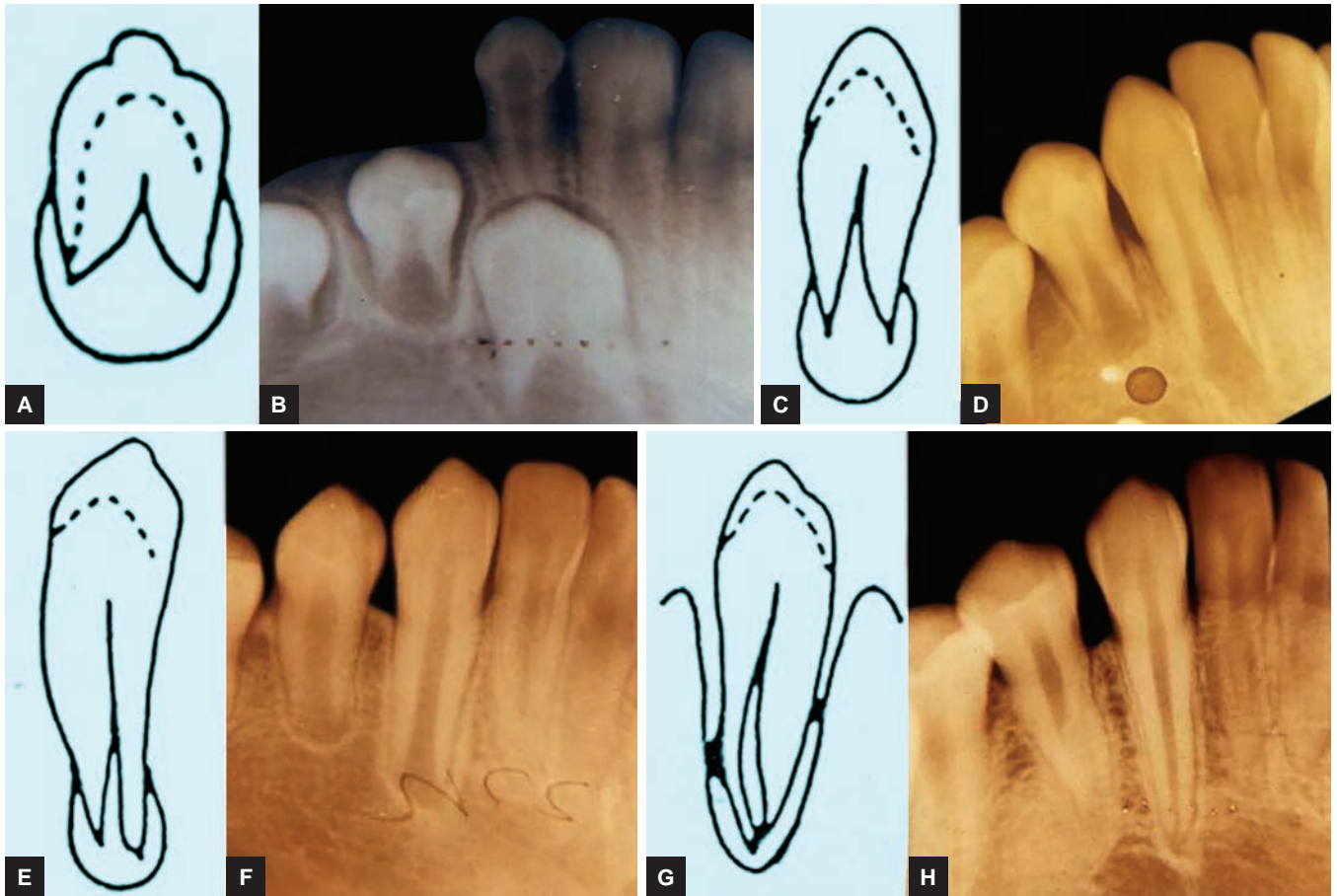Fig. 2: Hand–Wrist X-ray with phalanges, carpals, and metacarpals

Table 1: Sex-wise mean of chronological and skeletal ages

	Boys		Girls		Significance
	Number	Mean ± SD	Number	Mean ± SD	
Chronological age	221	11.32 ± 1.98	191	11.13 ± 2.18	NS
Skeletal age	221	9.06 ± 2.26	191	9.54 ± 2.45	p<0.05

SD: Standard deviation, NS: Not significant





**Figs 3A to H:** Demirjian's stages of mandibular canine calcification. Stage E (A and B): The walls of the pulp chamber from straight lines whose continuity is broken by the presence of the pulp horn. The root length is less than the crown height. Stage F (C and D): The walls of the pulp chamber now form a more or less isosceles triangle. The apex ends in a funnel shape. The root length is equal to or greater than the crown height. Stage G (E and F): The walls of the root canal are now parallel and its apical end still partially open. Stage H (G and H): The apical end of the root canal is completely closed. The periodontal membrane has a uniform width around the root and the apex

standard deviation of 2.18. The test of significance was not significant.

The mean skeletal age for boys was 9.06 years, with a standard deviation of 2.26, and the girls being 9.54 years with a standard deviation of 2.45. The skeletal age for girls is found to be advanced than the boys. Test of significance showed at  $p < 0.05$ .

Table 2 shows the relationship between skeletal age and the 11 skeletal maturity indicators for both boys and girls.

### Boys

- The epiphyseal widening in the third finger proximal and middle phalanx and the fifth finger middle phalanx occurs at about the same time: 8.1 years with a standard deviation of 1.8.
- The ossification of the adductor sesamoid is at 12.2 years with a standard deviation of 1.6.
- The capping of the epiphysis in the third finger distal and middle phalanx and the fifth finger middle phalanx occurs at about the same time 11.0 years, with a standard deviation of 0.09.

- The fusion of the epiphysis in distal phalanx and the middle phalanx in the third finger occurs at 13.8 years with a standard deviation of 0.5.
- The fusion of the epiphysis in the proximal phalanx in the third finger occurs at 14.3 years with a standard deviation of 0.5.
- The fusion of the epiphysis in the radius occurs at 14.4 years with a standard deviation of 1.2.

### Girls

- The epiphyseal widening in the third finger proximal, middle phalanx, and the fifth finger middle phalanx occurs at about 7.7 years with a standard deviation of 1.4.
- The ossification of the adductor sesamoid occurs at 11.6 years, with a standard deviation of 1.7.
- The capping of the epiphysis in the third finger distal and middle phalanx and the fifth finger middle phalanx occurs at about 10.0 years with a standard deviation of 0.9.

- The fusion of the epiphysis in the third finger distal, middle, and proximal phalanx occurs at 12.7 years with a standard deviation of 1.6.
- The fusion of the epiphysis in the radius occurs at about 13.0 years with a standard deviation of 1.4.

Table 2 results show that the ossification of the adductor sesamoid, capping, and fusion of epiphysis for girls are faster than boys.

Table 3 shows the interrelationship between maturity indicators in boys with the Chi-square values in the parenthesis.

Along with the epiphyseal widening in the third finger proximal phalanx, epiphyseal widening is also seen in the middle phalanx of the third finger and middle phalanx of the fifth finger to the same extent. All the above indicators occur in unison, indicating prepubertal growth, however, two individuals were seen with capping of epiphysis in the third finger distal and middle phalanx.

Along with the ossification of the adductor sesamoid, epiphyseal capping is seen in the middle, distal phalanx of the third finger, and middle phalanx of the fifth finger to the same extent, indicating a pubertal peak. Nine individuals have shown a fusion of the epiphysis in the distal, middle, proximal phalanges of the third finger with seven individuals showing a fusion of the epiphysis in the radius, indicating a decline of growth.

The interrelationships found to exist between epiphyseal widening in the third finger proximal, middle phalanx, and fifth finger middle phalanx: Epiphyseal capping in the middle distal phalanx of the third finger; middle phalanx of the fifth finger and fusion of distal; and middle proximal phalangeal of the third finger and fusion of epiphysis in the radius associated with prepubertal growth, accelerative, and decelerative phase respectively.

Table 4 shows the interrelationship between the skeletal maturity indicators in girls with the Chi-square given in parenthesis.

Along with the epiphyseal widening in the third finger proximal phalanx, epiphyseal widening was also seen in the middle phalanx of the third finger to the same extent. All the above indicators occur in unison, indicating prepubertal growth.

Along with the ossification of the adductor sesamoid, epiphyseal capping is seen in the middle, distal phalanx of the third finger and middle phalanx of the fifth finger to the same extent, indicating a pubertal peak; 48 individuals have shown a fusion of epiphysis in the distal phalanges and 49 individuals in the proximal phalanx of the third finger, with 36 individuals showing a fusion of epiphysis in the radius, indicating a decline of growth.

Interrelationships found to exist between epiphyseal widening in the third finger proximal, middle phalanx

Table 2: Mean skeletal ages for the various skeletal maturity indicators

	1	2	3	4	5	6	7	8	9	10	11
<b>Boys</b>											
Mean ± SD	8.15 ± 1.81	8.17 ± 1.82	8.17 ± 1.82	8.17 ± 1.82	11.04 ± 0.94	11.04 ± 0.94	11.04 ± 0.94	11.00 ± 0.94	13.88 ± 1.53	14.37 ± 0.51	14.42 ± 1.27
<b>Girls</b>											
Mean ± SD	7.73 ± 1.49	7.73 ± 1.49	7.73 ± 1.49	7.73 ± 1.49	10.06 ± 0.93	10.06 ± 0.93	10.06 ± 0.93	10.06 ± 0.93	12.72 ± 1.57	12.70 ± 1.61	13.03 ± 1.46
SD: Standard deviation											

Table 3: Interrelationship between the SMIs – boys

Sl. no.	1	2	3	4	5	6	7	8	9	10	11	SMI's total
1	-	159 (211.5)	159 (211.5)	2 (163.6)	2 (163.6)	2 (163.68)						161
2		-	159 (221)									159
3			-									159
4				-	20 (38.29)	20 (38.29)	20 (38.29)	9 (62.12)	9 (54.29)	9 (62.12)	67 (47.86)	29
5					-	52 (221)	50 (210)					52
6						-	50 (210)					52
7							-					50
8								-	6 (197.9)	9 (221)	7	9
9									-	69 (197.96)	37 (152.53)	10
10										-	7 (170.28)	9
11											-	7

Association between the SMIs for number (Chi-square values are given in parenthesis); p < 0.01

Table 4: Interrelationship between the SMIs – girls

Sl. no.	1	2	3	4	5	6	7	8	9	10	11	SMI's total
1	-	95 (191)	595 (191)	-	-	30 (13.55)	30 (38.29)	648 (88.96)	49 (91.45)	48 (88.96)	36 (61.56)	95
2	-	-	95 (191)	-	-	46 (191)	46 (191)	-	-	-	-	95
3	-	-	-	-	-	-	46 (191)	-	-	-	-	95
4	-	-	-	-	30 (13.555)	30 (13.55)	30 (38.29)	648 (88.96)	49 (91.45)	48 (88.96)	36 (61.56)	80
5	-	-	-	-	-	46 (191)	46 (191)	-	-	-	-	46
6	-	-	-	-	-	-	46 (191)	-	-	-	-	46
7	-	-	-	-	-	-	-	-	-	-	-	46
8	-	-	-	-	-	-	48 (185.79)	-	48 (185.79)	48 (191)	36 (132.16)	48
9	-	-	-	-	-	-	-	-	-	9489 (185.79)	636 (128.56)	49
10	-	-	-	-	-	-	-	-	-	-	36 (132.16)	48
11	-	-	-	-	-	-	-	-	-	-	-	36

Association between the SMIs for number (Chi-square values are given in parenthesis); p<0.01

and fifth finger middle phalanx: Epiphyseal capping in the middle, distal phalanx of the third finger, middle phalanx of the fifth finger and fusion of the distal, middle, proximal phalanges of the third finger, fusion of epiphysis in the radius, associated with prepubertal, accelerative, and decelerative phase respectively.

Table 5 shows the relationship between the various stages of calcification of mandibular canine with skeletal age.

**Boys**

- Stage E is present in 6.4 years with a standard deviation of 1.4 years
- Stage F is present in 8.9 years with a standard deviation of 1.6 years
- Stage G is present in 10.9 years with a standard deviation of 1.4 years
- Stage H is present in 14 years with a standard deviation of 1.2 years. Test of significance showed p<0.01.

**Girls**

- Stage E is present in 6.1 years with a standard deviation of 1.2 years.
- Stage F is present in 8.2 years with a standard deviation of 1.2 years.
- Stage G is present in 10.46 years with a standard deviation of 1.4 years.
- Stage H is present in 12.94 years with a standard deviation of 1.9 years. Test of significance showed p<0.01.

Table 5 results reveal that when compared with boys, the tooth mineralization stages in girls appeared to be more advanced in the same skeletal maturation period.

Tables 6A to F show the relationship between the various stages of mandibular canine calcification of skeletal maturity indicators for males.

Stages E and F are coincident with the epiphyseal widening in the third finger proximal, middle phalanx and middle phalanx of the fifth finger. Test of significance showed significance at p<0.01.

Stage G is coincident with the ossification of adductor sesamoid, capping of the third finger, middle phalanx, distal phalanx, and fifth finger middle phalanx, indicating its association with the accelerative phase of growth. Test of significance showed significance at p<0.01 (Figs 4A and B).

Stage H is coincident with a fusion of proximal, middle, distal phalanx of third finger and fusion of radius, indicating its association with the decelerative phase of growth. Test of significance showed significance at p<0.01 (Figs 4A and B).

Tables 7A to F show the relationship between the various stages of mandibular canine calcification with skeletal maturity indicators for females.



**Table 5:** Mean skeletal age for the various tooth stages

	<i>E</i>	<i>F</i>	<i>G</i>	<i>H</i>	<i>Test of sign</i>
<i>Male</i>					
Mean ± SD	6.4 ± 1.4	8.9 ± 1.6	10.92 ± 1.4	14.0 ± 1.2	p<0.01
<i>Female</i>					
Mean ± SD	6.14 ± 1.2	8.2 ± 1.2	10.46 ± 1.4	12.94 ± 1.9	p<0.01

SD: Standard deviation

**Table 6A:** Frequency distributions of skeletal maturity indicators by stages of mandibular canine maturity in boys. Adductor sesamoid (4)

<i>Tooth stage</i>	<i>Present</i>	<i>Absent</i>	<i>Total</i>
E	0	45	45
F	4	110	114
G	20	37	57
H	5	0	5

Chi-square = 112.73; p&lt;0.01

**Table 6B:** Third finger – proximal phalanx (1, 9)

<i>Tooth stage</i>	<i>1 (+)</i>	<i>9 (+)</i>	<i>Absent</i>	<i>Total</i>
E	45	0	0	45
F	98	0	16	114
G	18	5	34	57
H	0	5	0	5

Chi-square = 187.15; p&lt;0.01; 1 – appearance, widening; 9 – fusion

**Table 6C:** Third finger – middle phalanx (2, 6, 10)

<i>Tooth stage</i>	<i>2 (+)</i>	<i>6 (+)</i>	<i>10 (+)</i>	<i>Absent</i>	<i>Total</i>
E	45	0	0	0	45
F	98	16	0	0	114
G	16	16	4	1	57
H	0	0	5	0	5

Chi-square = 392.574; p&lt;0.01; 2 – appearance, widening; 6 – capping; 10 – fusion

**Table 6D:** Third finger – distal phalanx (5, 8)

<i>Tooth stage</i>	<i>5 (+)</i>	<i>8 (+)</i>	<i>Absent</i>	<i>Total</i>
E	0	0	45	45
F	16	0	98	114
G	36	4	17	57
H	0	5	0	5

Chi-square = 202.57; p&lt;0.01; 5 – capping; 8 – fusion

**Table 6E:** Fifth finger – middle phalanx (3, 7)

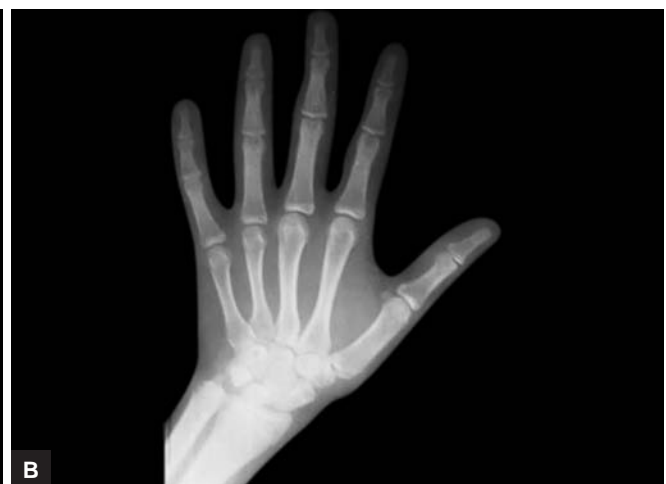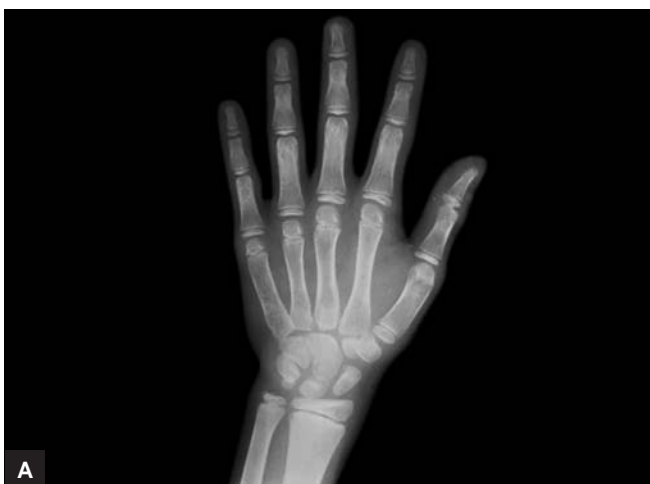<i>Tooth stage</i>	<i>3 (+)</i>	<i>7 (+)</i>	<i>Absent</i>	<i>Total</i>
E	45	0	0	45
F	98	16	0	114
G	16	34	7	57
H	0	0	5	5

Chi-square = 172.92; p&lt;0.01; 3 – appearance, widening; 7 – capping

**Table 6F:** Radius (fusion) = 11

<i>Tooth stage</i>	<i>Present</i>	<i>Absent</i>	<i>Total</i>
E	0	45	45
F	0	114	114
G	2	55	57
H	5	0	5

Chi-square = 166.88; p&lt;0.01

**Figs 4A and B:** Coincidence of (A) stage G with capping and (B) stage H with fusion

Stages E and F are coincident with the epiphyseal widening in the third finger proximal, middle phalanx and middle phalanx of the fifth finger. Test of significance showed significance at p<0.01.

Stage G is coincident with the ossification of adductor sesamoid, capping of the third finger, middle phalanx, distal phalanx, and fifth finger middle phalanx, indicating its association with the accelerative



**Table 7A:** Frequency distributions of skeletal maturity indicators by stages of canine maturity in girls. Adductor sesamoid (4)

Tooth stage	Present	Absent	Total
E	0	25	25
F	4	55	59
G	53	29	82
H	22	3	25

Chi square = 87.48;  $p < 0.01$

**Table 7C:** Third finger – middle phalanx (2, 6, 10)

Tooth stage	2 (+)	6 (+)	10 (+)	Absent	Total
E	25	0	0	0	25
F	50	7	1	1	59
G	19	34	28	1	82
H	1	5	19	0	25

Chi-square = 117.93;  $p < 0.01$ ; 2 – appearance, widening; 6 – capping; 10 – fusion

**Table 7E:** Fifth finger – middle phalanx (3, 7)

Tooth stage	3 (+)	7 (+)	Absent	Total
E	25	0	0	25
F	50	7	2	59
G	19	34	29	82
H	1	5	19	25

Chi-square = 114.174;  $p < 0.01$ ; 3 – appearance, widening; 7 – capping

**Table 7B:** Third finger – proximal phalanx (1, 9)

Tooth stage	1 (+)	9 (+)	Absent	Total
E	25	0	0	25
F	50	2	7	59
G	19	28	35	82
H	1	19	5	25

Chi-square = 115.40;  $p < 0.01$ ; 1 – appearance, widening; 9 – fusion

**Table 7D:** Third finger – distal phalanx (5, 8)

Tooth stage	5 (+)	8 (+)	Absent	Total
E	0	0	25	25
F	7	1	51	59
G	34	29	19	82
H	5	19	1	25

Chi-square = 117.80;  $p < 0.01$ ; 5 – capping; 8 – fusion

**Table 7F:** Radius (fusion) = 11

Tooth stage	Present	Absent	Total
E	0	25	25
F	0	59	59
G	17	65	82
H	19	6	25

Chi-square = 73.12;  $p < 0.01$

phase of growth. Test of significance showed significance at  $p < 0.01$ .

Stage H is coincident with a fusion of proximal, middle, distal phalanx of third finger and fusion of radius, indicating its association with the decelerative phase of growth. Test of significance showed significance at  $p < 0.01$ .

## DISCUSSION

Bones and joints, such as carpals, the femur, the elbow joint, the shoulder joint, cervical vertebrae, and skull could be used to assess maturation; however, the best information can be obtained from the hand and wrist primarily because hands are of easy access. Within a small area, they have a large number of bones and epiphysis. By utilizing the onset of events in ossification centers, the degree of calcification, and the size and shape of the carpal bones, the skeletal age of an individual can easily be determined.

Various techniques and standards are available to assess skeletal age and it has been said that they are generally in agreement.

The time of occurrence of certain ossification events in relation to the spurt of growth has also been frequently used to evaluate skeletal maturity. Although with this method, prediction improves as the growth spurt approaches, there are limitations for early

prediction of the ossification events and methods. Hence, serial observations are required.

In a radiograph of the hand–wrist area, not all ossification events or bone stages are used simultaneously at any time throughout the growth period. During early childhood (before the age of 6 years), the carpals can be used during late childhood and puberty as the changes occurring in the metacarpal and phalanges provide better information.

Rasool et al,<sup>16</sup> Chapman,<sup>17</sup> and Pileski et al<sup>18</sup> stated that the adductor sesamoid of the thumb always ossified before puberty. Hence, the observation of the initial ossification of the sesamoid will help us to conclude that the maximum pubertal growth is ahead and growth modification treatment can be initiated, so that advantage of this period of growth can be utilized to enhance the result of orthodontic treatment.

Numerous avenues of research have developed to test the relationship of (A) tooth eruption with skeletal maturation and/or growth in stature and (B) root formation or crown calcification with skeletal maturation.

Most of the abovementioned studies showed varying degrees of nonassociation to good correlation with skeletal maturation play some part in the development of the dentition. Goyal et al,<sup>19</sup> Divyashree et al,<sup>20</sup> and Tancan Uysal<sup>12</sup> said the mineralization stages of the mandibular canine correlated well as a maturity indicator. It was the





purpose of this study to correlate the above factors in this area of population and to evaluate its usefulness in clinical situations.

Intraoral periapical radiographs were selected because of easy accessibility and less complexity to the clinician.

The findings of this study show a difference of 2.2 years for boys and 1.5 years for girls between chronological age and skeletal age caused by the differential maturational process between the sexes. This finding agreed with the information published in several studies.<sup>1,2</sup> The phalangeal maturity indicators indicated the following:

Skeletal maturational indicator's (1–3) epiphyseal widening in the middle and proximal phalanx of the third finger and middle phalanx of the fifth finger was found to indicate the stage preceding pubertal peak occurred at 8.1 years for boys and 7.7 years for girls.

Skeletal maturational indicator's (4–7) ossification of adductor, sesamoid, epiphyseal capping in the proximal and middle phalanges of the third finger and the middle phalanx of the fifth finger was found to indicate the pubertal peak of growth. These changes were seen to occur between the skeletal ages of 11 and 12.2 years for boys and between 10 and 11.6 years for girls.

Skeletal maturational indicator's (8–10) epiphysis fusion in the distal, proximal, and middle phalanges of the third finger was found to indicate a decline of growth.

Skeletal maturational indicator's (11) epiphyseal fusion of the radius correlated with cessation of growth.

The mean skeletal ages for the changes seen in SMIs (8–11) were between 13.8 and 14.4 years for boys and between 12.6 and 13 for girls.

All the above findings of this study were found to correlate with the studies of Fishman,<sup>15</sup> and Grave and Brown.<sup>21</sup> Skeletal maturational indicators (1–3) are present during the prepubertal growth period and SMIs (4–7) with the pubertal peak with SMIs (8–11), indicating decline and end of the growth.

The relationship between calcification of the mandibular canine and skeletal maturity indicators in this study were high. Canine calcification stages E and F coincided with an epiphyseal widening in fifth finger middle phalanx and third finger distal and middle phalanx representing the state of the prepubertal peak.

Stage G is coincident with ossification of the adductor sesamoid and epiphyseal capping in third finger middle, distal phalanges and fifth middle phalanx, indicating a state of the pubertal peak.

Stage H coincides with epiphyseal fusion in distal, proximal, middle phalanges of the third finger and radius, indicating decline and the end of the growth.

The associations are similar to those reported by Goyal et al<sup>19</sup> who used the ossification method of staging. The results corroborate and extend the findings of Uysal et al<sup>12</sup> and Hegde et al,<sup>22</sup> showing a close relationship

between mandibular canine calcification stages and skeletal maturity indicators of pubertal growth spurt.

Therefore, the high associations found in this study might be related to the use of the mandibular canine rather than a composite of dental units. Moreover, use of multiple stages in canine development covers a wider range of maturity to produce higher relationships than the age of eruption.

Based on the findings of this study, the calcification state of mandibular canine can also be used to interpret the skeletal ages of both boys and girls as the interpretations of skeletal age from hand–wrist radiographs.

- Stage E was found to occur at 6.4 years for boys and at 6.1 years for girls.
- Stage F was found to occur at 8.9 years for boys and at 8.2 years for girls.
- Stage G was found to occur at 10.9 years for boys and at 10.4 years for girls.
- Stage H was found to occur at 14 years for boys and at 12.9 years for girls.

## CONCLUSION

For clinicians contemplating the initiation of orthopedic treatment, continual monitoring of skeletal maturity through hand–wrist films may not be necessary to estimate peak pubertal growth velocity. Instead, they can monitor the root development of the mandibular canine with periapical or panoramic radiographs, which are more readily available and easily interpreted. Orthodontists should use the demonstrated relationships between canine root development and skeletal maturity to estimate the expected sequence of the future developmental events.

When a child's skeletal age is advanced in comparison to his chronological age, less growth can be anticipated. Conversely, if the child's skeletal age is behind his/her chronological age, then a greater growth potential may be assumed and incorporated into the treatment plan.

The relationship between the stages of tooth mineralization of the mandibular canine and skeletal maturity indicators in this study were high.

Reliability on the calcification stage of the mandibular canine can be done with a similar degree of confidence as the skeletal maturity indicators of the hand and wrist. However, racial variations might exist in the relationship between the state of maturity of this tooth and the skeletal maturity indicators. Caution should thus be exercised in the application of these findings to other racial groups.

## REFERENCES

1. Krailassiri S, Anuwongnukroh N, Dechkunakorn S. Relationships between dental calcification stages and skeletal maturity indicators in Thai individuals. *Angle Orthod* 2002 Apr;72(2):155-166.

2. Pyle SI, Waterhouse AM, Greulich WW. A radiographic standard of reference for the growing hand and wrist. 1st ed. Chicago: Press of Case Western Reserve University; 1971.
3. Tanner JM, Whitehouse RH, Marshall WA, Healy MJ, Goldstein H. Assessment of skeletal maturity and prediction of adult height (TW2 Method). London: Academic Press; 1975.
4. Roche AF, Chumlea WC, Thissen D. Assessing the skeletal maturity if the hand-wrist (Fels Method). 2nd ed. Springfield, IL: Charles C Thomas; 1988.
5. Chalkoo AH, Nailkoo FA, Ahmad MB. Dental age assessment using Nolla's method and skeletal age assessment by hand wrist radiograph among Kashmiri children – a comparative study. *Br Biomed Bull* 2016 Feb;4(1):9-14.
6. Litsas G, Lucchese A. Dental and chronological ages as determinants of peak growth period and its relationship with dental calcification stages. *Open Dent J* 2016 Apr;10(1):99-108.
7. Demirjian A, Goldstein H, Tanner JM. A new system of dental age assessment. *Hum Biol* 1973 May;45(2):211-227.
8. Chen J, Hu H, Guo J, Liu Z, Liu R, Li F, Zou S. Correlation between dental maturation and cervical vertebral maturation. *Oral Surg Oral Med Oral Pathol Oral Radiol Endod* 2010 Dec;110(6):777-783.
9. Kumar S, Singla A, Sharma R, Viridi MS, Anupam A, Mittal B. Skeletal maturation evaluation using mandibular second molar calcification stages. *Angle Orthod* 2012 May;82(3):501-506.
10. Rozylo-Kalinowska I, Kolasa-Raczka A, Kalinowski P. Relationship between dental age according to Demirjian and cervical vertebrae maturation in Polish children. *Eur J Orthod* 2011 Feb;33(1):75-83.
11. Coutinho S, Buschang PH, Miranda F. Relationships between mandibular canine mineralization stages and skeletal maturation. *Am J Orthod Dentofacial Orthop* 1993 Sep;104(3):262-268.
12. Uysal T, Sari Z, Ramoglu SI, Basciftci FA. Relationships between dental and skeletal maturity in Turkish subjects. *Angle Orthod* 2004 Oct;74(5):657-664.
13. Motghare PC, Bedia AS, Degwekar SS, Indurkar AD, Bedia S. Correlation of calcification of permanent mandibular canine, mandibular premolars and permanent mandibular first and second molars with skeletal maturity in Indian population. *J Forensic Dent Sci* 2016 May-Aug;8(2):67-73.
14. Hackman L, Black S. The reliability of the Greulich and Pyle atlas when applied to a modern Scottish population. *J Forensic Sci* 2013 Jan;58(1):114-119.
15. Fishman LS. Radiographic evaluation of skeletal maturation. A clinically oriented method based on hand-wrist films. *Angle Orthod* 1982 Apr;52(2):88-112.
16. Rasool G, Khalid A, Awaisi ZH. Pubertal growth spurt age in local population – a study. *Pak Oral Dent J* 2011 Jun;31(1):78-83.
17. Chapman SM. Ossification of the adductor sesamoid and the adolescent growth spurt. *Angle Orthod* 1972 Jul;42(3):236-244.
18. Pileski RC, Woodside DG, James GA. Relationship of the ulnar sesamoid bone and maximum mandibular growth velocity. *Angle Orthod* 1973 Apr;43(2):162-170.
19. Goyal S, Goyal S, Gugnani N. Assessment of skeletal maturity using the permanent mandibular canine calcification stages. *J Orthod Res* 2014 Jan;2(1):11-16.
20. Divyashree R, Dinesh MR, Amarnath BC. Reliability of permanent mandibular canine calcification as an indicator of skeletal maturity in Karnataka population. *World J Dent* 2010 Apr-Jun;1(1):7-11.
21. Iguma KE, Tavano O, Carvalho IM. Comparative analysis of pubertal growth spurt predictors: Martins and Sakima method and Grave and Brown method. *J Appl Oral Sci* 2005 Mar;13(1):58-61.
22. Hegde G, Hegde N, Kumar A, Keshavaraj. A new system for assessment of growth using mandibular canine calcification stages and its correlation with modified MP3 stages. *J Pharm Bioallied Sci* 2014 Jul;6(Suppl 1):S58-S63.