

CASE REPORT

Supernumerary Teeth in Premolar and Molar Regions and their Effect on Overall Restorative Treatment Plan

Sadhana A Raina

ABSTRACT

Supernumerary tooth, also known as hyperdontia, is the condition where more than the normal number of teeth is present. By definition, the supernumerary teeth are the extra teeth present in the oral cavity. They can be found in the region of oral cavity, but are common in the maxilla than mandible.

Supernumerary teeth may be encountered by the dental practitioner as a chance finding on a radiograph or as the cause of an impacted central incisor. Their presence may give rise to a variety of clinical problems. Detection of supernumerary is best achieved through clinical and radiographic examination. This article shows the cases of supernumerary teeth in mandibular premolar region and maxillary third molar region along with its etiology, frequency, classification, complication, and management.

Keywords: Conical teeth, Panoramic X-ray, Premolar, Supernumerary teeth.

How to cite this article: Raina SA. Supernumerary Teeth in Premolar and Molar Regions and their Effect on Overall Restorative Treatment Plan. *Int J Prosthodont Restor Dent* 2016;6(4):98-101.

Source of support: Nil

Conflict of interest: None

INTRODUCTION

Supernumerary teeth are defined as those in addition to the normal series of deciduous or permanent dentition. They may occur anywhere in the mouth. They may appear as a single tooth or multiple teeth, unilaterally or bilaterally, erupted or impacted, and in the maxilla/mandible or both the jaws. The prevalence of supernumerary teeth varies between 0.1 and 3.8% and is more common in permanent dentition.¹⁻³ The low prevalence of supernumerary teeth in primary dentition is because it is generally overlooked by the parents, it is often of normal shape (supplement type), they erupt normally, and they appear to be in proper alignment.⁴ The incidence is considerably higher in the maxillary incisor region followed by maxillary third molar and mandibular molar,

premolar, canine, and lateral incisors.⁵ Though there is no significant sex distribution in primary supernumerary teeth, males are affected approximately twice than females in permanent dentition.^{6,7}

The etiology of supernumerary teeth is not completely understood. One theory suggests that the supernumerary tooth is created as a result of dichotomy of tooth bud.⁸ Another theory, well supported in literature, is the hyperactivity theory, which suggests that supernumeraries are found as a result of local, independent conditioned hyperactivity of dental lamina.^{8,9} Heredity may also play a role in the occurrence of this anomaly, as supernumerary are more common in the relatives of affected children than in the general population.

CASE REPORTS

Case 1

A 28-year-old female reported to the Department of Conservative Dentistry and Endodontics with the chief complaint of pain in the lower right first mandibular molar. On examination, deep proximal caries was seen with mandibular first molar. The tooth was tender on percussion. Hence, an intraoral periapical X-ray was advised to the patient. The X-ray showed deep carious lesion with first mandibular molar, along with an incompletely developed supernumerary located between roots of premolar and molars (Fig. 1). Root canal treatment was planned for mandibular first molar. After opening the pulp chamber, the pulp was extirpated, and diagnostic X-rays were taken. Irrigation was done with 5.25% sodium hypochlorite.

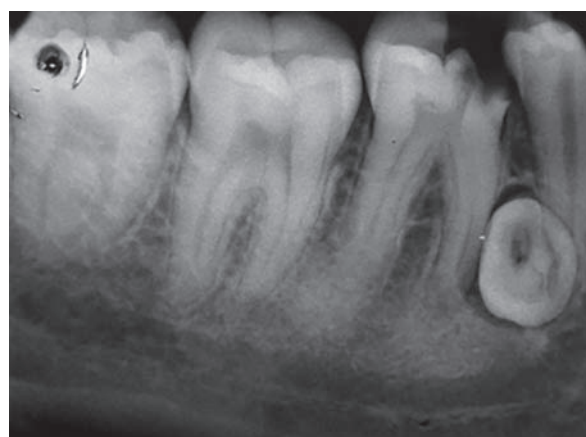

Fig. 1: X-ray of lower right first mandibular molar showing deep carious lesion along with incompletely developed supernumerary tooth

Assistant Professor

Department of Conservative Dentistry and Endodontics
Government Dental College & Hospital, Nagpur, Maharashtra
India

Corresponding Author: Sadhana A Raina, Assistant Professor
Department of Conservative Dentistry and Endodontics
Government Dental College & Hospital, Nagpur, Maharashtra
India, Phone: +91-9423685967, e-mail: drsadhanaraina@gmail.com

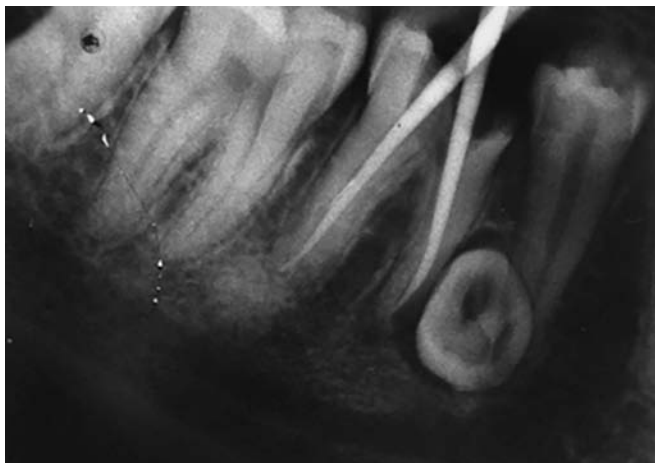


Fig. 2: X-ray showing the fit of gutta-percha point

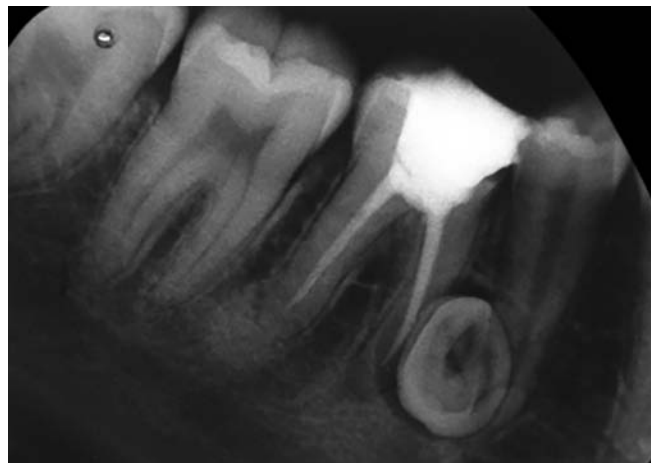


Fig. 3: X-ray showing root canal filling with lower right mandibular first molar

Protaper files were used for biomechanical preparation, and root canal filling was done with gutta-percha points (DiaDent, Korea) using AH Plus sealer (Dentsply, New York, USA) (Figs 2 and 3). The patient was told about the presence of supernumerary, but in this case, because of proximity of the bud to the apexes of adjacent teeth and mandibular nerve, it was believed that the potential hazards outweighed the benefits of the procedure. It was agreed to monitor the condition radiographically and intervene if patient has any discomfort or pain in future.

Case 2

A 26-year-old female reported to the Department of Conservative Dentistry and Endodontics with the chief complaint of pain in the left maxillary second molar. On examination, badly carious left maxillary second molar was seen. The oral hygiene of the patient with upper left maxillary region was very poor, as she had not been using that side since last 1 year. An intraoral periapical radiograph was taken, and X-rays revealed deep caries with

maxillary second molar along with supernumerary teeth with left maxillary third molar (Fig. 4). It was planned to remove maxillary second molar along with maxillary third molar and supernumerary tooth. However, patient refused to get her third molar removed along with the supernumerary as she had no problem. So, maxillary second molar was extracted and patient was asked to report every 6 months for the follow-up of maxillary third molar with supernumerary teeth for any complications (Fig. 5).

Case 3

A 25-year-old male patient reported with the chief complaint of difficulty in mastication because of too many teeth in his mouth. On examination, it was seen that there was an additional premolar in upper right and left quadrants and lower right and left quadrants. Since so many supernumerary premolars were seen in the patient, a panoramic X-ray was taken (Figs 6 to 9). It showed one more impacted premolar. Thus, a total of five additional premolars were seen in the patient.

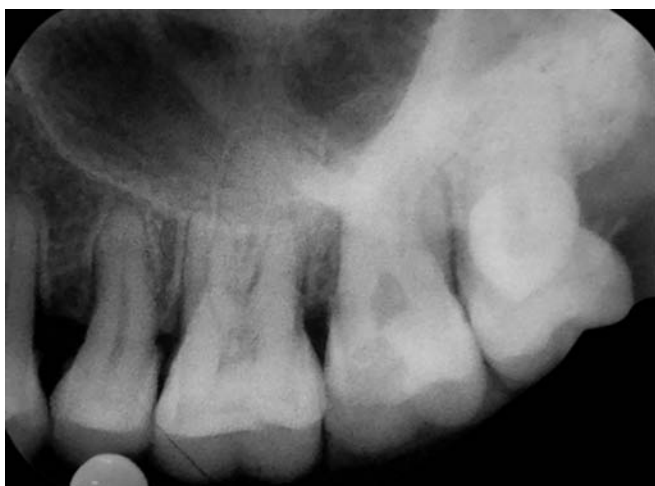

Fig. 4: X-ray of upper left maxillary second molar with supernumerary tooth

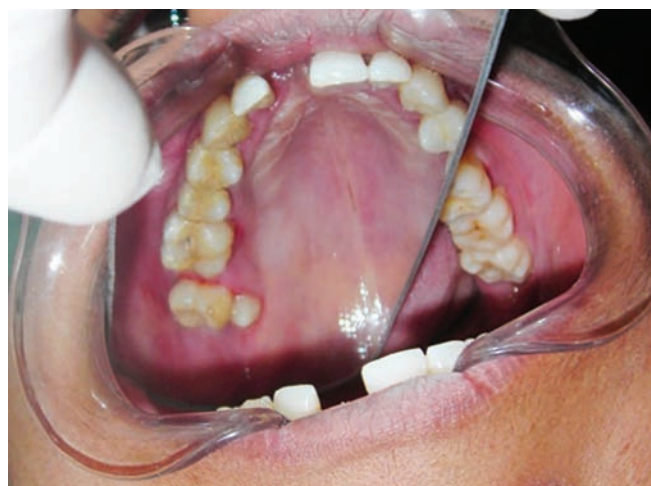

Fig. 5: Clinical picture of supernumerary tooth

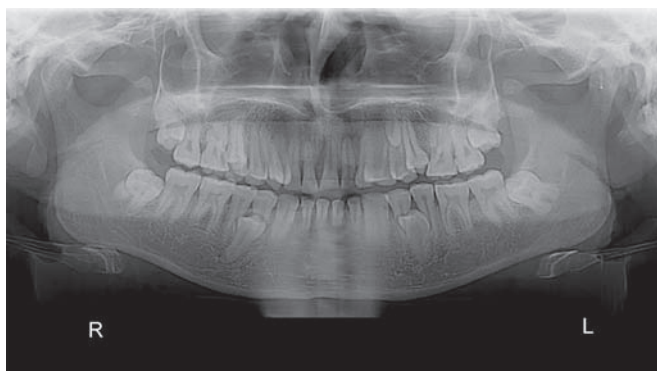

Fig. 6: Panoramic radiograph showing five supernumerary tooth

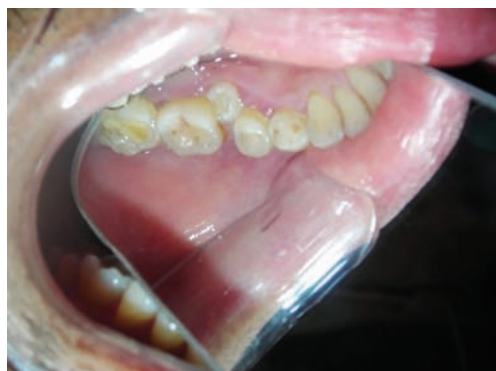

Fig. 7: Supernumerary tooth in lower right mandibular quadrant

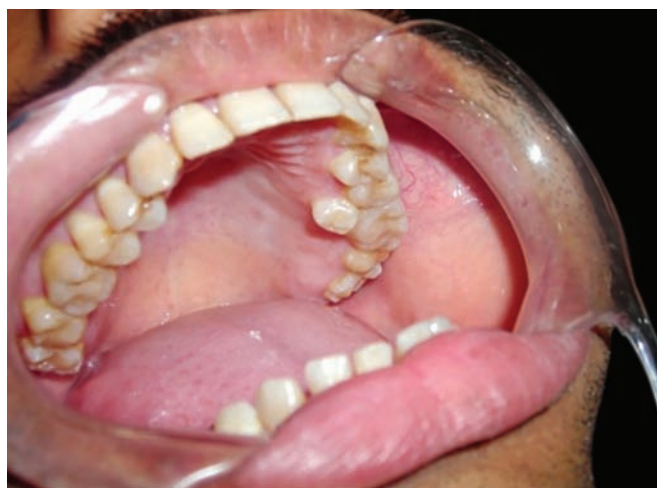

Fig. 8: Supernumerary tooth in upper left maxillary quadrant

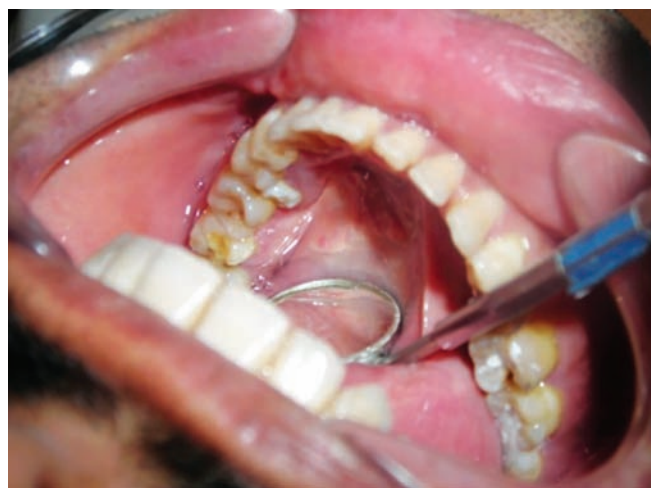

Fig. 9: Supernumerary tooth in lower left mandibular quadrant

DISCUSSION

The exact etiology of the supernumerary teeth has not been completely understood. Many theories are given to explain their presence. Some say it is because of abnormal division of tooth bud, but another theory says that it is because of hyperactivity of the lamina dura.¹⁰ Generally, multiple supernumerary teeth are associated with diseases or syndromes.³ Supernumerary teeth show strong association with developmental disorders like cleft lip and cleft palate, cleidocranial dysostosis, Gardner syndrome, and less commonly with Ehlers–Danlos syndrome and Anderson-Fabry syndrome.^{1,5}

Supernumerary teeth present themselves as mesoderm, conical, tuberculate, supplemental teeth or as an odontome. This can be complex composite odontome and compound composite odontome. As such, supernumerary teeth do not cause any complication. However, they may create some problems, such as the below:

- The presence of supernumerary teeth is one of the most common causes for the eruption of maxillary central incisor. Supernumerary teeth in other locations may cause failure of eruption of adjacent teeth.

- Its presence may cause displacement of permanent teeth. The degree of displacement may vary from mild rotation to complete displacement.
- Dentigerous cyst formation is another problem associated with supernumerary teeth. Resorption of roots adjacent to a supernumerary may occur, but it is rare.
- Erupted supernumerary most often causes crowding.
- Supernumerary teeth may compromise secondary alveolar bone grafting in patients with cleft lip and palate. Supernumeraries should not be extracted without consultation with cleft team.
- The presence of an unerupted supernumerary in a potential implant site may compromise implant placement.

Treatment management depends upon the location of the supernumerary teeth and its effect on the teeth. If it is asymptomatic and is not causing any problem, such as no displacement of teeth or hindrance in the eruption of teeth and no pathology involved, then the supernumerary tooth is not extracted. But, in conditions in which displacement of teeth is present, when eruption of teeth is delayed, or when major orthodontic alignment of the teeth is planned, the supernumerary tooth requires

extraction. Additionally, in cases of cleft lip and cleft palate where alveolar bone grafting is planned, and also in cases where supernumerary tooth comes in the way of implants, extraction is planned.

CONCLUSION

Supernumerary teeth can present itself in any region of the oral cavity. They may erupt or remain impacted and may lead to various complications. Though occurrence of premolar is rare, detailed history, clinical examination, thorough investigation, early diagnosis, and appropriate treatments of supernumerary teeth are mandatory, so that proper treatment plan can be executed.

REFERENCES

1. Yusof WZ. Non-syndrome multiple supernumerary teeth: literature review. *J Can Dent Assoc* 1990 Feb;56(2):147-149.
2. Rajab LD, Hamdan MA. Supernumerary teeth: review of the literature and a survey of 152 cases. *Int J Paediatr Dent* 2002 Jul;12(4):244-254.
3. Brook AH. Dental anomalies of number, form and size: their prevalence in British schoolchildren. *J Int Assoc Dent Child* 1974 Dec;5(2):37-53.
4. Scheiner MA, Sampson WJ. Supernumerary teeth: a review of the literature and four case reports. *Aust Dent J* 1997 Jun;42(3):160-165.
5. Grimanis GA, Kyriakides AT, Spyropoulos NA. A survey on supernumerary molars. *Quintessence Int* 1991 Dec;22(12):989-995.
6. Kinirons MJ. Unerupted premaxillary supernumerary teeth. A study of their occurrence in males and females. *Br Dent J* 1982 Aug;153(3):110.
7. Garvey MT, Barry HJ, Blake M. Supernumerary teeth – an overview of classification, diagnosis and management. *J Can Dent Assoc* 1999 Dec;65(11):612-616.
8. Lin JF. Characteristics of premaxillary supernumerary teeth: a survey of 112 cases. *ASCD J Dent Child* 1995 Jul-Aug;62(4):262-265.
9. Levine N. The clinical management of supernumerary teeth. *J Can Dent Assoc* 1961;28:297-303.
10. Primosch RE. Anterior supernumerary teeth – assessment and surgical intervention in children. *Pediatr Dent* 1981 Jun;3(2):204-215.