


CASE REPORT



Nonconventional Therapeutic Protocol for Type III Dens Invaginatus

¹Gustavo G Kunert, ²Itaborai R Kunert, ³José AP de Figueiredo, ⁴Fernando B Barletta, ⁵Carlos Estrela

ABSTRACT

Introduction: This study discusses a nonconventional therapeutic protocol for type III dens invaginatus. This condition is a disorder of dental development, caused by the invagination of enamel into coronal and/or radicular dentin structure. This promotes several structural alterations within the dental organ, which offers challenges and difficulties to perform the endodontic treatment when needed. This article reports a clinical case where a conservative approach was adopted to preserve the invaginated tooth, and endodontic treatment was performed in the main necrotic canal. Following 21 years of observation, a complete root formation could be seen, with dental pulp preservation of the pulpotomized tooth. Considering the reported difficulties for the treatment of dens invaginatus, conservative measures, such as pulpotomy to preserve the remaining dental pulp may be an excellent alternative to allow less invasive procedures, thus avoiding endodontic surgery. This study discusses a nonconventional therapeutic protocol for type III dens invaginatus. A conservative approach adopted preserved the invaginated tooth, and root canal treatment was performed in the main necrotic canal. Following 21 years of observation, there was complete root formation, with dental pulp preservation of the pulpotomized tooth.

Keywords: Case report, Dens invaginatus, Maxillary central incisor, Periapical lesion, Pulpotomy.

How to cite this article: Kunert GG, Kunert IR, de Figueiredo JAP, Barletta FB, Estrela C. Nonconventional Therapeutic Protocol for Type III Dens Invaginatus. *J Contemp Dent Pract* 2017;18(3):257-260.

Source of support: Nil

Conflict of interest: None

INTRODUCTION

Tooth development is sensitive to various anomalies during differentiation of various structures, such as the dental papilla. Genetic causes as well as local trauma and microbial ingress toward new dental tissues may collaborate to anatomical features that are difficult to deal when endodontic treatment may be of need.¹

Some deformities due to accidents during embryonic phase may lead to deep fissures with root depression and malformation of enamel with cusps with greater volume and dental invaginations (dens invaginatus), which form a tiny layer of enamel that allows bacterial deposition along its surface with limited access to hygienic measures.² This condition in the long term may lead to pulpal necrosis.

Root canal treatment is at times difficult to perform because of change in local anatomy not allowing proper cleaning and shaping of the whole endodontic structure. That may explain why it is not difficult to find case reports in the literature describing the procedure to overcome certain difficulties.

This anomaly occurs most frequently on the upper teeth, such as lateral and central incisors, premolars, canines, and molars, in descending order. The occurrence may be sole or bilateral, depending on the cause.¹

When clinical diagnosis is available, it displays a tooth with anomalous cusp, both in shape and in size, or a deep fissure. Central and lateral incisors often show the fissure in the cingulus palatally.³ According to Ohlers,⁴ invaginations can be classified as follows: Type I – small invagination, seen only on radiograph and affecting only the root cervical third; type II – a more severe condition, advancing toward the pulp chamber and reaching the root medium third; type III – the most severe invagination compromises the apical root third.

This case reports a type III dens invaginatus reaching the apical third and leading to the formation of two

¹⁻³Dental School, Unit of Endodontology, Pontifical Catholic University of Rio Grande do Sul (PUCRS), Porto Alegre, Rio Grande do Sul, Brazil

⁴Dental School, Unit of Endodontology, Lutheran University of Brazil (ULBRA), Canoas Rio Grande do Sul, Brazil

⁵Dental School, Unit of Endodontology, Federal University of Goiás, Goiânia, Goiás, Brazil

Corresponding Author: Fernando B Barletta, Dental School Unit of Endodontology, Lutheran University of Brazil (ULBRA) Canoas, Rio Grande do Sul, Brazil, e-mail: fbarletta@terra.com.br

distinct canals. Each root canal was treated differently; in one, traditional root canal preparation and filling was performed. The second canal was subjected to pulpotomy to preserve the dental pulp. Follow-up for 21 years is described.

CASE REPORT

A 12-year-old white male patient residing in a town 700 km from Porto Alegre, Brazil, visited the dental practice on August 10, 1994. Main complaint was the presence of sinus tract, which was noticed 1 month before, with continuous exudation.

Medical and dental history could not elucidate the cause of the sinus tract. During clinical examination, an unusual anatomical feature was observed, markedly in the palatal aspect of the crown, at the cingulum with slight deviation mesially. No discoloration, pit, or fissure could be found.

The periapical radiograph of the tooth showed the unusual configuration of type III dens invaginatus leading to two independent root canals. Both displayed incomplete root formation. It was surprising to note that tetrafluoroethane sensitivity test (-20°C , São Paulo, Brazil) at the buccal aspect was positive, even in the presence of fistula. A second pulp sensitivity test was performed at the cingulum, and it responded negatively. It was therefore concluded that the dental pulp of the main canal was vital and the one of the dens invaginatus was necrotic.

It was decided to perform the following protocol: Placement of rubber dam, access cavity, and disinfecting penetration of the dens invaginatus canal with 2.5% sodium hypochlorite (Asfer, São Paulo, Brazil). Length determination and canal preparation in a crown-down approach were performed. Ultrasonic (Adiel, São Paulo, Brazil) cleaning was used in adjunct with the preparation. Interim medication consisted of a paste containing pure calcium hydroxide (Biodinâmica, Paraná, Brazil) and glycerol (Biodinâmica, Paraná, Brazil). Lentulo spiral was used to help fill the canal provisionally with the paste. Restoration between visits was glass ionomer cement (Vidrion R, SS White, Rio de Janeiro, Brazil). Periapical radiograph allowed the visualization of the completion of the paste within the canal.

About 20 days later the patient returned and the sinus tract had disappeared. Calcium hydroxide paste was replaced. The renewal of this medication was repeated every 30 days. Three months following the first visit, with clinical normality, another sensitivity test was performed. However, there was a weak and inconclusive response at the buccal aspect of the crown.

It was decided to access the canal buccally, and live and consistent bleeding was noted. Pulpotomy was

the treatment of choice for this second canal, because of incomplete root formation. Topical corticosteroid (Otosporin, Farmoquímica, Rio de Janeiro, Brazil) was embedded in a cotton pellet and gently placed on the surface of the exposed pulp for 10 minutes. Thorough irrigation with saline was followed by drying and coverage of the pulp with pure calcium hydroxide powder. To help the calcium hydroxide sit in place, Dycal[®] (Dentsply, Rio de Janeiro, Brazil) was used followed by glass ionomer and composite restoration (Charisma, Heraeus Kulzer, São Paulo, Brazil).

About 16 visits with changes of calcium hydroxide paste allowed the apexification of the necrotic root. This was then filled with gutta-percha and zinc oxide and eugenol sealer (IRM, Dentsply, Rio de Janeiro, Brazil), using lateral condensation. Radiographic control of the pulpotomy 90 days after its procedure showed the formation of a dentin bridge. Pulp sensitivity test toward the bridge responded positively.

The sequence of events is summarized by the radiographies, displayed in a timely sequence (Figs 1A to C and 2A to C).

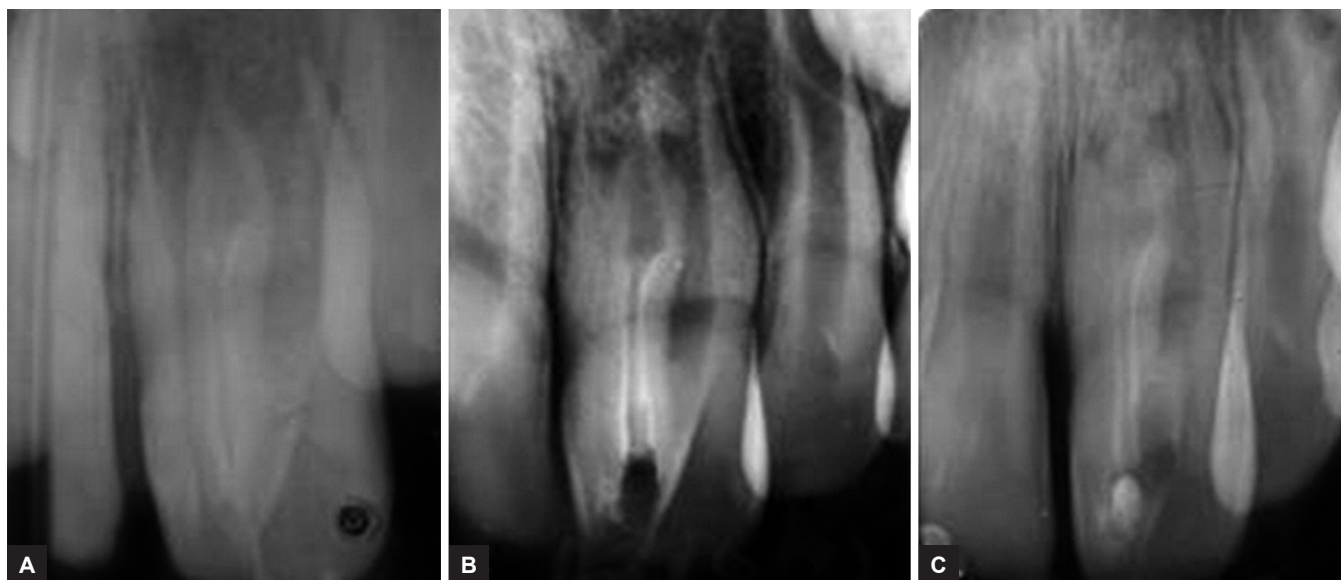
A total of 21 years following the first visit, the tooth remained asymptomatic, with complete root formation and normal behavior. Of note is the complete root formation, both in the necrotic pulp root and in the vital pulp root.

DISCUSSION

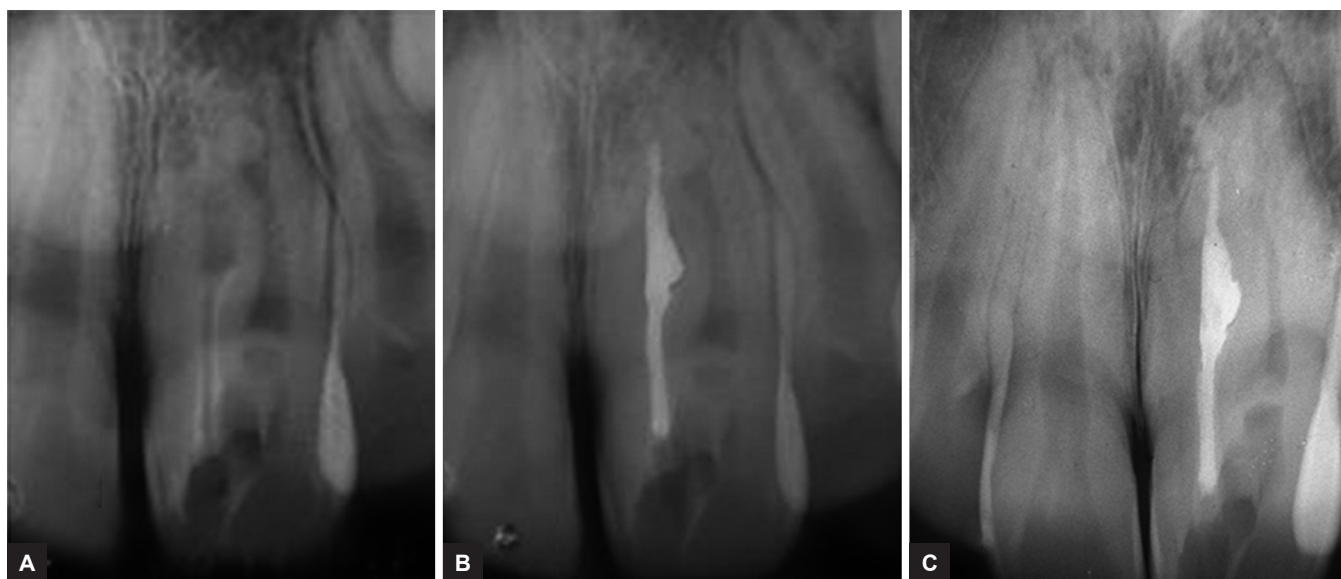Although dens invaginatus has low incidence in the population, varying from 0.04 to 10%,⁵ the challenge for the correct treatment allows complex decision-making processes.

Endodontic surgery may be needed to supplement traditional endodontic treatment in type II and III dens invaginatus.⁶ Type II cases have also been treated with conventional root canal treatment.⁷ The choice for a pulpotomy in root canals not affected by infection, as performed in this reported case, may reduce the risk and need of more complex procedures. Ferraz et al⁸ report the difficulties to treat talon cusp and dens invaginatus. It is often needed to do crown reduction with deep wear on enamel, dentin, and even pulp. Conservative procedures, such as pulpotomy, may avoid risky endodontic treatment which may lead to endodontic surgery afterward to seal the various apical ramifications. Pulpotomy may be the treatment of choice whenever the conditions are favorable.⁹

Calcium hydroxide was the interim medication following preparation procedures. It is the most used medication among available intracanal dressings in cases of apexigenesis, apexification, and dental pulp necrosis.¹⁰⁻¹³ The dissociation of calcium hydroxide into calcium and



Figs 1A to C: Operative sequence of conventional endodontic treatment of dens invaginatus and conservative treatment (pulpotomy) of main root canal. Initial procedures: (A) Initial radiograph; (B) calcium hydroxide medication; and (C) pulpotomy of main root



Figs 2A to C: Operative sequence of conventional endodontic treatment of dens invaginatus and conservative treatment (pulpotomy) of main root canal. Final procedures and follow-up: (A) Dentin bridge of main root and dens invaginatus medication; (B) dens invaginatus filling; and (C) 21 years follow-up

hydroxyl ions and the action of these ions on tissues and bacteria explain the biological and antimicrobial properties of this substance.^{12,13} The calcium hydroxide induces the deposition of a hard tissue bridge on pulpal and periodontal connective tissue.^{12,13} It was also used in contact with the remaining vital pulp, for pulpotomy procedure. Dentin bridge is consistently formed, and the remaining pulp is preserved.

The number of calcium hydroxide changes is a matter of debate. According to Felipe et al,¹⁴ calcium hydroxide should not be replaced to avoid jeopardizing root completion. Leonardo et al¹⁵ suggest the renewal to be performed every 60 days. For this case, the procedure of

replacement of calcium hydroxide was performed every 30 days. The reason was the anatomical feature which could facilitate solubility of the paste because of the large foraminal opening. Glass ionomer was chosen to provide stability during the replacement procedures.

da Silva Neto et al¹⁶ reported a type III dens invaginatus and pointed out as inevitable to do the endodontic treatment and surgical endodontics to supplement the seal. Yang et al¹⁷ present a case using regenerative technique to allow closure of the open apices. Kaya-Büyükbayram et al¹⁸ also recommend the regenerative technique for maintaining vitality, especially for the high difficulty of endodontic treatment in these cases.

Narayana et al¹⁹ suggest the use of clinical microscope and cone beam computed tomography to allow better outcome of this treatment, in agreement with the study of Ceyhanli et al⁵ and Vier-Pelisser et al.²⁰

However, the case we presented shows an alternative which may be of choice in future cases, when the dental pulp of one of the canals remains vital. This means that a simpler procedure maintains the radicular pulp with gain of dentin and prevention of further infection in an area of difficult access and preparation procedure. The satisfactory outcome of this case may allow the choice of a protocol with simple but effective procedure.

CONCLUSION

Considering the reported difficulties for the treatment of dens invaginatus, conservative measures, such as the pulpotomy to preserve the remaining dental pulp, may be an excellent alternative to allow less invasive procedures, thus avoiding endodontic surgery.

REFERENCES

- Alani A, Bishop K. Dens invaginatus. Part 1: classification, prevalence and aetiology. *Int Endod J* 2008 Dec;41(12):1123-1136.
- Gallacher A, Ali R, Bhakta S. Dens invaginatus: diagnosis and management strategies. *Br Dent J* 2016 Oct 7;221(7):383-387.
- Raut AW, Mantri V, Kala S, Raut RA. Management of "labial" type of dens invaginatus: a rare case report. *J Oral Biol Craniofac Res* 2016 Sep-Dec;6(3):253-256.
- Oehlers FA. Dens invaginatus (dilated composite odontome). I. Variations of the invagination process and associated anterior crown forms. *Oral Surg Oral Med Oral Pathol* 1957 Nov;10(11):1204-1218.
- Ceyhanli KT, Celik D, Altintas SH, Tasdemir T, S Sezgin O. Conservative treatment and follow-up of type III dens invaginatus using cone beam computed tomography. *J Oral Sci* 2014 Dec;56(4):307-310.
- Vier-Pelisser FV, Pelisser A, Recuero LC, Só MV, Borba MG, Figueiredo JA. Use of cone beam computed tomography in the diagnosis, planning and follow up of a type III dens invaginatus case. *Int Endod J* 2012 Feb;45(2):198-208.
- Liji MP, Chandrababu K, Kumar MR, Jayashree S. Type II canal configuration and type I dens invaginatus. *J Conserv Dent* 2014 Jul;17(4):382-384.
- Ferraz JA, de Carvalho Júnior JR, Saquy PC, Pécora JD, Sousa-Neto MD. Dental anomaly: dens evaginatus (talon cusp). *Braz Dent J* 2001;12(2):132-134.
- Mejère IA, Axelsson S, Davidson T, Frisk F, Hakeberg M, Kvist T, Norlund A, Petersson A, Portenier I, Sandberg H, et al. Diagnosis of the condition of the dental pulp: a systematic review. *Int Endod J* 2012 Jul;45(7):597-613.
- Holland R, de Souza V, Tagliavini RL, Milanezi LA. Healing process of teeth with open apices: histological study. *Bull Tokyo Dent Coll* 1971 Nov;12(4):333-338.
- Sousa Neto MD, Crisci FS, Saquy PC, Pecora JD. Treatment of teeth with incomplete root formation and a history of trauma. *Braz Endod J* 1996;1(1):49-51.
- Estrela C, Sydney GB, Bammann LL, Felipe Júnior O. Mechanism of action of calcium and hydroxyl ions of calcium hydroxide on tissue and bacteria. *Braz Dent J* 1995;6(2):85-90.
- Estrela C, Holland R, Estrela CR, Alencar AH, Sousa-Neto MD, Pécora JD. Characterization of successful root canal treatment. *Braz Dent J* 2014 Jan-Feb;25(1):3-11.
- Felippe MC, Felipe WT, Marques MM, Antoniazzi JH. The effect of the renewal of calcium hydroxide paste on the apexification and periapical healing of teeth with incomplete root formation. *Int Endod J* 2005 Jul;38(7):436-442.
- Leonardo MR, Bezerra da Silva LA, Utrilla LS, Leonardo Rde T, Consolaro A. Effect of intracanal dressings on repair and apical bridging of teeth with incomplete root formation. *Endod Dent Traumatol* 1993 Feb;9(1):25-30.
- da Silva Neto UX, Hirai VH, Papalexiou V, Gonçalves SB, Westphalen VP, Bramante CM, Martins WD. Combined endodontic therapy and surgery in the treatment of dens invaginatus type 3: case report. *J Can Dent Assoc* 2005 Dec;71(11):855-858.
- Yang J, Zhao Y, Qin M, Ge L. Pulp revascularization of immature dens invaginatus with periapical periodontitis. *J Endod* 2013 Feb;39(2):288-292.
- Kaya-Büyükbayram I, Özalp Ş, Aytugur E, Aydemir S. Regenerative endodontic treatment of an infected immature dens invaginatus with the aid of cone-beam computed tomography. *Case Rep Dent* 2014;2014:403045.
- Narayana P, Hartwell GR, Wallace R, Nair UP. Endodontic clinical management of a dens invaginatus case by using a unique treatment approach: a case report. *J Endod* 2012 Aug;38(8):1145-1148.
- Vier-Pelisser FV, Morgental RD, Fritscher G, Ghisi AC, Borba MG, Scarparo RK. Management of type III dens invaginatus in a mandibular premolar: a case report. *Braz Dent J* 2014 Jan-Feb;25(1):73-78.