

CASE REPORT

Tongue: An Unusual Site of Abscess Development

¹PK Dubey, ²A Chaudhary, ³MK Pandey, ⁴M Chaudhary, ⁵P Gupta, ⁶A Kumar

ABSTRACT

Despite continuous exposure to trauma, bites, and enormous number of potential pathogens, tongue is relatively resistant to infection. Abscess of tongue although is an extremely rare, but a life-threatening medical condition with little information of its diagnosis and management. Here, we present two cases of tongue abscess in young females, with their clinical presentation, differential diagnoses, and management in detail. This is a first report where tongue abscess is reported in two very young (10 years and less) patients, unlike previous few reports where this entity has been described in adults or old-aged patients. As discussed in both the cases in this report, patients responded remarkably well, without any recurrence.

Keywords: Lingual abscess, Oral cavity infection, Rare diseases, Tongue abscess.

How to cite this article: Dubey PK, Chaudhary A, Pandey MK, Chaudhary M, Gupta P, Kumar A. Tongue: An Unusual Site of Abscess Development. *Int J Prev Clin Dent Res* 2016;3(4): 306-309.

Source of support: Nil

Conflict of interest: None

INTRODUCTION

Acute infection of the tongue is rather rare in spite of the oral cavity full of innumerable sources of infection, and as a result only handful of cases of tongue abscess is reported worldwide.¹ However, this rare clinical entity can be potentially life threatening by compromising airway and disseminating infection to other regions. Lingual abscesses frequently present as painful swelling, dysphagia, odynophagia, and difficulty in speech.² In most

of the reported cases, no specific cause is identified. Some studies suggest that a lost fish bone may be the cause in many cases. Further, some recent reports also revealed the association between tongue abscess and body piercing. The data from epidemiological studies indicate that abscess of tongue is more associated to smoking, use of dental prostheses, and poor oral hygiene. Tongue infection establishes when the mechanical barrier of tongue mucosa, i.e., first line of defense, is breached and the host immune system is compromised.³ Clinical examination, ultrasonography (USG)/computed tomography (CT), and/or needle aspiration of pus collection should establish the diagnosis. Conservative treatment with antibiotics are given at first and if therapy fails or any deteriorating sign appears, immediate surgical incision and drainage is performed to avoid any emergency.⁴

CASE REPORTS

Case 1

A female of 10 years old was presented with complaints of swelling on the right side of tongue and pain during chewing of food items since 2 weeks. Moderate to high grade fever started a week before the patient came to clinic. There was no history of trauma to the tongue and intake of steroid or any immunosuppressive drugs. The physical examination of oral cavity showed, 2.5 × 2 cm size soft tissue swelling, which was tense, tender, and palpable on right side of the tongue dorsum in the anterior two-third region (Fig. 1A).

^{1,2,6}Reader, ³Assistant Professor, ⁴Senior Lecturer

⁵Senior Research Fellow

^{1,2}Department of Prosthodontics, Narsinhbhai Patel Dental College & Hospital, Sankalchand Patel University, Visnagar Gujarat, India

³Department of Neurosurgery, Dr. Susheela Tiwari Government Hospital, Haldwani, Uttarakhand, India

⁴Department of Oral Pathology, Surendera Dental College and Research Institute, Sri Ganganagar, Rajasthan, India

⁵Department of Pathology, All India Institute of Medical Sciences New Delhi, India

⁶Department of Public Health Dentistry, Sarjug Dental College and Hospital, Darbhanga, Bihar, India

Corresponding Author: A Chaudhary, Reader, Department of Prosthodontics, Narsinhbhai Patel Dental College & Hospital Sankalchand Patel University, Visnagar, Gujarat, India, Phone: +91-9694959495, e-mail: akashat.chaudhary@gmail.com

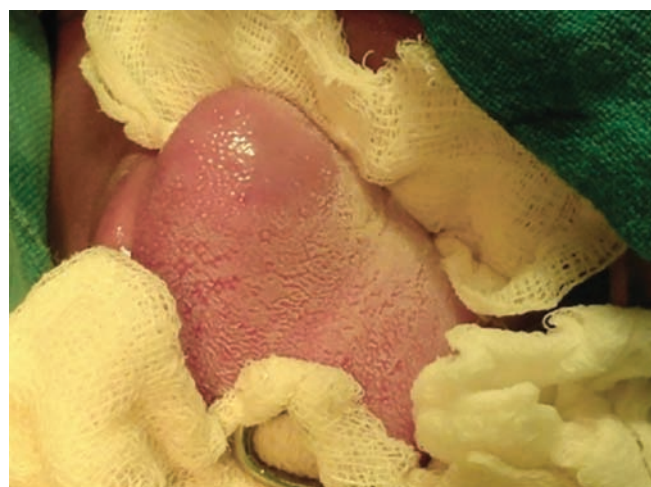

Fig. 1A: Preoperative photograph showing tongue abscess right dorsum anteriorly

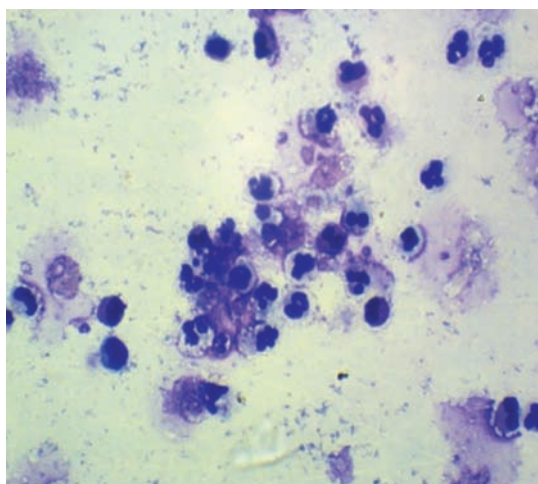


Fig. 1B: Fine needle aspiration cytology of tongue swelling

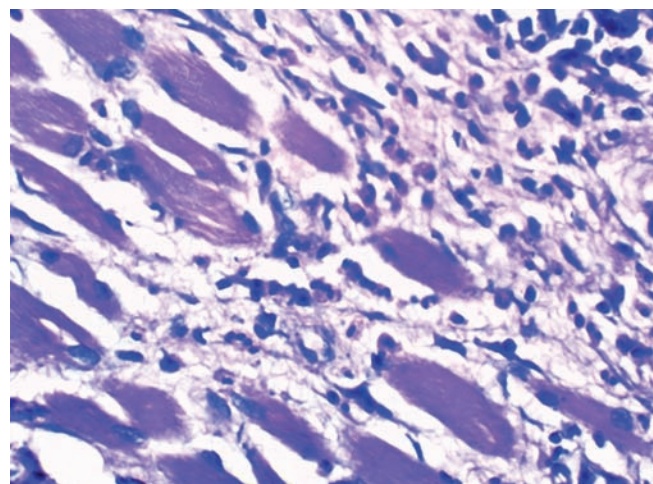


Fig. 1C: Histopathological examination showed nonspecific chronic inflammatory granulation tissue between the tongue muscle fascicles

The submandibular lymph nodes were palpable on the right side. The systemic examination was unremarkable. The laboratory investigations revealed her Hb 13.5 gm/dL, white blood cell (WBC) count 13,500 cells/mm³, erythrocyte sedimentation rate (ESR) 25 mm/hr, and blood sugar 88 mg/dL. Human immunodeficiency virus (HIV) was nonreactive. Ultrasonography of tongue showed hypoechoic mass lesion on right side dorsum of the tongue in the anterior two-third regions. Ultrasonography guided needle aspiration was done and sent for cellular smear study and culture sensitivity. Smear shows rich cellularity comprising fair number of polymorphs, few lymphocytes, and macrophages (Fig. 1B).

The case was diagnosed as tongue abscess. The patient was administered with broad spectrum intravenous antibiotics ceftriaxone, amikacin, clindamycin, and analgesics. The aspirate culture showed group II streptococcus, sensitive to amoxicillin, and amikacin. The antibiotics were changed after culture report. Although fever was improved, the swelling and pain could not respond to conservative therapy. As a result, incision and drainage with curettage was done. The histopathological examination of curettage material showed nonspecific chronic inflammatory granulation (Fig. 1C).

In postoperative period, the patient was kept on intravenous antibiotics amoxicillin, amikacin, and clindamycin for 1 week and then kept on oral antibiotics for 3 weeks. The patient was followed up for 1 year and no recurrence was reported.

Case 2

A female of 8 years age was presented with complaints of painless swelling on the right side anterior part of tongue, for last 1 month. No history of fever, trauma to the tongue, swallowing and chewing difficulty, and any intake of steroid or immune-suppressive drugs was reported. The

physical examination of oral cavity showed a non tender, soft, cystic swelling of size 2 × 1.5 cm, palpable on the right side of the tongue at anterior two-thirds regions. The overlying mucosa was normal in color (Fig. 2A).

There was no regional lymphadenopathy. The systemic examination was unremarkable. The hematological investigation revealed the WBC count 11,500/mm³, ESR 20 mm/hr, and blood sugar 97 mg/dL. Human immunodeficiency virus was nonreactive.

The USG of tongue suggested a well defined hypoechoic mass lesion measuring 15.1 × 11.1 mm with surrounding edema seen in muscular plane on right lateral part of the dorsal surface (Fig. 2B) on color flow imaging, no abnormal vascularity seen in mass lesion. Ultrasonography guided needle aspiration was done which showed pus material, and cellular smear study showed the inflammatory cells. Pus culture was positive *Staphylococcus aureus* and anaerobes, sensitive to piperacillin, tazobactam, and linezolid. The patient was managed conservatively with intravenous

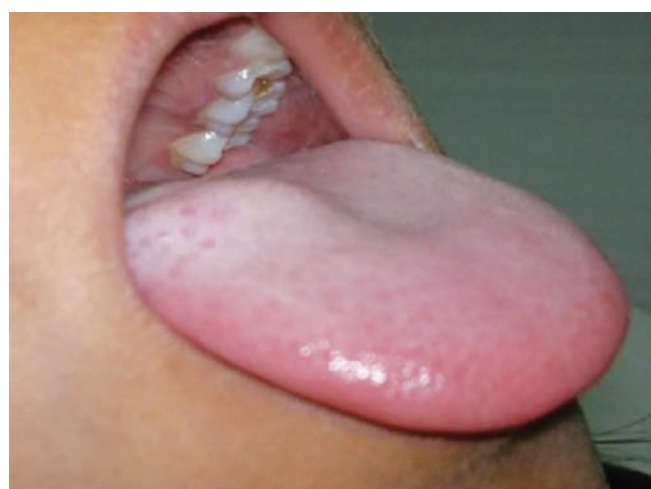

Fig. 2A: Photograph showing tongue abscess right side anterior two-third region

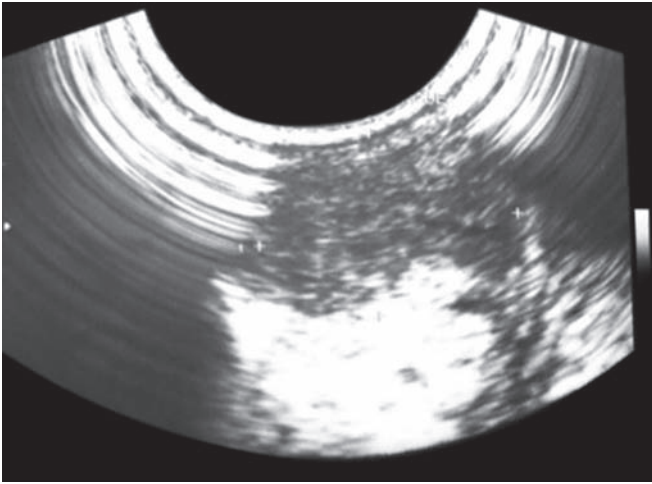


Fig. 2B: Ultrasonography of tongue showing hypoechoic mass lesion with surrounding edema

piperacillin and clindamycin for 1 week along with anti-inflammatory then oral linezolid for 2 weeks. Antiseptic gargle was encouraged for regular use. The swelling was subsided in 3 weeks. Patient was followed up for 1 year with no evidence of recurrence.

DISCUSSION

Although the tongue is constantly subjected to trauma, the inflammatory conditions of the tongue resulting from acute trauma are rare. Some of the reasons for this immunity include the constant mobility of the tongue, which helps the saliva produce a perpetual cleansing effect; its thick covering of keratinized mucosa, which is not easily penetrated by microorganisms; the muscle tissue, which constitutes the chief bulk of its parenchyma, with its rich vascular supply, its rich lymphatic drainage; and the immunologic properties of saliva.^{6,7} Quite often no specific cause can be identified.⁹ The etiology of a tongue abscess may differ depending on its location. The anterior two-thirds of the tongue commonly known as "oral tongue" is freely moving part that lies anterior to the circumvallate papillae. Posterior to the circumvallate papillae is the "tongue base" and is regarded as a part of the oropharynx.¹⁰ Glossal abscess is more frequently found on anterior portion of the tongue and is usually unilateral, being related to direct trauma⁵ but as in our case, there is no history of trauma. In the posterior third of the tongue, the abscess most often originates as lingual tonsillar infection, infected thyroglossal duct cysts, or extensions of apical or periodontal infection from lower molars.^{7,11} Abscesses located in the mobile tongue are easy to diagnose on the basis of the physical findings. However, those situated in the base of tongue may pose a diagnostic challenge¹² because the symptoms are less specific and other inflammatory processes, such as peritonsillitis or infection of the floor of the mouth, may be indistinguishable.¹³

The diagnosis must be done by the clinical history, correlating the risks factors associated with smoking, poor oral hygiene, use of dental prostheses and sex, physical examination of the oral cavity, and frequently in confirming image examinations.¹⁴ The symptoms of acute tongue abscess are swelling or a lump in the deep tissue of the tongue, pain radiating toward the ears, throbbing local pain, fever, difficulty in swallowing, voluntary fixation of the tongue because of pain, and, later, difficulty in breathing. Although with the help of these findings, the diagnosis of glossal abscess can be reached clinically, sometimes no specific sign or symptom is present, making diagnosis difficult.^{6,13} As in our second case history only swelling of tongue present; patient was consulted to hospital due to fear of tumor. The differential diagnosis from the anterior lesions of the tongue includes lingual artery false aneurysm, tuberculosis, syphilis, neoplasms, and actinomycosis.^{4,15,16} Oral tubercular lesions should particularly be considered in the differential diagnosis of tongue abscess, as the tongue being the most common site for oral involvement by tuberculosis.⁵ The lesions from the posterior third must include thyroglossal cyst and lingual tonsil abscess.⁴ Infarctions, edema, macroglossia due to hypopituitarism, metabolic alterations as deficiency of vitamin B₁₂, hypothyroidism, amyloidosis, acromegaly, iron deficiency, also must be considered as differential diagnosis.³

Several imaging techniques, including sonography, CT, and MR imaging, can be used to evaluate the tongue swellings.^{6,7,13} The USG defines and differentiates cystic structures, vascularized and abscesses, but in the tongue, there is a difficulty for the use of the transducer.¹⁴ Sonographic depiction of a lingual abscess as a hypoechoic lesion surrounded by a hyperechoic ring has been reported, but sonography is not always feasible because when the tongue is swollen, the patient may experience discomfort or acute pain if it is pressed.^{6,7}

The CT allows definition and anatomical relation of the lesion mostly in the posterior third of the tongue.¹⁴ Needle aspiration of pus collection was a useful diagnostic and therapeutic tool, which provides considerable amelioration of symptoms.¹³ The same technique was used in our patients also. The diagnosis in our case was basically clinical, but imaging and further smears analysis, culture, histopathology confirmed the diagnosis.

Antiseptic mouth washes are indicated until a focus of liquefaction is discernible. Incision on the lateral aspect of the tongue was given in our first case. That was practiced and preferable owing to the muscular structure, this permits a more rapid agglutination of the surfaces after the packing is removed; and, if any complication, such as hemorrhage, arises, it can more easily be controlled

by suture.¹⁷ The antibiotic therapy used in our case gives adequate coverage for the microorganisms more commonly responsible for the abscess of the tongue. They compose a mixed flora and are frequently present in the superior airway and in the flora of the oral cavity.¹⁴ The most common are the *Streptococcus viridans*, *Haemophilus influenzae*, *Staphylococcus aureus*, *Bacteroides*, *Neisseria*, and others.^{6-8,15} Drainage for guided puncture by USG, being this a less invasive procedure, with lower risks of bleedings also effective in the drainage of the abscess.¹⁵ The good prognosis and the none recurrence of the abscess in cases where are performed abscess drainage (surgical or by puncture) is due to the factors of protection presented by the tongue like the bactericidal action of saliva, its rich vascularization and the musculature that when contracting limits the inflammation and the cavity formed by the abscess.¹⁵ In addition to the general septicemic character of the complication, local dangerous phenomena, which render the prognosis rather bad, should always be borne in mind. Impending suffocation due to the extreme swelling, rupture of the abscess with the opening of a vein and resulting hemorrhage, spread of the infection into the submental connective tissue with a consequent Ludwig's angina, extension to the peritonsillar or postpharyngeal region, pulmonary or mediastinal structures are ominous possibilities.¹⁷ And, as a results, clinicians usually lacks experience in the diagnosis and therapy of this entity.

Tongue abscess should be considered in all cases of acute swelling in the tongue, especially, when host defenses are severely compromised.⁵

CONCLUSION

Abscesses of the tongue call for prompt clinical diagnosis and aggressive management because they are potentially life-threatening infections. Ultrasonography is very much useful and a cheaper investigation, helpful both in diagnosis and guided aspiration. Antimicrobial therapy is the cornerstone of treatment, and prompt incision and drainage as indicated. Patient was encouraged for good oral hygiene and also searches for any immunocompromised state.

KEY MESSAGES

- Early clinical diagnoses of tongue abscess make good result.

- Search the immune compromised state when diagnose the tongue abscess.
- Needs immediate surgical drainage when conservative therapy failed or any deteriorating sign noticed.
- Selection of antibiotics and good oral hygiene make treatment successful.
- Prevention by improving the immunity with healthy nutrition and good oral hygiene.

REFERENCES

1. Knight LC. Lingual abscess: a rarity. Br J Clin Pract 1991 Winter;45(4):294-295.
2. Combier and Murad: Presse Med., Sept 13, 1922.
3. Antoniadis K, Hadjipetrou L, Antoniadis V, et al. Acute tongue abscess. Report of three cases. Oral Surg Oral Med Oral Pathol Oral Radiol Endod 2004 May;97(5):570-573.
4. Hehar SS, Johnson IJ, Jones NS. Glossal abscess presenting as unilateral tongue swelling. J Laryngol Otol 1996 Apr;110(4):389-390.
5. Byahatti SM, Ingafou MSH. Lingual abscess—a rarity. J Clin Exp Dent 2011;3(2):e162-e165.
6. Ozturk M, Durak AC, Ozcan N, et al. Abscess of the tongue: findings on MR imaging. AJR Am J Roentgenol 1998 Mar;170(3):797-798.
7. Munoz A, Ballesteros AI, Brandariz Castelo JA. Primary lingual abscess presenting as acute swelling of the tongue obstructing the upper airway: diagnosis with MR. AJNR Am J Neuroradio 1998 Mar;19(3):496-498.
8. Sands M, Pepe J, Brown RB. Tongue abscess: case report and review. Clin Infect Dis 1993 Jan;16(1):133-135.
9. Balatsouras DG, Eliopoulos PN, Kaberos AC. Lingual abscess: diagnosis and treatment. Head Neck 2004 Jan;26(6):550-554.
10. Ozturk M, Yorulmaz I, Guney E, et al. Masses of the tongue and floor of the mouth: findings on magnetic resonance imaging. Eur Radiol 2000;10(10):1669-1674.
11. Brook I. Recovery of anaerobic bacteria from a glossal abscess in an adolescent. Pediatr Emerg Care 2002 Oct;18(5):358-359.
12. Ho J, Bush SP. Clinical pearls: painful tongue swelling. Acad Emerg Med 2000 Aug;7(8):918,941-943.
13. Reneham A, Morton M. Acute enlargement of the tongue. Br J Oral Maxillofac Surg 1993 Oct;31(5):321-324.
14. Thiago Bittencourt Ottoni de Carvalho, Atílio Maximino Fernandes, Raphael Angelo Sanches. Tongue Abscess: Case Report. Intl Arch Otorhinolaryngol 2012;16:126-129.
15. Kim HJ, Lee BJ, Kim SJ, Shim WY, Baik SK, Sunwoo M. Tongue abscess mimicking neoplasia. AJNR Am J Neuroradiol 2006 Nov-Dec;27(10):2202-2203.
16. Zamarro MTL, Pérez ML, Soriano J AM, Sanz GM. Actinomicosis de base de lengua. Acta Otorrinolaringol Esp 2005;56(5):222-225.
17. Wilensky AO, Harkavy J. Abscess of the tongue. Ann Surg 1923 Oct;78(4):496-500.