

## CASE REPORT

# Self-progressing Granulomatous Growth in Pediatric Patients: Pyogenic Granuloma?

<sup>1</sup>Unnati Pitale, <sup>2</sup>Ami Kandya, <sup>3</sup>Manish Varma, <sup>4</sup>Hitesh Mankad, <sup>5</sup>Vinaya K Kulkarni, <sup>6</sup>Rohit Pandey

## ABSTRACT

Fibrous overgrowths of soft tissues in oral cavity are relatively common and may be quite challenging to diagnose. Pyogenic granuloma is one such entity which occurs commonly in response to chronic local irritation, e.g., calculus, fractured tooth or restoration, foreign materials, etc. It occurs predominantly in females, probably due to the action of female hormones. These lesions are generally asymptomatic and are reported only due to difficulty in mastication. Treatment includes complete excision of the lesion along with the removal of causative factor. This paper describes a case of pyogenic granuloma in a ten-and-a-half-year-old girl, presenting with a single, irregular, reddish maxillary gingival swelling in relation to mobile 63.

**Keywords:** Exophytic growth, Fibrous overgrowth, Pyogenic granuloma.

**How to cite this article:** Pitale U, Kandya A, Varma M, Mankad H, Kulkarni VK, Pandey R. Self-progressing Granulomatous Growth in Pediatric Patients: Pyogenic Granuloma? *Int J Prev Clin Dent Res* 2016;3(4):299-302.

**Source of support:** Nil

**Conflict of interest:** None

## INTRODUCTION

Diagnosis of any exophytic growth in oral cavity is one of the challenges in dentistry, because a diverse group of pathologies can produce such lesions. It may be due to many causes, such as any developmental anomaly, inflammation, cysts, hyperplasia, neoplasm,<sup>1</sup> due to reaction to some drugs, like retinoic acid, oral contraceptives, indinavir, etc.<sup>2,3</sup> Hyperplasia may also be caused in response to any chronic, recurring tissue injury or any local irritation, insect bite or imbalance in hormonal levels.<sup>1</sup>

Pyogenic granuloma is one of the most common exophytic growths in the oral cavity.<sup>4</sup> However, the term “pyogenic granuloma” is a misnomer.<sup>5</sup> Based on the histological considerations, it is a lobular capillary hemangioma<sup>6</sup> or focal fibrous hyperplasia.<sup>7</sup> It is a painless, hyperplastic mass of soft tissue which may be pedunculated or sessile, red or purple in color.<sup>7</sup> It may be painful sometimes, in case the growth is constantly exposed to mastication. In around one-third of the cases, lesions are caused by any kind of trauma, and poor oral hygiene may be one of the precipitating factor.<sup>8</sup>

In oral cavity, pyogenic granuloma most commonly occurs on gingiva (on maxillary buccal surface). This disorder can be seen at any age but young adults are more commonly affected, females being more prone than males.<sup>9</sup> The treatment can be done conservatively by excision of lesion and maintenance of oral hygiene.

## CASE REPORT

A ten-and-a-half-year-old female patient reported with a complaint of pain and swelling on upper front tooth region since one-and-a-half month. The growth initially was rice sized, which progressed slowly and attained the present size, gradually causing difficulty in mastication. This was her first dental visit. Medical and family histories were noncontributory; however, she had a history of facial burn in childhood.

Extraorally, strictures could be seen on lower half of her face due to burn injury, which led to restricted mouth opening. No facial asymmetry was found. Submandibular or sublingual lymph nodes were nontender. Intraoral examination disclosed a bluish red pedunculated growth on buccal maxillary gingiva, which was approximately 2.5 × 1.5 cm in size. The growth extended from mesial surface of 63 to the middle surface of 65 anteroposteriorly (Fig. 1A) and buccopalatally extending from occlusal surface of 63, covering its crown up to palatal aspect (Fig. 1B). The indentations of mandibular teeth could be seen on occlusal surface of the growth. On palpation, the gingival growth was soft in consistency, nontender, and was bleeding on probing. Grade III mobility was seen with respect to 63. Patient had poor oral hygiene with large amount of calculus and deposits (which may be due to inability to open the mouth properly). Orthopantomogram examination revealed ectopically erupting 24 beneath the growth.

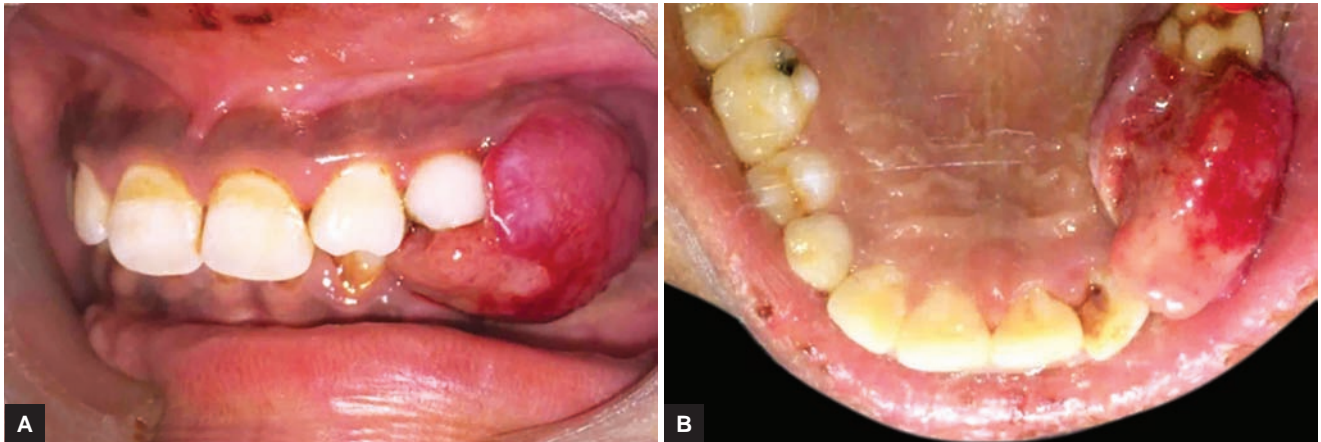
<sup>1,5</sup>Professor and Head, <sup>2-4,6</sup>Postgraduate Student

<sup>1,3,4,6</sup>Department of Periodontics, Modern Dental College and Research Centre, Indore, Madhya Pradesh, India

<sup>2</sup>Department of Pedodontics and Preventive Dentistry, Modern Dental College and Research Centre, Indore, Madhya Pradesh India

<sup>5</sup>Department of Pedodontics and Preventive Dentistry, SMBT Dental College, Sangamner, Maharashtra, India

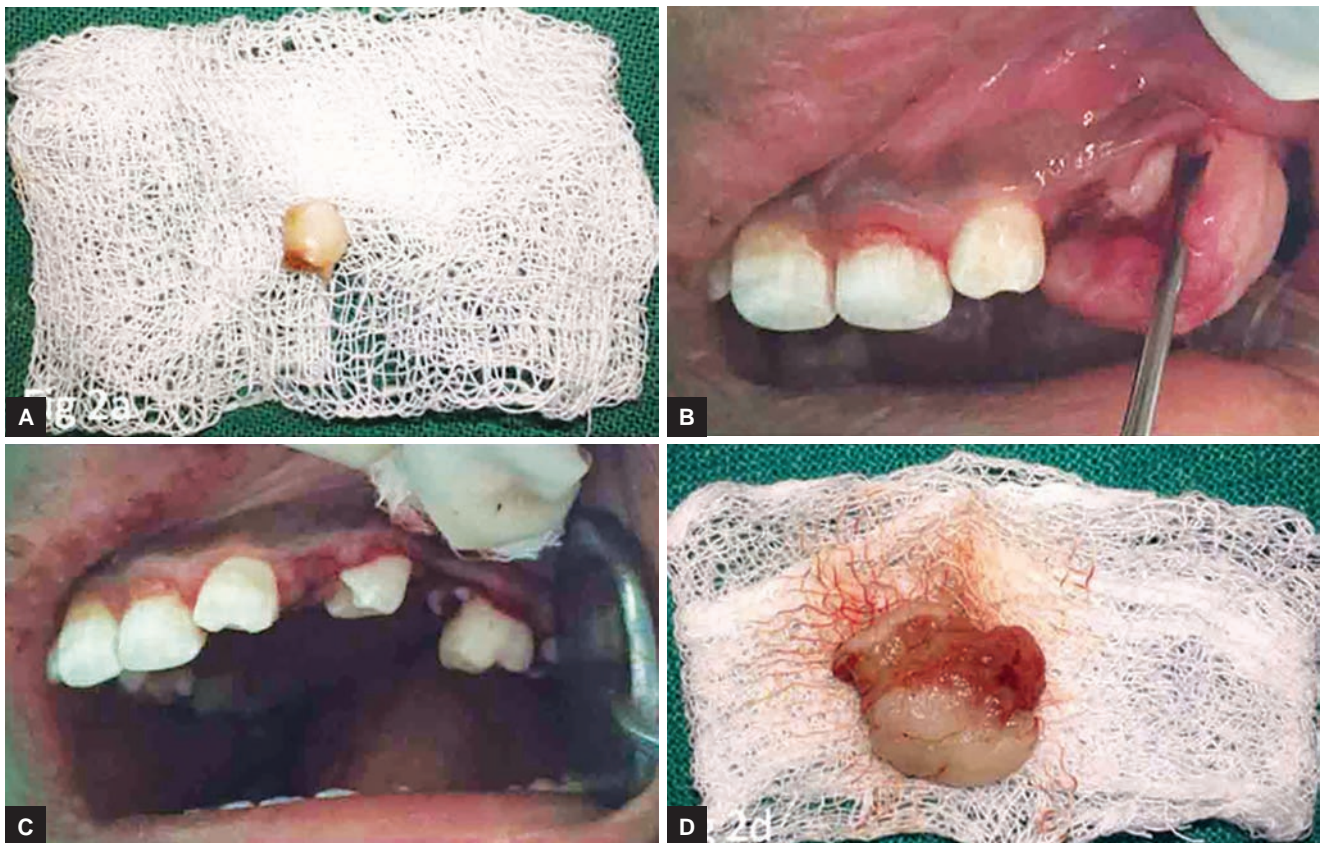
**Corresponding Author:** Manish Varma, Postgraduate Student Department of Periodontics, Modern Dental College and Research Centre, Indore, Madhya Pradesh, India, e-mail: idamanish@yahoo.co.in



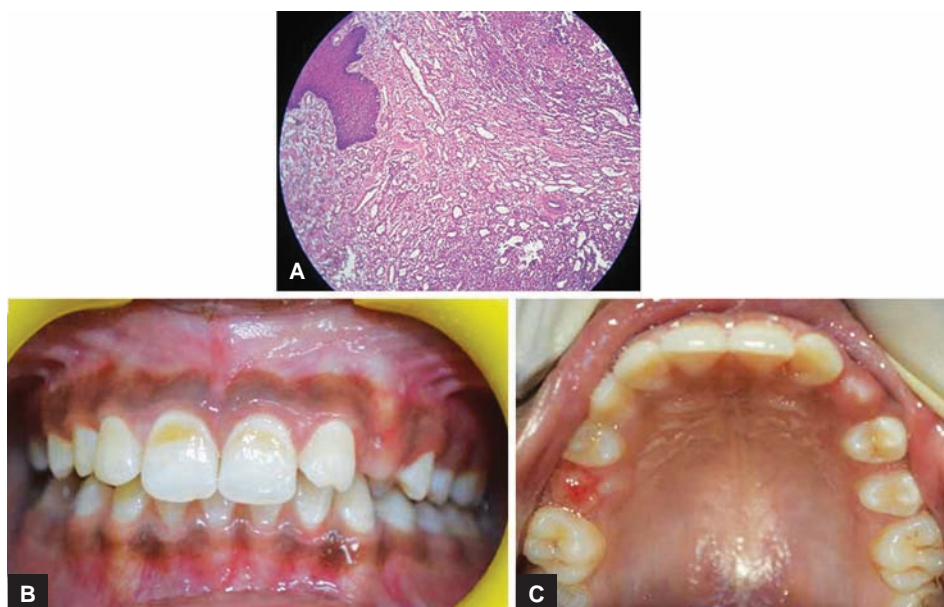**Figs 1A and B:** Preoperative pictures: (A and B) Intraoral images showing gingival overgrowth in the left maxillary region covering occlusal surface of 63 up to mesial surface of 65

Differential diagnoses of pyogenic granuloma, traumatic fibroma, and peripheral giant cell granuloma were made. Treatment planned was extraction of 63, followed by surgical excision of the gingival overgrowth. The hemogram of the patient was found to be within the normal limits, so, full mouth scaling was performed, which was followed by atraumatic extraction of 63 (Fig. 2A). The patient was advised to maintain proper oral hygiene and was recalled after 2 days. On recall, uneventful healing of the extraction socket was seen, and it was further decided to surgically excise the lesion (Fig. 2B).

After achieving proper anesthesia locally, the gingival overgrowth was excised under aseptic conditions. Excision was done with the help of a B.P blade number 15 up to the base of the lesion (Fig. 2C). Adjacent soft tissue remnants were also excised for the assurance of complete excision of the lesion. Tooth 65 was sacrificed in the procedure. A periodontal dressing was done to prevent trauma to the surgical site and enhance healing process. Antibiotics and analgesics were prescribed for 5 days. The excised soft tissue (Fig. 2D) was readily sent for histopathological examination.



**Figs 2A to D:** Operative pictures: (A) extracted tooth (63); (B) incision given at the base of the hyperplastic growth showing involvement of permanent tooth; (C) complete excision of the hyperplastic tissue; and (D) removed pathological mass



**Figs 3A to C:** Postoperative pictures: (A) Histopathological picture of the excised tissue; (B) and (C) 6 months postoperative image showing normal gingiva erupting permanent teeth

Microscopic evaluation (Fig. 3A) showed parakeratinized stratified squamous epithelium of variable thickness. Underlying connective tissue showed dense diffuse chronic inflammatory cell infiltration, the connective tissue stroma was edematous, moderately dense fibrocellular, and excessively vascular, which lead to confirmatory diagnosis of pyogenic granuloma. Postexcision period (Figs 3B and C) was uneventful with no evidence of recurrence.

## DISCUSSION

Pyogenic granuloma of oral cavity is a commonly occurring lesion which was at first described by Angelopoulos in 1897.<sup>10</sup> It was then called as *Botryomycosis hominis*.<sup>10</sup> The term "pyogenic granuloma" was coined by Hartzell in 1904.<sup>11</sup> However, it has also been referred to as "granuloma pediculatum benignum," "benign vascular tumor," "vascular epulis," etc.<sup>10</sup>

The term pyogenic granuloma does not accurately express the histopathological picture as it is neither associated with pus nor is a granuloma. Based on the histopathological results, Cawson et al suggested an alternative term as "granuloma telangiectacticum" since there are numerous blood vessels present in it and has an inflammatory nature.<sup>12</sup> Some researchers believed pyogenic granuloma to be infectious in nature, which was caused by *Staphylococcus* and *Botryomycosis*.<sup>10</sup> It is now agreed that pyogenic granuloma is caused by some minor trauma to the tissues, which may provide a path for nonspecific microorganisms, and the tissue responds by proliferation of vascular tissue.<sup>5</sup> According to Regezi et al,<sup>9</sup> pyogenic granuloma is due to profuse proliferation of tissue in response to any injury caused by any stimulus,

e.g., calculus, sharp tooth, overhanging restoration, foreign material, etc. Pyogenic granuloma can occur in all age groups, in both the sexes, but females are more prone for this because of the hormonal changes that women undergo during puberty, pregnancy, and menopause.<sup>12</sup> In this case, the patient was a girl near her pubertal growth spurt, with a poor oral hygiene and chronic irritation in the gingiva due to a mobile tooth "63." This probably justifies the development and enlargement of the lesion.

Clinically, pyogenic granuloma is a pink to red/purple hyperplastic, nodular growth.<sup>4</sup> It may occur on gingiva, lips, tongue, buccal mucosa, hard palate; gingiva being the most predominant site. They may be sessile or pedunculated, are soft in consistency, and generally painless.<sup>7</sup> Pyogenic granuloma histologically shows prominent growth of capillaries in the hyperplastic tissue. The pathogenesis of pyogenic granuloma is associated with increase in some angiogenesis enhancers (vascular endothelial growth factor, fibroblast growth factor) and decrease in angiogenesis inhibitors (angiostatin, thrombospondin-1).<sup>13</sup> Generally, no radiographic findings are seen in association with pyogenic granuloma, however, localized alveolar bone resorption may be seen associated with it, in long-standing cases.<sup>10</sup> In the present case, there were no obvious radiographic findings.

Differential diagnosis of pyogenic granuloma includes irritation fibroma or traumatic fibroma, peripheral giant cell granuloma, and peripheral ossifying fibroma. However, final diagnosis can only be made after confirmation by histopathological examination of biopsied tissue mass. Microscopically, it is completely or partially covered by parakeratinized or nonkeratinized stratified squamous epithelium.<sup>10</sup> Its core has a proliferating

vascular connective tissue stroma with acute or chronic inflammatory infiltrates.<sup>4</sup> Surface can be ulcerated or nonulcerated, and there is a sparse collagen found in the connective tissue.<sup>1</sup> Based on the proliferation of vascular tissue, it has two variants known as lobular capillary hemangioma (LCH) and non-LCH type.<sup>4</sup>

Treatment consists of removal of irritants and surgical excision of the complete lesion.<sup>4</sup> Other treatment forms may be excision through neodymium-doped yttrium aluminum garnet laser, flash lamp pulsed dye laser, or cryosurgery. Intralesional injections of ethanol or steroid and sodium tetradecyl sulfate have also been suggested. Low rate of recurrence is seen with pyogenic granuloma and in such cases, reexcision may be done.<sup>7</sup>

The present case was followed up for a period of 1 year. The healing was uneventful and satisfactory with no signs of recurrence.

## CONCLUSION

Pyogenic granuloma is a well-known and a commonly present lesion of the oral mucosa. Varied reasons are possible for its occurrence and can be presented in a wide variety of forms. So, it should always be kept in mind while diagnosing a reddish hyperplastic growth and adequate treatment should be done accordingly.

## REFERENCES

1. Kamal R, Puri A, Gupta R. Oral pyogenic granuloma. *IJDS* 2010;2(5):31-32.
2. Jafarzadeh H, Sanatkhan M, Mohtasham N. Oral pyogenic granuloma: a review. *J Oral Sci* 2006 Dec;48(4):167-175.
3. Campbell JP, Grekin RC, Ellis CN, Matsuda-John SS, Swanson NA, Voorhees JJ. Retinoid therapy is associated with excess granulation tissue responses. *J Am Acad Dermatol* 1983 Nov;9(5):708-713.
4. Asha V, Dhanya M, Patil BA, Revanna G. An unusual presentation of pyogenic granuloma of the lower lip. *Contemp Clin Dent* 2014 Oct;5(4):524-526.
5. Shafer, WG.; Hine, MK.; Levy, BM. *Shafer's textbook of oral pathology*. 5th ed. Amsterdam: Elsevier Health Sciences; 2006. p. 459-461.
6. Wood, NK.; Goaz, PW. *Textbook of differential diagnosis of oral and maxillofacial lesions*. 5th ed. St Louis: Mosby; 1997. p. 32-34.
7. Verma PK, Srivastava R, Baranwal HC, Chaturvedi TP, Gautam A, Singh A. Pyogenic granuloma – Hyperplastic lesion of the gingiva: case reports. *Open Dent J* 2012;6:153-156.
8. Miller RA, Ross JB, Martin J. Multiple granulation tissue lesions occurring in isotretinoin treatment of acne vulgaris: successful response to topical corticosteroid therapy. *J Am Acad Dermatol* 1985 May;12 (5 Pt 1):888-889.
9. Regezi, JA.; Sciubba, JJ.; Jordan, RC. *Oral pathology: clinical pathologic considerations*. 4th ed. Philadelphia: WB Saunders; 2003. p. 115-116.
10. Angelopoulos AP. Pyogenic granuloma of the oral cavity: statistical analysis of its clinical features. *J Oral Surg* 1971 Dec;29(12):840-847.
11. Cawson, RA.; Binnie, WH.; Speight, PM.; Barrett, AW.; Wright, JM. *Lucas's pathology of tumors of oral tissues*. 5th ed. Missouri: Mosby; 1998. p. 252-254.
12. Kamal R, Dahiya P, Puri A. Oral pyogenic granuloma: various concepts of etiopathogenesis. *J Oral Maxillofac Pathol* 2012 Jan;16(1):79-82.
13. Yuan K, Jin YT, Lin MT. Expression of Tie-2, angiopoietin-1, angiopoietin-2, ephrinB2 and EphB4 in pyogenic granuloma of human gingiva implicates their roles in inflammatory angiogenesis. *J Periodontal Res* 2000 Jun;35(3):165-171.