

# Morphometric Analysis of Foramen Magnum in Gender Determination: A Radiographic Study

<sup>1</sup>Aparna Srivastava, <sup>2</sup>G Poornima, <sup>3</sup>P Balaji, <sup>4</sup>Pulivarthi Sushma, <sup>5</sup>Nikhat Gagze

## ABSTRACT

**Introduction:** Sex determination is a significant criterion in identification, and when all bones of the diseased skeleton are present, sex determination becomes slightly easy. Craniometric features can be used to aid in identifying an individual from a skull found detached from its skeleton. Foramen magnum (FM) dimensions tend to stabilize after the second decade of life and the reconstructed computed tomography (CT) images can provide reliable measurement of these dimensions.

**Aim:** Estimation of FM in gender determination using CT scanning.

**Objective:** To study the vagueness and reliability of the FM in gender classification through the use of reconstructed helical CT images.

**Materials and methods:** A total of 40 patients (20 males and 20 females; age range, 20 to 49 years) were selected for this study. The FM measurements (sagittal, transverse, circumference, and area) were obtained from reformatted axial sections using helical CT scan. The FM sagittal diameter, FM transverse diameter, FM circumference, and the FM area were measured. Head width and circumference were also measured.

**Results:** Multivariate analysis showed 89.7% of FM dimensions of males and 71.8% of FM dimensions of females were gendered correctly.

**Keywords:** Computed tomography, Foramen magnum, Gender determination.

**How to cite this article:** Srivastava A, Poornima G, Balaji P, Sushma P, Gagze N. Morphometric Analysis of Foramen Magnum in Gender Determination: A Radiographic Study. *Int J Prev Clin Dent Res* 2016;3(4):246-250.

**Source of support:** Nil

**Conflict of interest:** None

## INTRODUCTION

Skeletal identification in decomposing human residues is one of the most difficult challenges in forensic medicine. Determination of sex is also crucially significant in the identification. If virtually complete skeleton exists, sex

estimation is not challenging. After pelvis, the skull is the most easily sexed portion of the skeleton, but the determination of the sex from the skull is not reliable until well after puberty. Craniometric features are included among these physiognomies, which are closely connected to forensic medicine since they can be used to aid in identifying an individual from a skull found detached from its skeleton. The craniofacial structures have the advantage of being composed largely of hard tissue, which is relatively indestructible.<sup>1</sup> Due to the thickness of the cranial base and its relatively protected anatomical position and the area of skull base tends to withstand both physical insults and inhumation somewhat more successful than many other areas of the cranium.<sup>2</sup> The skull and, particularly, the skull base has been analyzed with varying results and levels of success. The foramen magnum (FM) is the largest opening in the skull base, and it is oval, wider behind with greatest diameter being anteroposterior. It contains the lower end of the medulla oblongata, the vertebral arteries, and spinal accessory nerves.<sup>3</sup> The dimensions of the FM are clinically significant because of the above-mentioned vital structures passing through it.<sup>4</sup> The head width, the circumference of the head, and the FM have been used to determine gender in unidentifiable human residues.<sup>5-9</sup> The present study was conducted with an aim to evaluate the morphology of FM in gender determination, and the objective was to assess the value and accuracy of the measurements of FM with respect to gender.

## MATERIALS AND METHODS

A prospective study was undertaken in which study sample consisted of 40 patients including 20 males and 20 females ranging from 20 years to 49 years. Patients were selected from the Department of Radiology, RajaRajeswari Dental College & Hospital, Bengaluru, Karnataka, India, for the purpose of imaging of the brain for several reasons. The study protocol was approved by the college ethical committee. Inclusion criteria were patient should fall under the above-mentioned age range. Exclusion criteria comprise patients with history of trauma, surgery, or pathological lesions in the region of the FM. The FM measurements (sagittal, transverse, circumference, and area) were obtained from reformatted axial sections using helical computed tomography (CT) scan (Somatom Emotion, Siemens, AG,

<sup>1,4,5</sup>Postgraduate Student, <sup>2</sup>Reader, <sup>3</sup>Professor and Head

<sup>1-5</sup>Department of Oral Medicine and Radiology, RajaRajeswari Dental College & Hospital, Bengaluru, Karnataka, India

**Corresponding Author:** Aparna Srivastava, Postgraduate Student Department of Oral Medicine and Radiology, RajaRajeswari Dental College & Hospital, Bengaluru, Karnataka, India, e-mail: dentistaparna04@gmail.com

Erlangen, Germany) with 5 mm thickness, 130 kVp, 200 to 230 mAs, 1,800 AU window levels, and 35 to 45 seconds scan time. All sections selected were parallel to the plane of the FM in order to select the best image of the foramen. The FM sagittal diameter (FMSD) was recorded as the greatest anteroposterior dimension of the FM and the FM transverse diameter (FMTD) was recorded as the greatest width of the FM (Fig. 1). The FM circumference (FMC) and the FM area (FMA) were automatically given after tracing the bony margin of the FM on the CT (Fig. 2). Head width was also measured from the axial sections as a maximum transverse width at the Euryon point.<sup>9</sup> Head circumference was measured clinically by a metric tape at the level of the glabella when the patient was in an upright position.

Statistical descriptions were calculated from the measurements, the mean, and standard deviation (SD). Consequently, to determine the ability to classify between the both genders, multivariate discriminant function analysis was used to analyze sex differences using Statistical Package for the Social Sciences software.

## RESULTS

A total of 40 individuals were studied (20 females and 20 males with an age range of 20 to 49 years). Relative measurements with the maximum and minimum values, means, and SD for each dimension of the FM in both males and females are presented. Pearson's correlation equation was applied for all FM measurements. All measurements were significantly correlated with each other ( $p > 0.01$ ). The strongest correlation was between FMC and FMA for males and females ( $r = 0.972$  and  $0.951$  respectively) and between FMSD and FMC ( $r = 0.816$  and  $0.911$  for males and females respectively). In males, it was found that the maximum values were 39 and 31 mm, whereas the minimum values were 31 and 26 mm for the sagittal

and transverse diameters respectively (Tables 1 to 3). The maximum values obtained for female subjects were 36 and 30 mm, whereas the minimum values were 28 and 24 mm for the sagittal and transverse diameters respectively (Table 1). The SD, TD, and FMA in males were significantly greater than in females ( $p < 0.001$ ). Statistical comparisons of the correlations of all measured parameters were made. The maximum and minimum areas found in males and females were 1,266 and 710 mm<sup>2</sup> and 1,006 and 677 mm<sup>2</sup> respectively.

The equation provided by the model to calculate D will aid in the prediction process of gender by substituting the values of the specific measurement(s) in the equation and the equation is quoted below. Among the skull measurements included, FMC was the best discriminator, followed by FMA (Table 4).

$$D = -12.273 + (0.136 \times \text{FMSD}) + (0.078 \times \text{FMTD}) + (0.165 \times \text{FMC}) + (-0.008 \times \text{FMA})$$

The value of calculated D greater than reference D indicates male gender, while a value less than the reference value indicates female gender. As a result of this multivariate analysis, 89.7% of FM dimensions of males and 71.8% of FM dimensions of females were sexed correctly (Table 5).

## DISCUSSION

Sex determination is an important enigma in the identification.<sup>10</sup> When the skeleton exists completely, sex can be estimated with proficient accuracy. This estimation rate is 98% in the existence of the pelvis and cranium, 95% with only the pelvis or the pelvis and long bones, and 80 to 90% with only the long bones.<sup>11</sup> However, in explosions, warfare, and other mass cataclysms like aircraft crashes, identification and sex determination are not an easy task.

**Table 1:** Gender difference for foramen magnum and other craniometric measurements

Variables	Range	Mean	SD	SE	Range	Mean	SD	SE	p-value
FMSD	28.9–36.2	31.86	1.872	0.418	30–39.6	34.48	2.447	0.547	<0.001
FMTD	24–30.2	27.64	1.638	0.366	26–31.7	29.14	1.79	0.40	<0.001
FMC	86.6–105.9	95.66	4.7	1.05	92.1–118.2	101.12	7.13	1.59	<0.001
FMA	515–750	698.4	61.32	13.71	570–920	774.3	94.6	21.73	<0.001
HC	53.2–57.3	54.37	1.007	0.22	54.2–57.5	55.92	0.85	0.196	<0.001
HD	12.4–14.8	13.27	0.58	0.13	13.2–14.4	13.70	0.35	0.079	<0.001

SE: Standard error; HC: Head circumference; HD: Head diameter

**Table 2:** Correlation among tested variables of female group

Females	FMSD	FMTD	FMC	FMA	HC	HW
FMSD	1	0.3707	0.5731	0.5262	0.2587	0.345
FMTD	0.3707	1	0.2705	0.567	0.7339	0.2318
FMC	0.5731	0.2705	1	0.4805	-0.0092	0.2885
FMA	0.5262	0.567	0.4805	1	0.4364	0.5189
HC	0.2587	0.7339	-0.0092	0.4364	1	0.394
HW	0.345	0.2318	0.2885	0.5189	0.394	1

HW: Head width

**Table 3:** Correlation among all tested variables of male group

Males	FMSD	FMTD	FMC	FMA	HC	HW
FMSD	1	0.6544	0.8605	0.8045	0.2065	-0.007
FMTD	0.6544	1	0.6877	0.1606	0.7488	0.2253
FMC	0.8605	0.6877	1	0.8434	0.2232	-0.867
FMA	0.8045	0.1606	0.8434	1	0.118	0.0671
HC	0.2065	0.7488	0.2232	0.118	1	0.3112
HW	-0.007	0.2253	-0.867	0.0671	0.3112	1

**Table 4:** Discriminant analysis using FM and other craniometric measurements to discriminate between genders

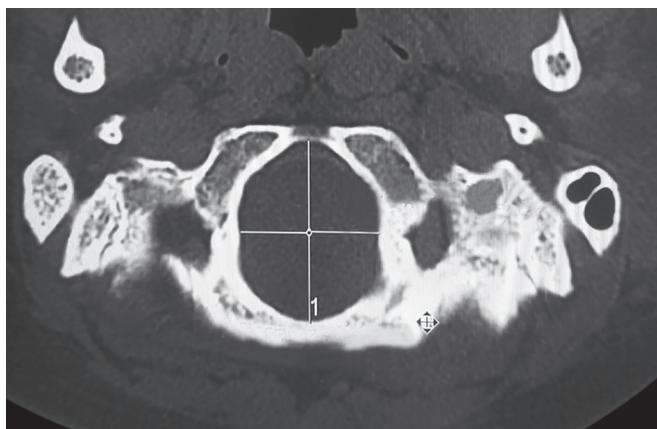
<i>FMSD</i>			
D = -11.862 + 0.034 × FMSD			–
Wilks' lambda = 0.772, p, 0.001	Female	Male	Overall
Percentage of accurately predicted group membership	61.2%	70.76%	66.46%
Functions at group centroids	Female	Male	Classified as male if
	-0.331	0.479	D > 0.014
<i>FMTD</i>			
D = 12.156 + 0.3966 × FMTD			
Wilks' lambda = 0.792, p, 0.001	Female	Male	Overall
Percentage of accurately predicted group membership	68.92%	73.22%	70.08%
Functions at group centroids	Female	Male	Classified as male if
	-0.303	0.443	D > 0.012
<i>FMC</i>			
D = 11.427 + 0.164 × FMC			
Wilks' lambda = 0.664, p, 0.001	Female	Male	Overall
Percentage of accurately predicted group membership	64.54%	74.65%	68.45%
Functions at group centroids	Female	Male	Classified as male if
	-0.367	0.478	D > 0.014
<i>FMA</i>			
D = 8.453 + 0.114 × FMA			
Wilks' lambda = 0.722, p > 0.001	Female	Male	Overall
Percentage of accurately predicted group membership	65.66%	71.83%	70.87
Functions at group centroids	Female	Male	Classified as male if
	-0.548	0.447	D > 0.014
<i>HC</i>			
D = -41.241 + 0.5866 × head c			–
Wilks' lambda = 0.742, p, 0.001	Female	Male	Overall
Percentage of accurately predicted group membership	63.4%	63.6%	63.5%
Functions at group centroids	Female	Male	Classified as male if
	-0.365	0.485	D > 0.0012
<i>HD</i>			
D = -36.826 + 0.596 × head d			
Wilks' lambda = 0.624, p, 0.001	Female	Male	Overall
Percentage of accurately predicted group membership	79.8%	73.6%	76.56%
Functions at group centroids	Female	Male	Classified as male if
	-0.586	0.662	D > 0.0007

**Table 5:** Discriminant analysis using FM measurements to discriminate between males and females

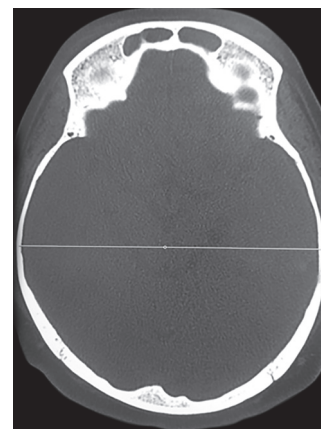
	<i>Standard coefficient</i>		
FMSD	0.224		
FMTD	0.167		
FMC	1.028		
FMA	-0.557		
Percentage of accurately predicted group membership	Female	Male	Overall
	71.8%	89.7%	80.65%
Functions at group centroids	Female	Male	Classified as male, if D > 0.014
	-0.679	0.864	
Wilks' lambda = 0.601, p < 0.001			

The study of anthropometric characteristics is of fundamental importance when solving problems related to identification. The craniofacial structures have the advantage of being composed largely of hard tissue, which is relatively indestructible. Sex estimation can be accomplished

using either morphological or metric methodologies. Statistical methods using metric traits are becoming more popular, with most of the bones having been subjected to linear discriminant classification. Murshed et al<sup>12</sup> studied FM dimensions using spiral CT and recorded the mean value of the FMSD (37.2 mm ± 3.43 mm in males and 34.6 mm ± 3.16 mm in females) and of the FMTD (31.8 mm ± 2.99 mm in males and 29.3 mm ± 2.19 mm in females). These results were higher than those recorded in the present study where FMSD was 34.48 ± 2.4 in males and 31.86 ± 1.87 in females and FMTD was 29.1 ± 1.9 in males and 27.3 mm ± 2.2 in females. This variation might be due to the different measurement techniques (millimetric sliding caliper) followed in their study. It was obvious that the mean value of FMSD and FMTD in males was significantly higher than in females among all studies of the FM. Catalina et al found that FMA found in male and female skulls were 888.4 mm<sup>2</sup> and 801 mm<sup>2</sup> respectively.



**Fig. 1:** Measurement of foramen magnum sagittal diameter and foramen magnum transverse diameter



**Fig. 2:** Measurement of head width

These results were slightly higher than those of the present study. Gunay et al<sup>1</sup> measured the FMA directly on Turkish skulls, estimating it by considering it as a “circle” whose “radius” was attained as the mean value between the half measurements of the length and the breadth; the results showed a mean value of  $909.91 \text{ mm}^2 \pm 126.02 \text{ mm}^2$  for males and  $819.01 \text{ mm}^2 \pm 17.24 \text{ mm}^2$  for females. These values were higher than those reported in the present study; such variation may be due to differences between the anatomic and radiographic methods. Gapert et al<sup>13</sup> in 2008 in Britain and Ukoha et al<sup>14</sup> in 2011 in Nigeria – population dimensions included were FMSD, FMTD, and FMA in all the above-stated studies, which show similar results with the present study. Deshmukh and Devershi<sup>15</sup> measured head width using sliding Vernier calipers directly on the crania, which resulted in mean values of  $13.1 \text{ cm} \pm 0.49 \text{ cm}$  for males and  $12.7 \text{ cm} \pm 0.49 \text{ cm}$  for females. These values were lower than those recorded in the present study. Deshmukh and Devershi measured head circumference using standard flexible steel tape on crania, which give rise to mean values of  $49.6 \text{ cm} \pm 1.33 \text{ cm}$  in males and  $47.9 \text{ cm} \pm 1.55 \text{ cm}$  in females. Gunay et al<sup>1</sup> assessed the usefulness of FM size for gender determination and the accuracy rate was found to be 64.0% in females and 64.5% in males. Compared with the present study, the accuracy rate in females was higher by 1.8%, while the accuracy rate in males was lower than the present study by 12.2%. These values were much higher than those of the current study, which might be because of the difference between the anatomical and radiographic methods. A similar study was conducted by Uthman et al,<sup>16</sup> who showed similar results involving all the parameters, which were used in the present study, and it reveals that all these parameters can give the relevant and accurate results that are highly beneficial to reach the aim.

## CONCLUSION

It can be concluded that the reconstructed CT image can provide valuable measurements for the FM and could be

used for sexing. The FM dimensions stabilize after the second decade of life and, thereby, constructed CT images can provide reliable measurement of these dimensions. The significant difference was noticed when FMSD and FMTD were compared. Hence, it is a useful modality to determine gender.

## REFERENCES

1. Gunay Y, Altinko K, Cagdir S, Kirangil B. Gender determination with skull measurements (in Turkish). *J Forensic Med* 1997;13:13-19.
2. Graw, M. Morphometric and Morphognostic of the human skull. In: Oehmicen M, Geserick G, editors. *Osteological identification and age estimation*. Germany: Schmidt-Romhild, Lubeck; 2001. p. 103-121.
3. Standarding S. *Gray's anatomy. The anatomical basis of clinical practice*. 39th ed. London: Elsevier Churchill Livingstone; 2005. p. 460.
4. Zaidi SH, Dayal SS. Variations in the shape of foramen magnum in Indian skulls. *Anat Anz Jena* 1988;167(4): 338-340.
5. Gunay Y, Altinko K, Cagdir S, Sari H. Is foremen magnum size useful for gender determination (in Turkish). *Bull Legal Med* 1998;3:41-45.
6. Cameriere R, Ferrante L, Mirtella D, Rollo UF, Cingolani M. Frontal sinuses for identification: quality of classifications, possible error and potential correction. *J Forensic Sci* 2005 Jul;50(4):770-773.
7. Rogers TL. Determining the sex of human remains through cranial morphology. *J Forensic Sci* 2005 May;50(3):493-500.
8. Gruber P, Henneberg M, Boni T, Ruhli FJ. Variability of human foramen magnum size. *Anat Rec* 2009 Nov;292(11): 1713-1719.
9. Patil KR, Mody RN. Determination of sex by discriminant function analysis and stature by regression analysis: a lateral cephalometric study. *Am J Orthod Dentofacial Orthop* 2005;128:157-160.
10. Fernandes CL. Forensic ethnic identification of crania. The role of the maxillary sinus – a new approach. *Am J Forensic Med Pathol* 2004 Dec;25(4):302-313.
11. Krogman WM, Iscan MY. *The human skeleton in forensic medicine*. 2nd ed. Springfield, IL: Charles C Thomas Publishing; 1986. p. 493.



12. Murshed KA, Cicekcibasi AE, Tuncer I. Morphometric evaluation of the foramen magnum and variations in its shapes: a study on computerized tomographic images of normal adults. *Turk J Med Sci* 2003;301-306.
13. Gapert, R., Black S, Last J. Sex Determination from the occipital Condyle: Discriminant Function Analysis in an Eighteenth and Nineteenth Century British Sample American. *J Physi Anthro* 2008; 138(4):384-394.
14. Ukoha U, Egwu OA, Okafor IJ, Anyabolu AE, Ndukwe GU, Okpala I sexual dimorphism in the foramen magnum of nigerian adult. *Int J Biol Med Res* 2011;2(4):878-881.
15. Deshmukh AG, Devershi DB. Comparison of cranial sex determination by univariate and multivariate analysis. *J Anat Soc India* 2006;55:1-5.
16. Uthman AT, Al-Rawi NHA, Timimi JF. Evaluation of foramen magnum in gender determination using helical CT scanning *dmfr* 2012;41,197-202.