

CASE REPORT

Unilateral Congenital Choanal Atresia in a 48-Year-Old Patient

¹Lília Ferraria, ²Sílvia Alves, ³Helena Rosa, ⁴Mário Santos, ⁵Luis Antunes

ABSTRACT

Aim: To report a case of unilateral choanal atresia diagnosed in a 48-year-old, presenting with fatigue as the major symptom. To highlight the importance of a detailed clinical history and physical examination for an accurate diagnosis.

Background: Choanal atresia is an uncommon and often poorly recognized cause of unilateral or bilateral nasal obstruction. It is a congenital condition that occurs in approximately 1 in 5,000 to 8,000 live births.

Case report: This study reports a case of unilateral choanal atresia diagnosed in a 48-year-old presenting with fatigue as the major symptom. The patient presented with a lifelong history of tiredness investigated in cardiology. She was treated by a combined transseptal and transnasal endoscopic surgical technique. Topical use of mitomycin was performed with no use of stents, with clinical regression of the symptoms.

Conclusion: Unilateral choanal atresia usually presents in younger patients but can be undiagnosed until adulthood due to the nonspecific nature of the symptoms. This diagnosis should be, therefore, considered in all ages and bedside diagnostic procedures should, then, be done. Nasal endoscopy and computed tomography (CT) scan are the gold standard for the diagnosis. The use of stents and mitomycin C topically as an adjunct to the surgical repair of choanal atresia is a controversial subject.

Keywords: Choanal atresia, Endoscopic surgical procedure, Mitomycin C.

How to cite this article: Ferraria L, Alves S, Rosa H, Santos M, Antunes L. Unilateral Congenital Choanal Atresia in a 48-Year-Old Patient. *Int J Otorhinolaryngol Clin* 2017;9(1):28-31.

Source of support: Nil

Conflict of interest: None

INTRODUCTION

Choanal atresia is an uncommon and often poorly recognized cause of unilateral or bilateral nasal obstruction. It is defined as a developmental failure of the posterior nasal cavity to communicate with the nasopharynx. Johann

Roderer was the first to describe it in 1755 and Emmert was the first who attempted to correct it surgically in 1851.

It is an unusual congenital malformation affecting roughly 1 out of every 5,000 to 8,000 newborns and may, more commonly, be unilateral ($\approx 60\%$ of all cases) or bilateral (more severe). Choanal atresia occurs more commonly in females than in males (2:1), and there is predominance on the right side.¹⁻⁴ Unilateral choanal atresia is usually not associated with other facial anomaly or with syndromic malformations.²

Anatomically, it manifests as a narrow nasal cavity, altered growth of the horizontal and vertical palatine processes, and thickening of the vomer and/or of the medial alae of the pterygoid processes. Mixed bony/membranous abnormalities are found in 70% of cases, purely bony atresia in 30%, and purely membranous are not considered to be existent.¹

The diagnosis depends on a high degree of suspicion. Unilateral choanal atresia may have a delayed diagnosis with less dramatic unilateral rhinorrhea or unilateral nasal obstruction with some cases diagnosed in adulthood. Bilateral atresia often presents at delivery with acute respiratory distress due to the fact that newborns are obligate nasal breathers.^{1,3}

The diagnosis of choanal atresia is based on clinical examination with nasal endoscopy and computed tomography (CT) the gold standard for the diagnosis.¹⁻³

Surgical treatment is mandatory. Different approaches have been described over time for the treatment of choanal atresia: Transnasal, transpalatal, transantral, or transseptal. Moreover, there is controversy about the usefulness of placing stents and adjuvant mitomycin.¹

CASE REPORT

A 48-year-old female patient presented with a lifelong history of tiredness investigated in cardiology. She performed a Holter monitor and cardiac CT scan, which were normal. Her medical history was remarkable for an adenoidectomy and tonsillectomy at age 14. She was referred to ear, nose, and throat consultation for hearing loss investigation. On examination, earwax was removed, and a profuse clear mucoid discharge in her right nostril was noticed (Fig. 1). The right nostril was completely blocked, which was confirmed by holding a Glatzel mirror under her nose and asking her to breathe

^{1,2}Resident, ^{3,4}Assistant, ⁵Chief

¹⁻⁵Department of ENT, Hospital Garcia de Orta, Almada Portugal

Corresponding Author: Lília Ferraria, Resident, Department of ENT, Hospital Garcia de Orta, Almada, Portugal, Phone: +00351212940294, e-mail: liliaferraria@gmail.com

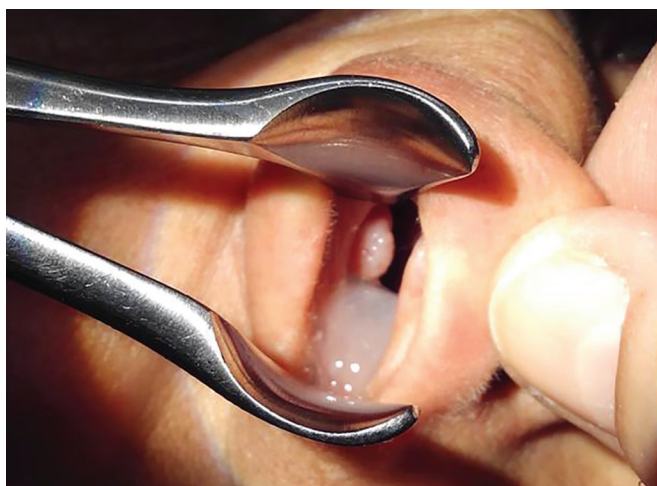

Fig. 1: Rhinoscopy: Profuse clear mucoid discharge in the nasal cavity

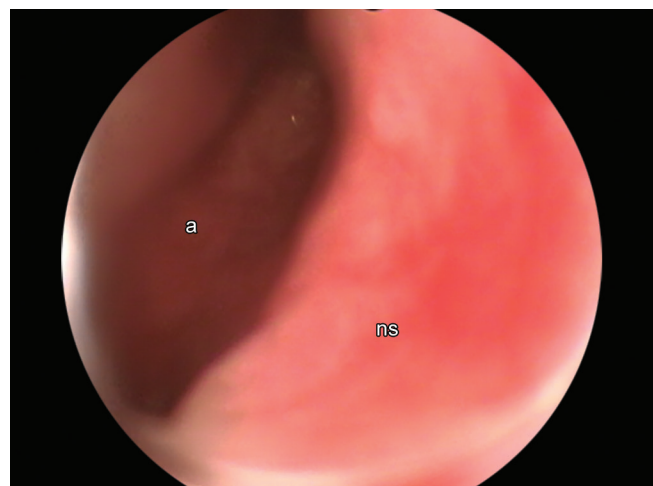


Fig. 2: Nasal endoscopy examination: Right choanal atresia. A, atretic plate; ns, nasal septum

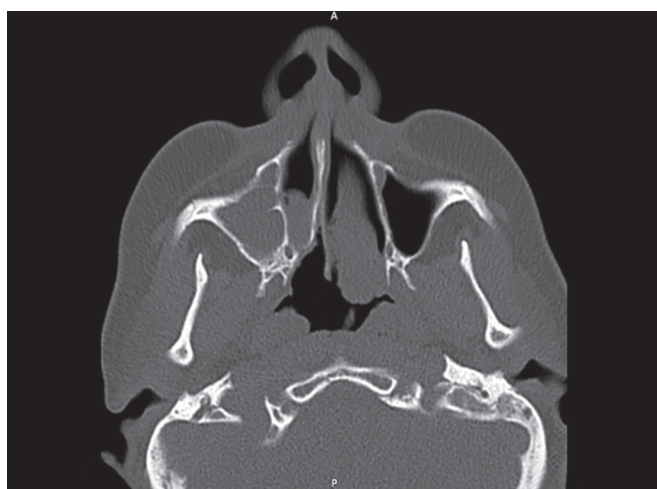

Fig. 3: Axial CT scan shows right-sided unilateral choanal atresia. Note the inflammatory thickening of the right maxillary sinus mucosa and the narrow nasal cavity on the atresia side due to thickened pterygoid plates

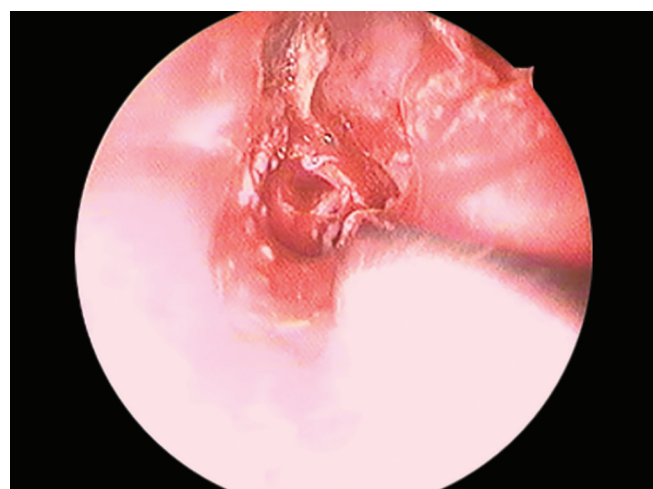


Fig. 4: The choana is shown immediately after opening during endoscopic surgery

only through her nose. The patient referred nasal obstruction of the right nostril only when specifically asked for it, saying she had never noticed it before.

The diagnosis of right choanal atresia was suspected and confirmed by nasal endoscopy (Fig. 2) and CT scan of the paranasal sinuses. Computed tomography scan showed a right bony and membranous obstruction with thickening of the vomer, a narrow nasal cavity on the atresia side, due to thickened pterygoid plates (Fig. 3). Patient was treated by transnasal endoscopic surgical technique associated with transseptal access. Surgery was performed under general anesthesia with endotracheal intubation. The nasal cavity was packed with cottonoid pledgets soaked in adrenaline for 7 minutes. A 0°, 4 mm nasal endoscope was used. Prior to beginning the surgery, gauze was placed orally in the cavum to fill the nasopharynx and give easier orientation once the atretic plate is perforated. A cold resection of the posterior

nasal septum anterior to the atretic plate was performed and then removal (Fig. 4): A vertical, hemitransfixion incision was made in the septum, 1 cm anterior to the atretic plate. This incision continued along the floor of the fossa in the direction of the tail of the inferior concha. A J-shaped mucosal flap was raised to expose the osteo-cartilaginous septum and the atretic plate. This flap was preserved for the entire surgery. On the contralateral side, a vertical incision was made in the septum at the level of the contralateral incision. This incision was extended superiorly, at a right angle, at the level of the free edge of the middle concha to the choanal border. This mucosal flap was raised and preserved. Once both flaps had been raised, a posterior septectomy was performed, and the atretic plate was punctured inferomedially with the tip of the aspirator. After opening the access with the nasopharynx (the gauze previously placed was identified), it was circumferentially widened with forceps for the soft

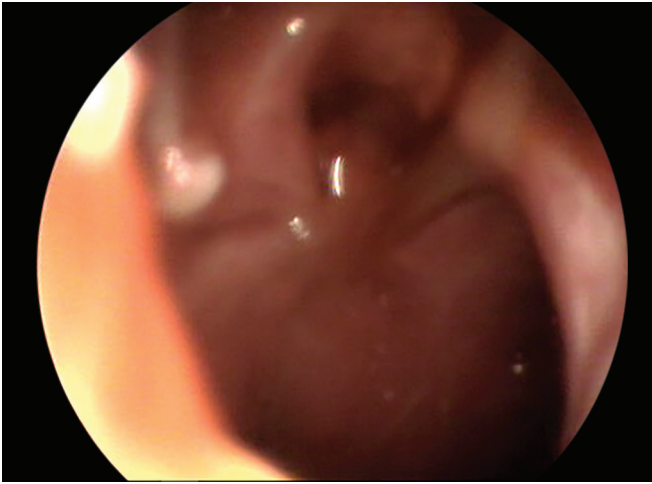


Fig. 5: Complete opening of the atresia, the nasopharynx is seen

and bone tissue. Once a broad communication between the nasal fossae and nasopharynx was established, the flaps were carefully replaced to cover the bone exposed on the roof and floor of the neochoana. Topical application of mitomycin C (0.4 mg/mL), with 5 mL of the solution soaked in cottonoid pledgets, was left in place for 5 minutes in the neochoana (Fig. 5). No postoperative stenting was used, and the nasal cavity was packed with a Merocel for 48 hours. The patient was discharged within 48 hours after the surgery and a regular follow-up with nasal endoscopy was performed. The patient showed adequate patency at 1 year with clinical regression of the symptoms.

DISCUSSION

Even though the symptomatology of unilateral choanal atresia is not life threatening and less severe than the bilateral one, surgical repair is indicated for all the affected patients. Persistent unilateral rhinorrhea makes the occurrence of a surgical intervention mandatory.²

A CT scan of the paranasal sinuses is the test of choice for diagnosis. This examination shows the type of atresia plate, other associated anomalies and also contributes to surgical planning. It must always be associated with nasal endoscopy. Computed tomography usually shows the normal aeration of the paranasal sinuses, confirming that the sinus development occurs regardless of posterior nasal ventilation and draining, as confirmed in the present case.⁴

Bone atresia usually occurs 1 to 2 mm anterior of the posterior edge of the hard palate. Regardless of the technique, the abnormal posterior portion of the vomer and part of the lateral pterygoid bone should be resected in order to create a common posterior nasal cavity. The choanal opening should be performed from the confluence region between the hard palate, the vomer, and atresia plate since this is the thinnest area.⁴

A combined use of transseptal and transnasal technique is described providing excellent visualization of atresia.⁴

The transnasal surgery compared with the transpalatal approach has less trauma, lower bleeding risk, shorter operative time, few orthodontic complications, faster recovery postoperatively, and shorter hospital stay. It has disadvantages, such as poor visualization of the surgical field and higher restenosis rates.^{3,4}

The transseptal route allows, in addition to the correction of atretic plate, the removal of the posterior portion of the vomer, the lateral pterygoid process, and simultaneous correction of potential septal defects. This technique is especially effective in patients with choanal atresia presenting a thick posterior portion of the vomer, associated with medial projection of the pterygoid process.⁴

Regardless of the surgical technique, the mucosal damage is minimal, avoiding the formation of granulation tissue.

Restenosis of the choanae is a major problem in surgery of choanal atresia. The literature varies on surgical failure as the rate of restenosis ranges from 0 to 85% of the cases. Surgical failure is considered when choanal restenosis is more than 50% of the diameter.⁴

Classically, postoperative nasal stenting has been used to avoid restenosis. The premise is that it would hold the mucosal flaps in place and would prevent the narrowing of the choanal lumen while healing takes place. There is a tendency to avoid nasal stenting because stents were found to damage the nasal mucosa, which would lead to an increase in granulation tissue, scarring, bacterial overgrowth and biofilms, and alteration of mucous drainage.^{1,2,4} All of these factors would work against the ultimate aim of achieving lasting patency. Recent studies^{5,6} have concluded that there are no differences in the use of stents with respect to the rate of restenosis. This stenting may be avoided performing only mucosal flap rotation covering the wound area.

New studies describe the use of topical mitomycin in choanal atresia in order to decrease restenosis rates.^{7,8} Mitomycin C has been shown to inhibit fibroblast proliferation, avoiding the growth of scar tissue and thereby prolong nasal patency when applied topically. Its clinical use as a modulator of the wound-healing response has no systemic side effects when applied topically.² The recommended concentrations of topical mitomycin range from 0.4 to 0.5 mg/mL, for 3 to 5 minutes applied on the edges of the new choana. The maximum nontoxic concentration topical described is 1 mg/mL.⁴

CONCLUSION

Unilateral choanal atresia usually presents in younger patients but can be undiagnosed until adulthood due to the nonspecific nature of the symptoms. This diagnosis should be, therefore, considered in all ages, and bedside diagnostic procedures should, then, be done. Nasal

endoscopy and CT scan are the gold standard for the diagnosis. In our experience, transnasal access endoscopy is the way of choice for surgical correction of congenital choanal atresia. In cases where there is significant thickening of the posterior portion of the vomer, a transseptal access can be associated with transnasal. There is no need for stenting after surgery if a mucosal flap covers the wound area of the new choana.

CLINICAL SIGNIFICANCE

This report documents the case of a patient with unilateral choanal atresia, which has presented in adult age group and with complaints not clearly pointing to the diagnosis. The varying methods of investigation and management are discussed.

REFERENCES

1. Llorente JL, López F, Morato M, Suárez V, Coca A, Suárez C. Endoscopic treatment of choanal atresia. *Acta Otorrinolaringol Esp* 2013 Nov-Dec; 64(6):389-395.
2. Rombaux P, de Toeuf C, Hamoir M, Eloy P, Bertrand B, Veykemans F. Transnasal repair of unilateral choanal atresia. *Rhinology* 2003 Mar; 41(1):31-36.
3. da Fontoura Rey Bergonse G, Carneiro AF, Vassoler TM. Choanal atresia: analysis of 16 cases--the experience of HRAC-USP from 2000 to 2004. *Braz J Otorhinolaryngol* 2005 Nov-Dec; 71(6):730-733.
4. Frota AE, Paes V, Esquenazi D, Felix F, Vasconcelos S, Joffily L. Bilateral congenital choanal atresia: 35 years old patient. *Intl Arch Otorhinolaryngol* 2008;12:454-458.
5. Cedin AC, Atallah AN, Andriolo RB, Cruz OL, Pignatari SN. Surgery for congenital choanal atresia. *Cochrane Database Syst Rev* 2012 Feb;2:CD008993.
6. Strychowsky JE, Kawai K, Moritz E, Rahbar R, Adil EA. To stent or not to stent? A meta-analysis of endonasal congenital bilateral choanal atresia repair. *Laryngoscope* 2016 Jan; 126(1):218-227.
7. Carter JM, Lawlor C, Guarisco JL. The efficacy of mitomycin and stenting in choanal atresia repair: a 20 year experience. *Int J Pediatr Otorhinolaryngol* 2014 Feb; 78(2):307-311.
8. Bozkurt MK, Keles B, Azimov A, Ozturk K, Arbag H. The use of adjunctive topical mitomycin in endoscopic congenital choanal atresia repair. *Int J Pediatr Otorhinolaryngol* 2010 Jul; 74(7):733-736.