

CASE STUDY

A Modified Cutler-Beard Technique to manage Extensive Sebaceous Gland Carcinoma of Upper Eyelid

¹Pranav Gupta, ²Y Rizvi, ³Etti Goyal

ABSTRACT

Introduction: Sebaceous gland carcinoma (SGC) is a rare tumor affecting the elderly, with a predisposition for females arising from the meibomian glands and occurring more commonly on the upper eyelid. Diagnosis is difficult because the tumor mimics chalazion or blepharitis. Sebaceous gland carcinoma has a mortality rate of about 5 to 10%.

Aim: To present a modified Cutler-Beard technique of lid reconstruction to manage a case of extensive SGC of upper lid.

Materials and methods: A 65-year-old male presented with a rapidly growing extensive mass of right upper eyelid (size 4.2 × 4 × 2.1 cm) causing mechanical ptosis. Histopathology confirmed the diagnosis as SGC. Wide excision of the lesion was performed sacrificing the whole upper eyelid. Lid reconstruction was done employing lower eyelid as per the bridged flap technique with the use of 4 mm silicon band to enhance lid stability. Patient achieved a satisfactory functional and cosmetic result following the second stage of the procedure.

Conclusion: Total loss of upper eyelid is often dealt with classical lid sharing technique of reconstruction first described by Cutler-Beard. For lid stability, use of tarsus from contralateral eye, ear cartilage has their attendant problems. A 4.0 silicon band was used to replace the sacrificed tarsus, achieving good results.

Keywords: Bridged flap, Meimobian gland, Pleomorphic, Silicon band, Vacuolated.

How to cite this article: Gupta P, Rizvi Y, Goyal E. A Modified Cutler-Beard Technique to manage Extensive Sebaceous Gland Carcinoma of Upper Eyelid. *Int J Adv Integ Med Sci* 2016;1(4):188-190.

Source of support: Nil

Conflict of interest: None

INTRODUCTION

Sebaceous gland carcinoma (SGC) is the third most common malignancy arising from meibomian glands, glands of Zeis, sebaceous glands of the caruncle, and

eyebrow.¹ Worldwide incidence of SGC is 1 to 1.5%.² In Indian population, it constitutes about 31.2% of eyelid malignancies.³ Treatment of choice is wide surgical excision with microscopic monitoring of the margins preferably with frozen section technique.⁴ Surgical excision of the tumor leaves a large lid defect that requires adequate lid reconstruction. Goal of lid reconstruction is normal anatomical and functional restoration.⁵ Choice of reconstructive procedure depends upon extent and tissue loss.

CASE REPORT

A 65-year-old male farmer presented with an indurated, erythematous painless mass involving entire right upper eyelid of about 1 year duration. There was no history of trauma or previous ocular surgery. Swelling started as a small lid marginal nodule mimicking a chalazion and gradually progressed to involve entire upper lid. Mucopurulent discharge persisted and enhanced with time, forming marginal crusting. On local examination, 4.2 × 4 × 2.1 cm sized, firm, multilobulated, indurated, erythematous swelling involving the entire upper lid causing mechanical ptosis and conjunctival congestion was pronounced at the lower fornix (Figs 1A and B). Cornea and other structures of anterior segment were normal. Fundus examination was also normal. Visual acuity was: Oculus dexter (OD) – 6/12 to 6/9, Oculus sinister (OS) – 6/9. Intraocular pressure measurements were: OD – 14.6 mm Hg, OS – 14.6 mm Hg. Ocular motility was unrestricted.

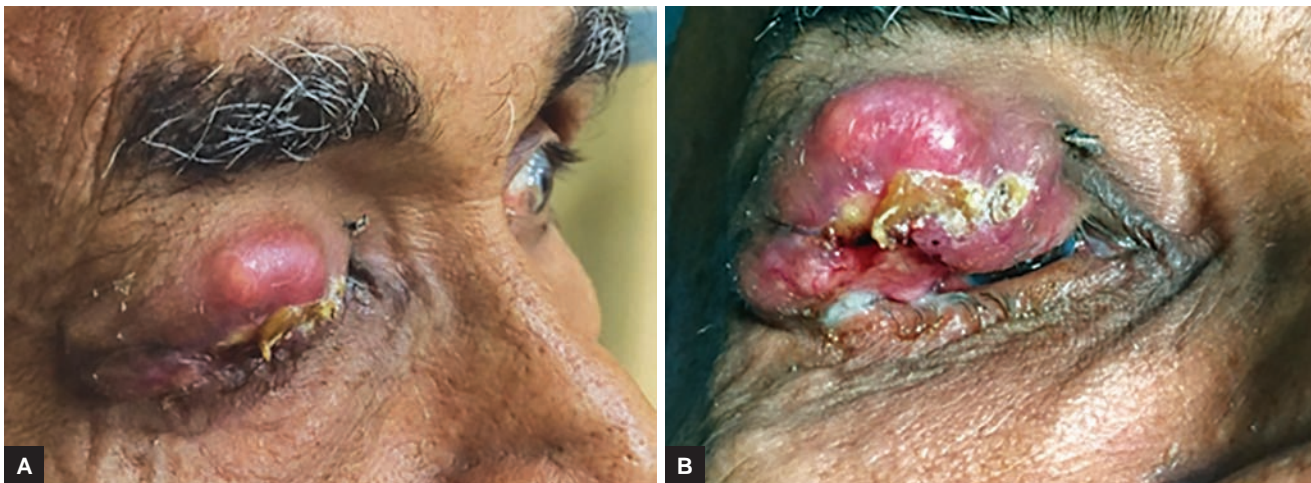On general and systemic examination, no significant abnormality was detected. Routine blood investigations were carried out and erythrocyte sedimentation rate was raised (43 mm after first hour). Fine-needle aspiration cytology of the nodule showed characteristic malignant cells and cytoplasmic vacuolation, which was suggestive of SGC.

After 3 weeks, patient reported with continuous mild pain over lids and periocular area with complete shut-down of eyelid. Swelling had increased in size to about 5.1 × 4.6 × 2.8 cm in its greatest dimensions with hard to firm consistency. Conservative option being ruled out, wide radical excision of the tumor sacrificing the complete upper lid was subsequently planned. As surgery involved sacrificing whole upper eyelid, a Cutler-Beard operation

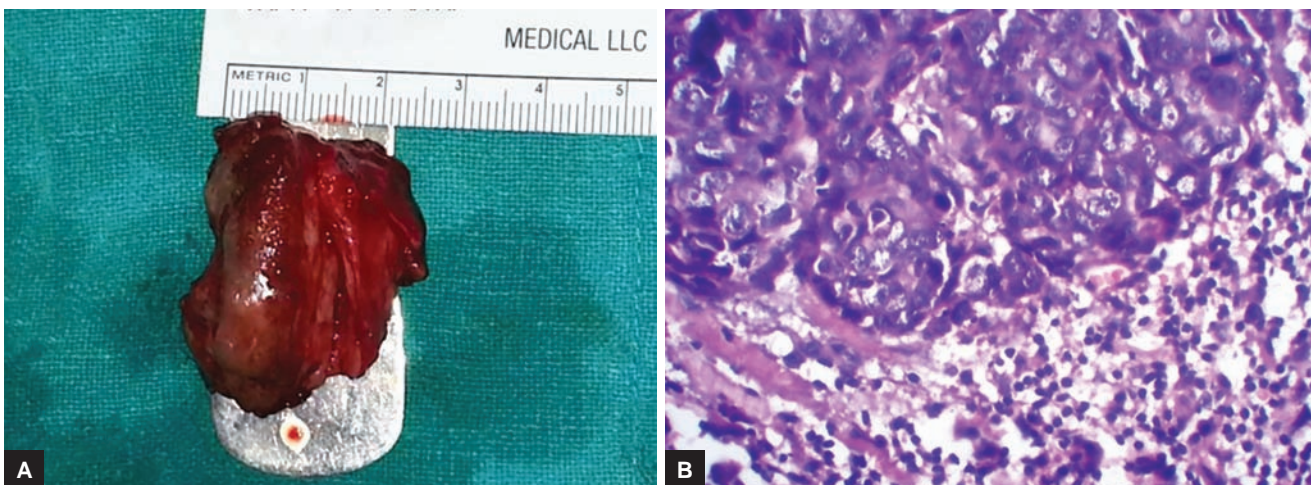
^{1,3}Postgraduate Student (3rd Year), ²Associate Professor

¹⁻³Department of Ophthalmology, Rohilkhand Medical College and Hospital, Mahatma Jyotiba Phule Rohilkhand University Bareilly, Uttar Pradesh, India

Corresponding Author: Pranav Gupta, Postgraduate Student (3rd Year), Department of Ophthalmology, Rohilkhand Medical College and Hospital, Mahatma Jyotiba Phule Rohilkhand University, Bareilly, Uttar Pradesh, India, Phone: +917830003283, e-mail: gupta_pranav59@yahoo.co.in



Figs 1A and B: (A) Extent of lesion; and (B) undersurface of the lesion

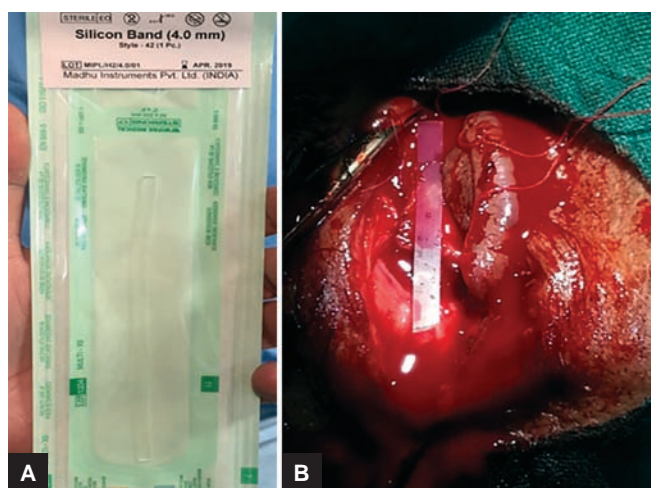


Figs 2A and B: (A) Excised mass; and (B) histopathological section

was contemplated. Total lid excision under general anesthesia was undertaken along with lid reconstruction with lower lid sharing technique of Cutler-Beard procedure. Tarsus reconstruction was employed using a 4 mm silicon band (Figs 2A and B) sutured with conjunctiva and the levator aponeurosis using 5-0 vicryl. Orbicularis and skin were sutured separately, followed by pressure bandage for 48 hours. Excised mass (Fig. 3A) was sent for histopathological examination that revealed vacuolated cytoplasm and hyperchromatic pleomorphic nuclei and mitotic figures (Fig. 3B).

After a hospital stay of 1 week with conservative treatment, the patient was discharged. During fortnightly follow-up, uneventful recovery was noted with no infection or wound dehiscence.

Second-stage surgery was undertaken after 8 weeks following initial surgery, incising upper lid 1 mm above the bucket handle sling margin. Care was undertaken to form a uniform lid edge with everted conjunctiva. Conjunctiva and skin at the newly formed lid margin were sutured with 5-0 vicryl and knots were buried (Figs 4A and B).

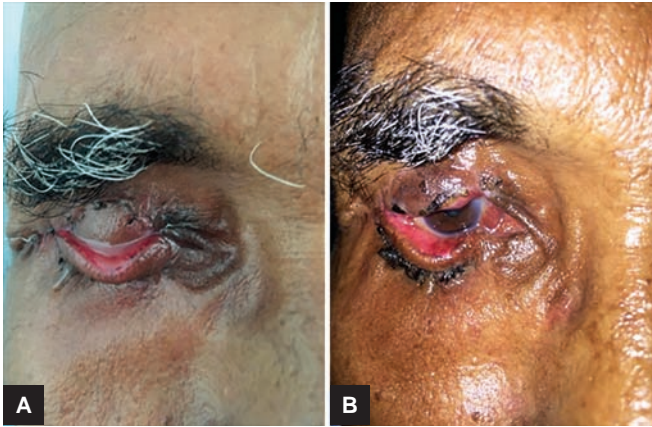

Figs 3A and B: (A) 4.0 mm silicon band; (B) silicon band being sutured

Postoperative recovery was good; functional and cosmetic status of newly formed upper lid was satisfactory.

DISCUSSION

Lid reconstruction, even though falling in the arena of oculoplastic surgeon, often invokes a general



Figs 4A and B: (A) After stage 1 surgery; (B) after stage 2 surgery

ophthalmologist in view of emergent requirements. It is required in various clinical conditions like lid tumors and malignancies, traumatic lid defects, colobomas, burns, postirradiation, and severe variant of herpes zoster ophthalmicus.⁶

The following key factors had to be noted while evaluating lid defects: Eyelid involvement – upper or lower; depth of defect – superficial or full thickness; involvement of lid margin in defect; size of defect – 25, 40, 50, 75, or 100%; shape of defect – vertical, horizontal, irregular, or pentagonal; elasticity of lids (age factor); involvement of canthal tendon; and involvement of levator muscle or lacrimal apparatus. Smaller lid defects up to 25% in young and 40% in old may be repaired by primary lid closure. A large defect above 60% has little option like cheek rotation flap (Mustarde's) or tarsoconjunctival advancement flap (Hughe's).⁷

Bridged advancement flap (Cutler-Beard procedure) has been sited to give excellent results where complete upper lid sacrifice is a compulsion. Cutler-Beard technique was proposed in year 1955 as a viable surgical option for upper lid reconstruction.⁸ It is based on the concept of lower lid sharing. Its major disadvantage was insufficient transfer of tarsus to upper lid causing a floppy lid formation. Tarsus reconstruction was sought using various grafts like donor sclera, ear cartilage, buccal cartilage, nasal septum, or even tarsus from contralateral eye.⁹ Added morbidity of the modifications in already physically challenged patient was a cause for concern.

Present work had tried a routine 4 mm silicon band used by the vitreoretinal surgeon to replace these homografts. Key advantages were easy availability, saving of surgical time, and a taut lid margin contour was achieved. Complications of the surgery were not different from routine Cutler-Beard procedures like lagophthalmos, ectropion/entropion of lids, absence of cilia, lid notching, and lid retraction. The present case noted a mild lagophthalmos insufficient to produce corneal exposure and central lid notching that required a subsequent correction by Z-plasty.

CONCLUSION

Sebaceous gland carcinoma is a matter of concern in Indian subcontinent due to its relative high incidence and late diagnosis and it may fox as recurrent chalazion initially. Cutler-Beard surgery should be regarded as the procedure of choice where complete resection of upper lid becomes necessary. Morbidity and surgical time can be reduced by use of 4 mm silicon band for upper lid reconstruction.

REFERENCES

1. Shields JA, Demirci H, Marr BP, Eagle RC Jr, Shields CL. Sebaceous carcinoma of the ocular region: a review. *Surv Ophthalmol* 2005 Mar-Apr;50(2):103-122.
2. Gardetto A, Rainer C, Ensinger C, Baldisserra I, Piza-Katzer H. Sebaceous carcinoma of eyelid: a rarely worth considering. *Br J Ophthalmol* 2002 Feb;86(2):243-244.
3. Vemuganti GK, Rai NN. Symposium on ophthalmic cytology: neoplastic lesions of eyelid, eyeball and orbit. *J Cytol* 2007 Jan-Mar;24(1):30-36.
4. Jakobiac FA, To K. Sebaceous tumors of the ocular adnexa. In: Albert DM, Jakobiac FA, editors. *Principles and practice of ophthalmology*. 2nd ed. Vol. 4. Philadelphia (PA): WB Saunders; 2000. p. 3382-3405.
5. McCord CD Jr, Nunery WR. Reconstruction of the lower eyelid and outer canthus. In: McCord CD Jr, Tanenbaum M, editors. *Oculoplastic surgery*. 2nd ed. New York (NY): Raven Press; 1987.
6. Jelks GW, Smith BJ. Reconstruction of the eyelid and associated structure, In: McCarty JG, editor. *Plastic surgery*. Philadelphia (PA): WB Saunders; 1990. p. 1671-1784.
7. Mustarde JC. *Repair and reconstruction in the orbital region*. New York (NY): Churchill Livingstone; 1980.
8. Fischer T, Noever G, Langer M, Kammer E. Experience in upper eyelid reconstruction with the Cutler-Beard technique. *Ann Plast Surg*, 2001 Sep;47(3):338-342.
9. Codner MA. Reconstruction of the eyelids and orbit. In: *Plastic surgery*. London (UK): Mosby; 2000. p. 1425-1464.