

# Prosthetic Management of Total Glossectomy Patients

<sup>1</sup>Varun Yarramaneni, <sup>2</sup>Dhanasekar Balakrishnan, <sup>3</sup>IN Aparna, <sup>4</sup>Saumya Kapoor

## ABSTRACT

**Background:** Total glossectomy impairs various functions of tongue, such as mastication, speech, swallowing, and also results in psychological breach for the patient during social activities. In a glossectomy patient, the new size of the oral cavity often produces a change in the resonance associated with certain sounds. Also, due to the decrease in size and function of the tongue, interruption occurs in articulation patterns between the tongue, the hard and soft palate, and the teeth.

**Materials and methods:** We performed a review with a bibliographic search in Scopus, Web of Science along with the PubMed/Medline, Google scholar and internet. We included the articles with major contribution toward management of total glossectomy, excluded articles and works about surgical treatments in anatomical locations other than the oral cavity.

**Conclusion:** To obtain maximum rehabilitation for these patients, the dentist must have a thorough knowledge of the physiologic processes involved in oral functions. The present article is an overview of various objectives and design concepts for rehabilitation of a total glossectomized patient.

**Keywords:** Glossectomy, Linguoalveolar, Mastication, Neuro-muscular, Resonance.

**How to cite this article:** Yarramaneni V, Balakrishnan D, Aparna IN, Kapoor S. Prosthetic Management of Total Glossectomy Patients. *Int J Prosthodont Restor Dent* 2016;6(3):66-68.

**Source of support:** Nil

**Conflict of interest:** None

## INTRODUCTION

Tongue is a muscular hydrostat situated in the floor of the mouth. Complex functions, such as mastication, swallowing and speech that requires precise neuromuscular coordination are performed by the tongue. Unlike other organs of the human body, apart from biological functions, it plays a pivotal role in maintaining social contacts.

The primary function of tongue includes swallowing and mastication with the secondary function being speech. These functions are impaired in the conditions like congenital and acquired tongue defects. Oral cancer constitutes

5% of all cancers in the human body with lips being the most prevalent site followed by tongue. The posterior two-thirds and lateral borders of the tongue have the highest incidence of occurrence. Management of such pathological conditions includes partial or total resection of tongue.<sup>1</sup> The treatment modality and its severity depends on factors, such as duration and size of the lesion as well location of the tumor. Irrespective of the extent of the surgical resection, oral form and functions are affected. Rehabilitation for total or subtotal glossectomy patients has recently gained wider acceptance. Owing to earlier detection of lesions and refined surgical techniques that have resulted in better survival rates, the number of patients requiring this care is amplified. Several investigators have used modified oral prostheses for the psychological and physical rehabilitation of these individuals which is an enormous task and has restored the oral functions.<sup>1</sup>

Lehman WL et al designed a prosthesis for the complete glossectomized patient. An acrylic resin mantle was attached to the mandibular denture and contoured to interchange with the palate of the maxillary denture. This prosthesis aids in directing the food toward the right and left occlusal tables.<sup>2</sup> Speech problems encountered by the total glossectomy patient can seriously impair speaker's intelligibility. The primary means of articulation of sounds are lost when there is a disruption in dynamic capabilities of the tongue. This leads to impairment of the patient's ability to alter the vocal track and resonance changes.

Studies were conducted on differential effects of speech prosthesis in these patients through acoustic and perceptual analysis and it was concluded that the glossal prosthesis improved speech and food management.<sup>3</sup> Management of such cases is not only challenging, but also technique sensitive. Over the years, various attempts were made to rehabilitate patients with total glossectomy and innovative designs have been proposed in both prosthetic and surgical fields.

The treatment options include surgical and Prosthodontic approach, Prosthodontic approach to treatment is based on the type and extent of surgery.<sup>4</sup>

## SURGICAL APPROACH

Surgical reconstruction through various designs of flaps includes:

- *Double tongue method:* Uses anterolateral thigh fasciocutaneous flap.<sup>5</sup>

<sup>1,4</sup>Postgraduate Student, <sup>2</sup>Professor and Head, <sup>3</sup>Professor

<sup>1-4</sup>Department of Prosthodontics and Crown & Bridge, Manipal College of Dental Sciences, Manipal, Karnataka, India

**Corresponding Author:** Dhanasekar Balakrishnan, Professor and Head, Department of Prosthodontics and Crown & Bridge Manipal College of Dental Sciences, Manipal, Karnataka, India Phone:+919742444184, e-mail: docdhana@hotmail.com

- *Manta ray flap technique*: Uses anterolateral thigh fascio-cutaneous flap.<sup>6</sup>
- *Functional reconstruction technique*: Using composite gastrointestinal-dynamic gracilis flaps<sup>7</sup> and
- *Mushroom-shaped flap*: From anterolateral thigh perforator flap for subtotal tongue reconstruction.<sup>8</sup>

The surgical approach for the management of glossectomized patient has various limitations which include the need for additional surgery, systemic condition of the patient should be compatible for additional intervention, surgical intrusion at the donor site, possible atrophy of the graft with the questionable functional outcome and the chances of recurrence of the lesion leads to unpredictable results/prognosis.<sup>9</sup> Surgical reconstruction is not feasible for such patients, and prosthetic management is the preferred treatment option.

### PROSTHODONTIC APPROACH

Prosthetic reconstruction is indicated in the conditions where the defects acquired due to certain diseases have doubtful surgical prognosis and surgical correction is difficult due to large extent of the defect, the age or physical condition of the patient which contraindicates extensive surgery, need for rapid results with minimal pain, condition of the surrounding tissues not favorable for a surgery, need for temporary appliances between multiple surgical procedures and as an adjunct to surgical procedures.<sup>9</sup>

Various designs have been described in the literature for glossectomized patients and are categorized in the Flow Chart 1. Designing a tongue prosthesis is dependent on the status of the dentition and support from the surrounding tissues. Conditions, such as glossectomy associated with resection of mandible or part of the larynx complicates the treatment plan.

### Goals<sup>4</sup>

- Decrease the size of the oral cavity to enhance the resonance and quality of speech.
- Direct the food into the esophagus
- Protection of the underlying fragile tissue
- Provide a surface for the residual tongue tissue to contact during speech and swallowing.
- Improvement in appearance and psychosocial adjustment.

### Maxillary – Glossal Prosthesis

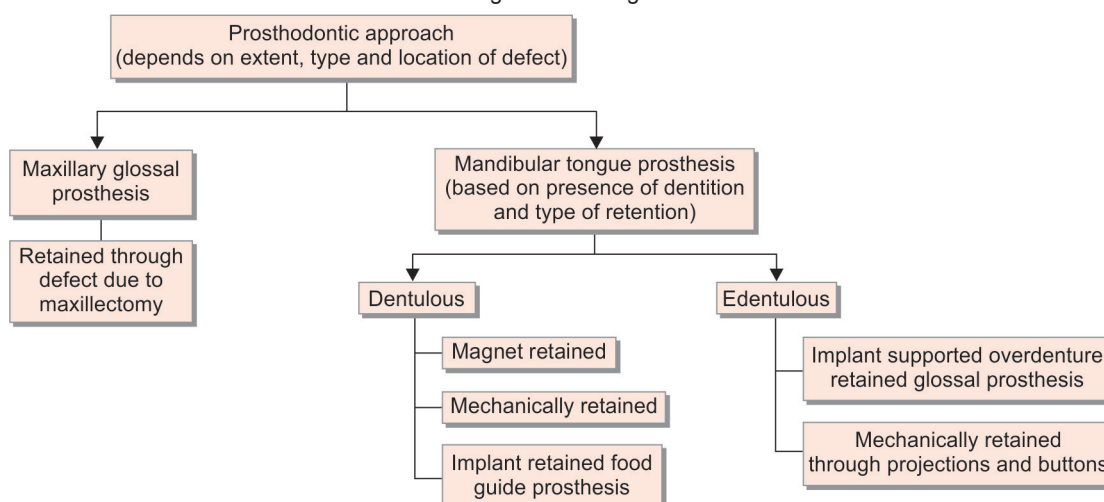
- Tongue prosthesis attached to the maxillary obturator prosthesis.

Shlomo and Stephen described replacement of the glossal structures by an artificial tongue fabricated with polysiloxane material and attached to maxillary prosthesis. The tongue is made hollow and is retained to the palatal surface of maxillary prosthesis mechanically by creating an undercut. Even though the tongue prosthesis cannot replicate the functions of the tongue, it helps in swallowing and acts as a support for the mandible during respiration as well it directs food to the posterior region of the oral cavity and eventually into oesophagus.<sup>10</sup> It is indicated in partial glossectomy situations, irradiated and resorbed mandibular ridges that do not facilitate other treatment alternatives. Even though maxillary denture prosthesis has an inherent stability, it negatively affects resonance, swallowing and speech.

### Mandibular Tongue Prosthesis

Based on the design, they can be mechanically or magnetically retained and the tongue prosthesis over implant retained denture.

Flow Chart 1: Categorization for glossal rehabilitation



## Mechanically Retained Tongue Prosthesis to Mandibular Denture includes

- *Tongue prosthesis attached to mandibular prosthetic component by mushroom like projections:* A mandibular complete denture tongue prosthesis made of silicone is retained over mandibular prosthesis by the mushroom shaped projection.<sup>11</sup>
- *Multiple button retained:* Gills et al performed speech analysis in rehabilitated glossectomized patients. The prosthesis consisted of two portions, the upper/tongue portion and a portion made of a cast framework fitted on the remaining dentition that covers the floor of the mouth. Five methylmethacrylate resin buttons were placed on the dorsal surface of finished floor of the mouth portion of the prosthesis to retain the upper portion which is shaped in the form of tongue.<sup>3</sup> These mechanically retained prostheses cause discomfort to the patient and accumulate food and debris.

## Magnetically Retained Tongue Prosthesis on Cast Partial Component<sup>12</sup>

It consists of two components, the first component is made of cast chromium-cobalt framework and is processed in clear acrylic, it covers the floor of the mouth and facilitates in swallowing. The second component is a silicone tongue prosthesis designed with anterior and posterior elevations. The anterior elevation of the prosthetic tongue aids in the expressal of anterior linguoalveolar sounds, such as t and d by allowing positive contact with the palate during speech, while the posterior elevation assists in the articulation of the glottal stops g and k. A trough-like groove in the posterior middle aspect of the prosthetic tongue helps with the pronunciation of s, sh, and ch sounds. This design of prosthesis is comfortable for the patient as there is absence of projections and design reduces the accumulation of food and debris. It has various demerits, the magnets need to be replaced/repositioned due to loss, wear, corrosion and is not supportive in the cases of resorbed mandibular edentulous ridge.

## Implant-retained Feeding Aid Prosthesis<sup>13</sup>

Food guide prosthesis helps in improving the function. It consists of a lingual extension that directs food into oropharynx. However, patients need to chop or blend the food or use a special pusher spoon. This definitive prosthesis was designed as an implant-retained overdenture to facilitate oral hygiene maintenance.

As the major functions of the tongue are swallowing and speech. In order to restore these functions, either two tongue prosthesis or a single tongue prosthesis is designed to facilitate the functions. In a two tongue

prosthesis, the tongue for speech is made with an anterior elevation that helps in speech and the other tongue is designed with a trough in posterior region to guide the food and help in swallowing. A single tongue prosthesis is designed for swallowing and speech production through anterior, posterior elevations and a midline trough.

Success of rehabilitation depends on:

- Patient motivation.
- Anatomic factors (such as presence or absence of teeth, ridge support).
- Associated morbidity of surrounding structures, including mandibulectomy, palatotomy and radiation therapy.<sup>12</sup>

## REFERENCES

1. Lauciello FR, Vergo T, Schaaf NG, Zimmerman R. Prosthodontic and speech rehabilitation after partial and complete glossectomy. *J Prosthet Dent* 1980 Feb;43(2):204-211.
2. Lehman WL, Hulicka IM, Mehringer EJ. Prosthetic treatment following complete glossectomy. *J Prosthet Dent* 1966 Mar-Apr;16(2):344-350.
3. Gillis RE, Leonard RJ. Prosthetic treatment speech and swallowing in patients with total glossectomy. *J Prosthet Dent* 1983 Dec;50(6): 808-814.
4. Aramany MA, Downs JA, Beery QC, Aslan Y. Prosthodontic rehabilitation for glossectomy patients. *J Prosthet Dent* 1987 May;57(5): 608-611.
5. Hamamoto Y, Nagasao T, Kogure T, Tamai M, Tanaka Y. The Double-Tongue Method: A new reconstruction technique for oral floor reconstruction after total glossectomy. *J Plast Reconstr Aesthet Surg* 2015 Nov;68(11):1624-1626.
6. Selber, Jesse C, Robinson, Jennifer. The manta ray flap: a technique for total glossectomy reconstruction. *Plast Reconstr Surg* 2014 Aug;134(2):341e-344e.
7. Sharma M, Iyer S, Kuriakose MA, Vijayaraghavan S, Arun P, Sudhir VR, Chatni SS, Sharan R. Functional reconstruction of near total glossectomy defects using composite gastro omental-dynamic gracilis flaps. *J Plast Reconstr Aesthet Surg* 2009 Oct;62(10):1277-1280.
8. Longo B, Pagnoni M, Ferri G, Morello R, Santanelli F. The mushroom-shaped anterolateral thigh perforator flap for subtotal tongue reconstruction. *Plast Reconstr Surg* 2013 Sep;132(3):656-665.
9. Swoope CC. Prosthetic management of resected edentulous mandibles. *J Prosthet Dent* 1969 Feb;21(2):197-201.
10. Taicher S, Bergen SF. Maxillary polydimethyl siloxane glossal prostheses. *J Prosthet Dent* 1981 Jul;46(1):71-77.
11. Aramany MA, Downs JA, Berry QC, Aslan Y. Prosthodontic rehabilitation for glossectomy patients. *J Prosthet Dent* 1982 Jul;48(1):78-81.
12. Sabouri AA, Safari A, Gharechahi J, Esmailzadeh S. Prosthodontic rehabilitation for totalglossectomy with a magnetic detachable mandibular tongue prosthesis: a clinical report. *J Prosthodont* 2012 Jul;21(5):404-407.
13. Penn M, Grossmann Y, Shifman A, Taicher S. Implant-retained feeding aid prosthesis for a patient following total glossectomy and laryngectomy: a clinical report. *J Prosthet Dent* 2007 May;97(5):261-265.