

## CASE SERIES

# Isolated Abducens Nerve Palsy Secondary to Isolated Sphenoid Sinus Disease: Case Series

<sup>1</sup>Anilkumar S Harugop, <sup>2</sup>Ramesh S Mudhol, <sup>3</sup>Shama A Bellad, <sup>4</sup>Priti S Hajare  
<sup>5</sup>Dharmishtha R Kaku, <sup>6</sup>Basavaraj Hiremath

## ABSTRACT

Isolated sphenoid sinusitis is a rare entity. Due to noncharacteristic primary manifestations, most of the patients present with ophthalmic complications, most commonly proptosis and diplopia. We report here the case series of two patients who presented with diplopia, blurred vision, and headache. Diagnosis of isolated abducens nerve palsy secondary to isolated sphenoid sinus disease was made, and both the patients underwent endoscopic sinus surgery (ESS). We hereby propose that prompt diagnosis and treatment of isolated sphenoidal sinusitis is very important, and abducens nerve (CN6) palsy could be attributed to the disease condition as both the patients' condition improved after surgery.

**Keywords:** Abducens nerve palsy, Case series, Endoscopic sinus surgery, Sphenoid sinus.

**How to cite this article:** Harugop AS, Mudhol RS, Bellad SA, Hajare PS, Kaku DR, Hiremath B. Isolated Abducens Nerve Palsy Secondary to Isolated Sphenoid Sinus Disease: Case Series. *Clin Rhinol An Int J* 2016;9(3):137-140.

**Source of support:** Nil

**Conflict of interest:** None

## BACKGROUND

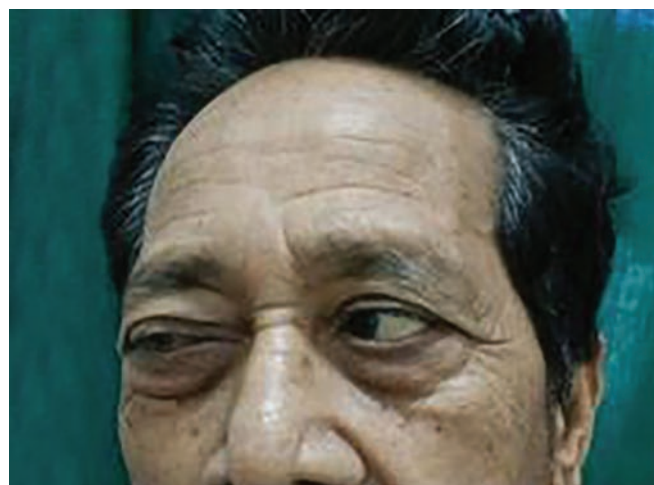Isolated sphenoid sinus disease is easily misdiagnosed because of its subtle onset and vague symptoms and accounts for 1 to 3% of all sinus lesions.<sup>1</sup> As reported in the literature, sphenoid sinus is an uncommon location of this disease. The disease may spread to important structures in the vicinity of sinus, including the cranial nerves, pituitary gland, cavernous sinus, and internal carotid artery. In this case series, the patients presented with a severe headache and lateral rectus palsy. As per literature, involvement of the abducens nerve is uncommon, with only a few documented cases of isolated

sphenoid sinus disease with ipsilateral or bilateral abducens nerve palsy and only one case with contralateral palsy.<sup>2,3</sup> Early antimicrobial therapy and/or surgical treatment should be done, as permanent cranial neuropathy and death have been reported. Quick surgical drainage or decompression of sphenoidal sinus should be done in cases with orbital involvement.<sup>1,4-7</sup>

## CASE REPORTS

### Case 1

A 45-year-old diabetic patient presented with double vision on looking to left lateral side with fever, headache, and vomiting since 20 to 25 days. On examination, the patient had left lateral rectus palsy (Fig. 1), with the rest of ear, nose, and throat (ENT) examination being normal. Computerized tomography (CT) of paranasal sinus (PNS) suggested huge enlargement of sphenoid sinus, with rest of PNS being normal (Figs 2 and 3). The patient underwent endoscopic sinus surgery (ESS) for drainage, and intraoperatively a blackish mass was seen occupying the sphenoid sinus. Marsupialization of the fungal ball was done. Potassium hydroxide (KOH) mount from sinus was positive. Intravenous cefotaxime was administered over 3 days along with topical fluconazole nose drops, and the

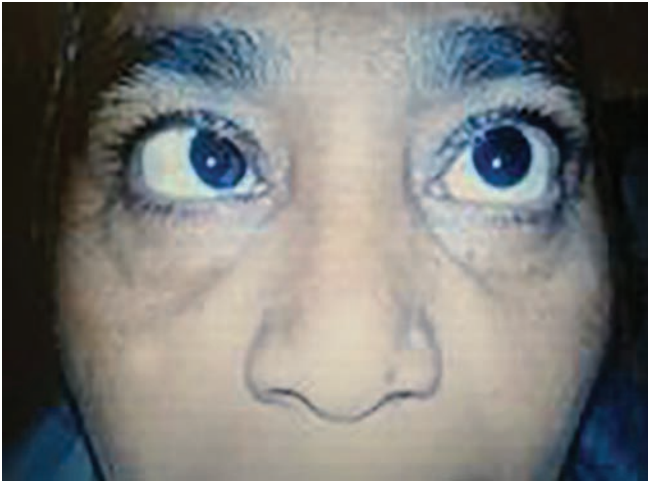

**Fig. 1:** Preoperative photograph showing paralysis of left lateral rectus (left abducens nerve palsy)

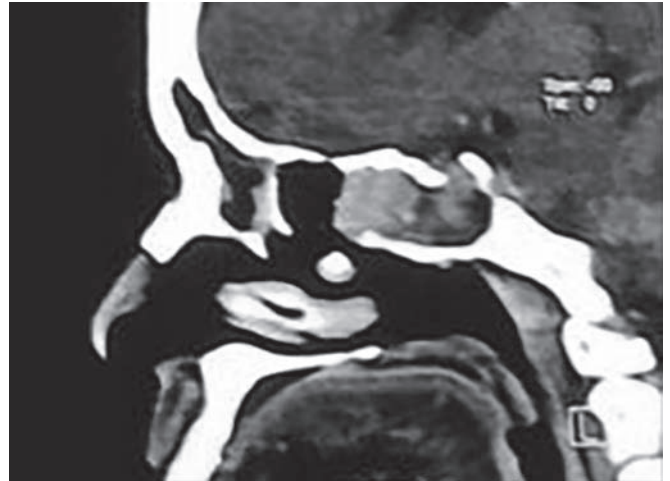
<sup>1,2,4</sup>Professor, <sup>3</sup>Assistant Professor, <sup>5,6</sup>Postgraduate

<sup>1-6</sup>Department of ENT, Head and Neck Surgery, Jawaharlal Nehru Medical College, Belgaum, Karnataka, India

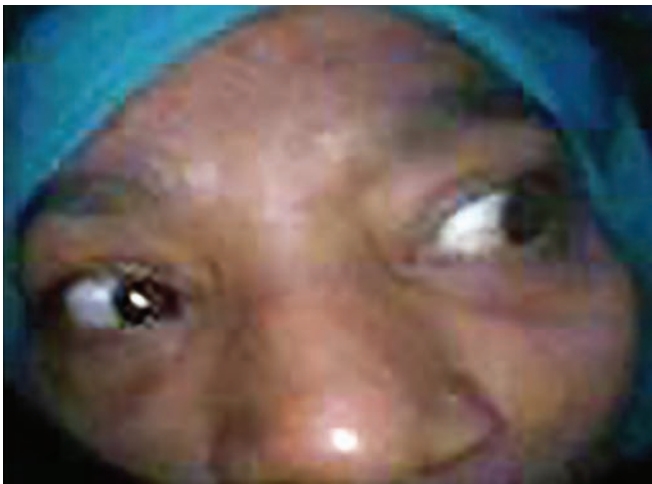
**Corresponding Author:** Anilkumar S Harugop, Professor Department of ENT, Head and Neck Surgery, Jawaharlal Nehru Medical College, Belgaum, Karnataka, India, Phone: +919448113532, e-mail: aharugop@yahoo.com



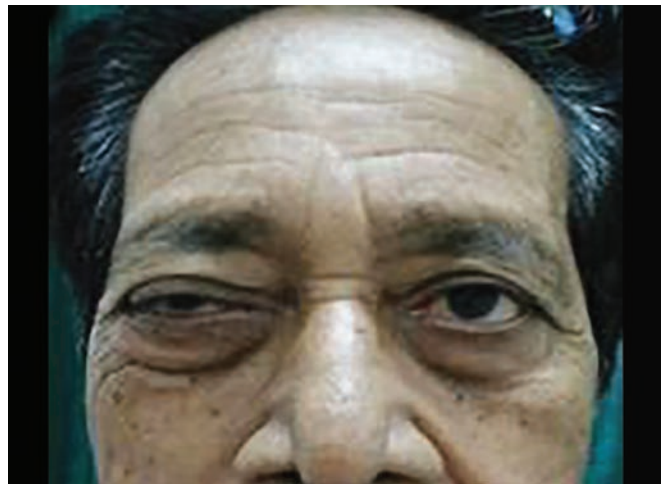**Fig. 2:** Computerized tomography scan of PNS (plain) – axial section



**Fig. 3:** Computerized tomography scan of PNS (contrast enhanced) – coronal section



**Fig. 4:** Postoperative photograph shows improvement of left abducens nerve function

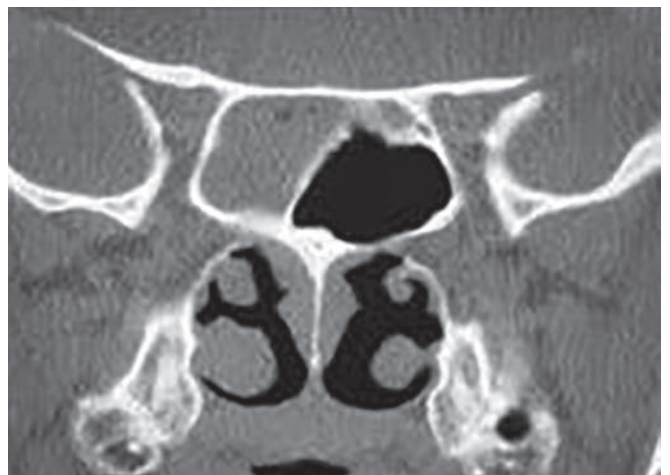


**Fig. 5:** Preoperative photograph showing right lateral rectus palsy (right abducens nerve paralysis)

patient was discharged on the third postoperative day. In the postoperative period, after 12 weeks, there was improvement in vision, improved eyeball movements (Fig. 4), and relief of symptoms of raised intracranial tension.

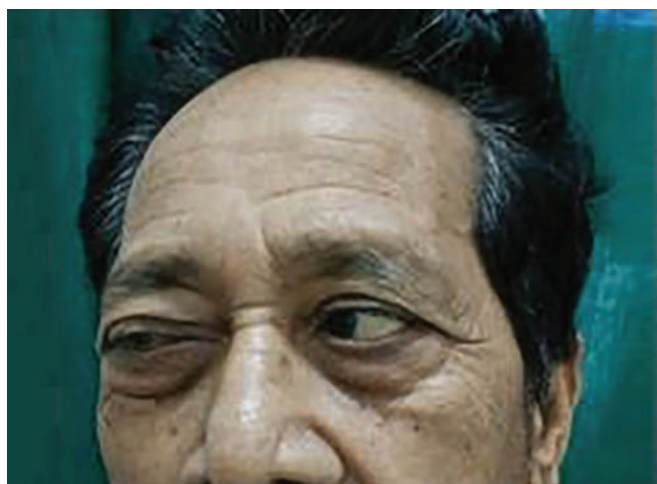
## Case 2

A 72-year-old male patient was referred from neuro-medicine with complaints of headache, blurred vision, and diplopia since 10 to 12 days. On examination, right abducens nerve palsy (Fig. 5) was present, and thick mucoid secretions were present in the nasal cavity with no PNS tenderness. Rest of the ENT examination was normal. Computerized tomography scan of PNS suggested sphenoid sinus haziness on right side (Fig. 6), with rest of sinuses being normal. Endoscopic sphenoidotomy (ESS) was done for him, and KOH mount from the sinus was positive. Postoperatively, patient received injection amphotericin B for 3 days and topical fluconazole nose

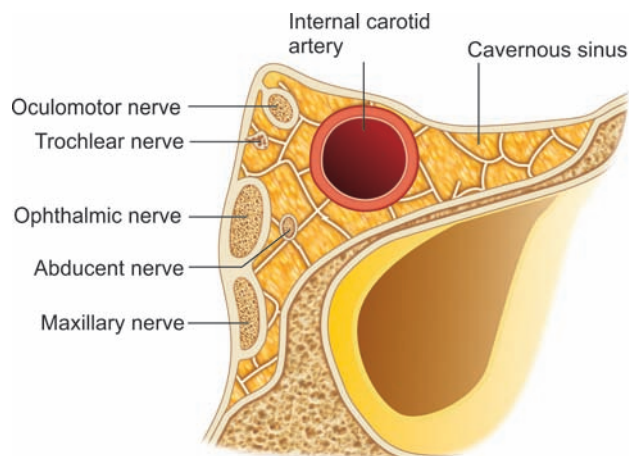


**Fig. 6:** Computerized tomography scan PNS showing involvement of sphenoid sinus (coronal section)

drops, following which the patient was discharged. In the postoperative period, there was improvement in vision, improved eyeball movements (Fig. 7), and sinus symptoms were relieved.



**Fig. 7:** Postoperative photograph showing improvement in right abducens nerve function



**Fig. 8:** Coronal section of the posterior aspect of the sphenoid sinus showing its close proximity to important functional structures: The internal carotid artery, cavernous sinus, and oculomotor, trochlear, ophthalmic, abducens, and maxillary nerves

**Table 1:** Clinical characteristics of two patients with solitary abducens palsy due to isolated sphenoid sinus disease

Age/sex	Predisposing factor	Symptoms	Interval	Diagnosis	Surgical technique	Follow-up	Outcome
45 years/F	Diabetes mellitus	Diplopia, fever, headache, and vomiting	25–27 days	Isolated sphenoid sinus fungal disease	ESS	3 months	Improved eye movements
72 years/M		Blurred vision, diplopia, and headache	10–12 days	Isolated sphenoid sinus fungal disease	ESS	3 months	Improved eye movements

**RESULTS**

The results are summarized in Table 1.

**DISCUSSION**

Isolated sphenoid sinus disease (ISSD) frequently occurs in the middle aged (about 40 to 50 years old).<sup>1,4</sup> It is rare, and sphenoid sinus disease is usually accompanied with the involvement of other sinuses. The drainage of sphenoid sinus may be affected by direct spread from the ethmoid sinus, anatomic variation, or iatrogenic trauma, and these predispose the area to the disease.<sup>5,6</sup> Causes of ISSD are inflammatory diseases, fibro-osseous disease, neoplasms, encephalocele, and internal carotid artery aneurysms.<sup>1</sup> Inflammatory pathogens are considered the most commonly reported etiological factors, among which fungal agents have been detected in 31% of cases.<sup>8</sup> In our cases, fungal infection, which is a form of inflammation, was the etiologic factor. The presenting symptoms and signs in our cases were headache and diplopia, with the involvement of abducens nerve (Table 1). Lesions of the sphenoid sinus might involve the adjacent structures including the optic, abducens, and oculomotor nerves (Fig. 8).<sup>1,4,9</sup> Abducens nerve due to its medial intracavernous position is the second most frequently involved cranial nerve (incidence 6%).<sup>1</sup>

The possible mechanisms for the development of abducens palsy are<sup>10-12</sup>

- Inflammation from sphenoidal sinusitis to infect abducens nerve sheath and to result in nerve palsy.
- The sphenoid mass expanding to the cavernous sinus or superior orbital fissure and compressing the abducens nerve.
- Vasculitis or cavernous sinus thrombosis causing ischemic infarction of the abducens nerve. The dorsal clival artery, which arises from the meningohypophyseal trunk and supplies the proximal portion of the intracavernous abducens nerve, may play a significant role in the isolated abducens palsy.
- Dehiscent lateral wall of the sphenoid sinus, which could be present in 4% of adult skull, known as Sternberg’s canal.<sup>13</sup>

In our cases, inflammatory cause could be the possible mechanism for abducens nerve palsy. The common pathogens isolated from acute sphenoid sinusitis are *Staphylococcus aureus*, *Streptococcus* species, and *Aspergillus*. Gram-negative and anaerobic organisms are more associated with chronic sphenoid sinusitis.<sup>1,4,14</sup> In the chronic noninvasive form, usually described as a “fungal ball” of the sinus, the fungal hyphae proliferate in the sinuses of immunocompetent patients without evidence of tissue invasion or bone erosion.<sup>14</sup> The fungus

ball is defined as an extramucosal mycotic proliferation that fills one or more PNSs.<sup>15</sup> Complications of sinus infection include bacterial meningitis, cavernous sinus thrombosis, subdural abscess, cortical vein thrombosis, ophthalmoplegia, and pituitary insufficiency.<sup>16</sup> In addition, sphenoid sinusitis can present as an aseptic meningitis due to the presence of a parameningeal focus.<sup>17</sup> Osteomyelitis, subperiosteal abscess, orbital cellulitis and abscess, visual loss mimicking optic neuritis, multiple cranial nerve palsies, and papilledema can also occur as a complication of sphenoidal sinusitis. Thus, sinusitis can be a life-threatening condition and if neglected or mismanaged can lead to various complications.<sup>18</sup> Endoscopic sphenoid surgery is the surgery of choice for sphenoid sinus lesion, and the surgeon should be careful of the nearby important structures, such as the optic nerve and internal carotid artery.<sup>19</sup>

## CONCLUSION

Advancements in technology including CT, MRI, and ESS have allowed better elucidation of the sinus disease process, etiology, and surgical intervention. The longer the diplopia persists, the longer the recovery time is needed, and improvement in the extraocular muscle function is a good sign for recovery. Hence, early diagnosis and prompt surgical intervention are imperative in patients with sphenoidal fungus, especially those presenting with signs of raised intracranial tension and orbital involvement.

## CLINICAL SIGNIFICANCE

Early diagnosis and prompt surgical treatment are paramount in patients of sphenoid sinusitis in order to avoid impending complications and to regain the extraocular function for better vision.

## ACKNOWLEDGMENT

The authors acknowledge the anesthetists for providing hypotensive anesthesia and to radiologists for their radiological diagnosis.

## REFERENCES

1. Lawson W, Reino AJ. Isolated sphenoid sinus disease: an analysis of 132 cases. *Laryngoscope* 1997 Dec;107(12 Pt 1):1590-1595.

2. Taskapilioglu O, Yurtogullari S, Yilmaz E, Hakyemez B, Yilmazlar S, Tolunay S, Turan F, Bora I. Isolated sixth nerve palsy due to plasma cell granuloma in the sphenoid sinus: case report and review of the literature. *Clin Neuroradiol* 2011 Nov;21(4):235-238.
3. Gupta N, Michel MA, Poetker DM. Recurrent contralateral abducens nerve palsy in acute unilateral sphenoiditis. *Am J Otolaryngol* 2010 Sep-Oct;31(5):372-375.
4. Ruoppi P, Seppa J, Pukkila M, Nuutinen J. Isolated sphenoid sinus diseases-report of 39 cases. *Arch Otolaryngol Head Neck Surg* 2000 Jun;126(6):777-781.
5. Postma LGN, Chole RA, Nemzek WR. Reversible blindness secondary to acute sphenoid sinusitis. *Otolaryngol Head Neck Surg* 1995 Jun;112(6):743-746.
6. Turgut S, Ozcan M, Celikkanant S, Ozdem C. Isolated sphenoid sinusitis. *Rhinology* 1997 Sep;35(3):132-135.
7. Muneer A, Jones NS. Unilateral abducens nerve palsy: a presenting sign of sphenoid sinus mucocoeles. *J Laryngol Otol* 1997 Jul;111(7):644-646.
8. Friedman A, Batra PS, Fakhri S, Citardi MJ, Lanza DC. Isolated sphenoid sinus disease; Etiology and management. *Otolaryngol Head Neck Surg* 2005 Oct;133(4):544-550.
9. Gray, H. Oblique section through the cavernous sinus. In: *Gray's anatomy*. 38th ed. Philadelphia, PA: Lea & Febiger; 1918. Fig 571.
10. Patt BS, Manning SC. Blindness resulting from orbital complications of sinusitis. *Otolaryngol Head Neck Surg* 1991 Jun;104(6):789-795.
11. Krisht A, Barnett DW, Barrow DL, Bonner G. The blood supply of the intracavernous cranial nerves: an anatomic study. *Neurosurgery* 1994 Feb;34(2):275-279.
12. Lee LA, Lee TJ, Huang CC. Endoscopic sinus surgery for solitary abducens palsy in patients with isolated sphenoid sinus disease: report of four cases. *Chang Gung Med J* 2007 Oct;25(10):689-694.
13. Khatrar VS, Hathiram BT, Sharma H. Sternberg's canal and the controversies surrounding it. *Otorhinolaryngol Clin* 2011 Sep-Dec;3(3):184-187.
14. Megalamani SB, Shetty N. Lateral rectus palsy associated with isolated sphenoid sinus fungal lesion. *J Otol Rhinol* 2014;3(6):1-3.
15. Pagella F, Pusateri A, Matti E, Giourgos G, Cavanna C, De Bernardi F, Bignami M, Castelnuovo P. Sphenoid sinus fungal ball: our experience. *Am J Rhinol Allergy* 2011 Jul-Aug;25(4):276-280.
16. Goldman GE, Fontanarosa PB, Anderson JM. Isolated sphenoid sinusitis. *Am J Emerg Med* 1993 May;11(3):235-238.
17. Brook I, Overturf GD, Steinberg EA, Hawkins DB. Acute sphenoid sinusitis presenting as aseptic meningitis: a pachymeningitis syndrome. *Int J Pediatr Otorhinolaryngol* 1982 Mar;4(1):77-81.
18. Singh B, VanDellen J, Ramjettan S, Maharaj TJ. Simogenic intracranial complications. *J Laryngol Otol* 1995 Oct;109(10):945-950.
19. Yanagisawa E. Endoscopic view of sphenoid sinus cavity. *Ear Nose Throat J* 1993 Jun;72(6):393-394.